

Tenex Health Abstract Summaries

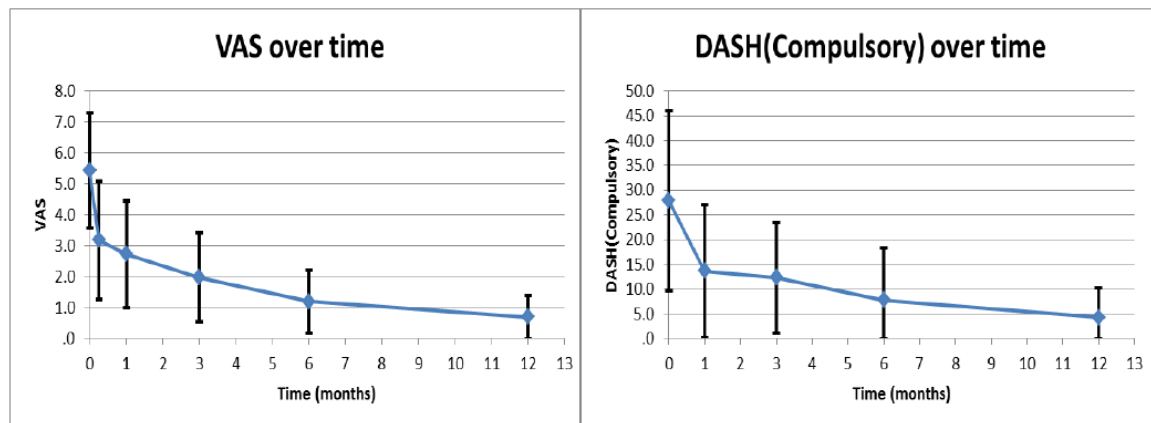
Koh, Joyce; Mohan, P.; Morrey, Bernard et al. "Fasciotomy and Surgical Tenotomy for Recalcitrant Lateral Elbow Tendinopathy"

American Journal of Sports Medicine, Vol. 41, 636-644, 2013

Purpose: To explore the safety and efficacy of a new minimally invasive mode of treatment that delivers focused, calibrated ultrasonic energy, effectively microsecting and removing only the pathological tendon tissue with the Tenex Health TX-1 device. This prospective study explores the safety, tolerability and early efficacy of this technique in patients suffering from lateral epicondylitis.

Results: Twenty (20) patients between the ages of 33-65 years of age underwent the ultrasonic microresection procedure in an outpatient clinic setting using the TX-1 device. The patients had failed non-operative therapy and were symptomatic for an average 12.5 months. Patient's baseline pain (VAS), quality of life/QOL (DASH Score) and ultrasound evidence of tendonosis was documented and at 2 weeks, 1, 3, 6 and 12 months post-procedure. There were no device or patient related complications. All patients were treated under local anesthesia with an average ultrasonic energy of 33 seconds required to complete the percutaneous tenotomy. No additional treatments or physical therapy were provided to the patients. Improvement in pain and QOL measurements were observed in 2 weeks and reached statistical significance by 1 month which was sustained at 12 months. Nineteen of the 20 patients expressed satisfaction with the procedure.

Conclusion: Ultrasonic micro resection of diseased tissue with the Tenex Health TX-1 device provides a focally directed, safe, specific, minimally invasive and well-tolerated treatment for recalcitrant elbow tendinopathy in an office based or ambulatory setting with good evidence of some level of efficacy in 19 of 20 and is sustained for at least one year.



October 2014

Hackel, Joshua; Williams, Michael “Ultrasonic energy helps perform fasciotomy and surgical tenotomy for tendinosis, fasciosis” Orthopedics Today, May 2013

Tendinosis, is a common problem affecting over 10 million people per year. Tendon injury is often the result of overuse activities which cause microtears of collagen fiber within a tendon. These microtears propagate a cycle of degenerative change leading to tendinosis, pain and limiting function. The diagnosis of tendinosis is made by patient history, physical exam and can be confirmed by ultrasound imaging. If conservative methods fail to control pain and restore function the patient is typically offered surgery. Recently, Tenex Health received FDA approval to market their TX-1 device designed to treat tendinosis and fasciosis. This is an innovative option for treating tendinosis and fasciosis where the TX-1 MicroTip is used to cut and remove degenerative tendon tissue to relieve pain and dysfunction. The Tenex Health TX is a minimally invasive procedure and addresses the plantar fascia similar to the traditional open fasciotomy. It has also been successful in the treatment of lateral and medial epicondylitis, plantar fasciitis, patellar tendinosis, quadriceps and Achilles tendinosis.

Morrey, Bernard “Ultrasound Percutaneous Tenotomy for Epicondylitis” Techniques in Shoulder and Elbow Surgery. Vol. 14 Number 2, June 2013

The use of therapeutic ultrasound is well recognized in the medical field. Successful medical treatment of cataracts with phacoemulsification is now treated quickly and effectively as an outpatient surgery. The same concept has been applied for the management of chronic tendinopathy. This treatment employs an ultrasonic probe - surgical instrument that uses ultrasonic energy to effectively tenotomize the diseased tendon. Ultrasound imaging is used to diagnose, identify the pathology of diseased tissue and the treatment can be performed in a clinical or ambulatory surgical center. The patient is placed supine on an operating or clinical exam table and positioned based on surgeon preference and anatomical location. The site of maximum tenderness is identified by the patient, confirmed by physician and diagnostic ultrasound identifies the hypoechoic area that appears darkened under ultrasound imaging. The area is prepped and a fast acting local anesthetic is used to create a skin wheal approximately 1.5 cm. The needle is then advanced through the skin wheal to the area of precise tenderness and 3 to 4 ML of a fast acting anesthetic is injected in the region. To facilitate the percutaneous insertion of the Tenex Health TX-1 ultrasonic probe, an 11 inch blade is used to create a puncture site through the skin wheal. The TX-1 MicroTip is then introduced through the puncture site, identified with the sensor and under ultrasound guidance is introduced to the hypoechoic region. During the procedure, the TX-1 MicroTip surgical instrument is moved in a linear manner in and out of the lesion and the hypoechoic region is visually altered, indicating the lesion has been effectively treated. The procedure is extremely well tolerated and has a low complication rate. The effectiveness appears to improve up to one year after the initial procedure and is emerging as a viable and attractive alternative for the treatment of chronic epicondylitis.

October 2014

Elattrache, Neal; Morrey, Bernard “Percutaneous Ultrasonic Tenotomy as a Treatment for Chronic Patellar Tendinopathy-Jumper’s Knee” Operative Techniques in Orthopaedics, Volume 23 Issue 2 June 2013

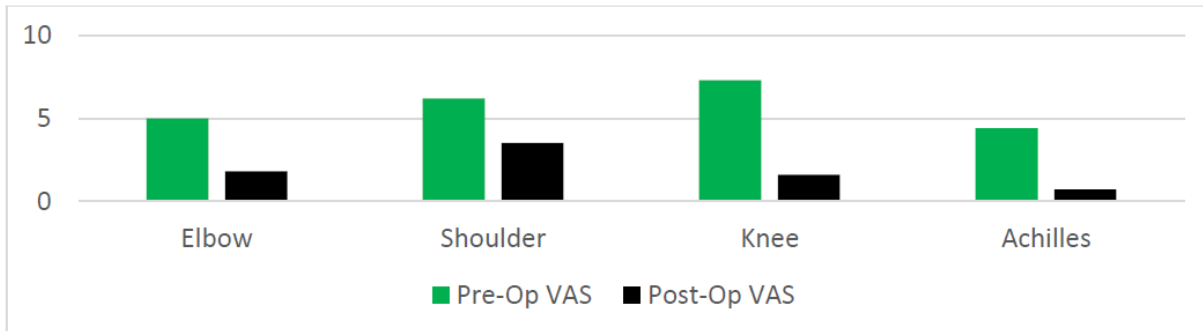
Chronic tendinopathy of the patella or “jumper’s knee” remains a major treatment challenge. Surgery has considerable morbidity and is unpredictable in effectiveness and most surgeons will try other conservative treatment for about a year prior to performing. The result is often the patient has marked dysfunction even for daily activity. Most recently the use of ultrasound to guide various treatments has been introduced and documented. Emerging as a treatment for chronic tendinopathy is to first isolate the lesion by ultrasound guidance and perform a percutaneous tenotomy using ultrasonic cutting energy. Tenex Health has developed the TX-1 instrument with targeted ultrasonic cutting energy to perform a percutaneous tenotomy on areas of anatomy where tendinopathy exists. To date, the safety and efficacy of the procedure in general has been exhibited in over 5000 patients treated for chronic tendinosis or plantar fasciitis. This is the only percutaneous modality, other than open resection that is capable of cutting and debriding the diseased tendon tissue. Percutaneous tenotomy of the patella tendon with the TX-1 MicroTip was successfully performed in 16 patients of which 10 were collegiate level athletes. The patients were treated with the TX-1 MicroTip once with no additional follow-on treatments. The procedure is well tolerated and has a low complication rate and is a viable alternative to treat refractory patellar tendinopathy.

Barnes, Darryl “Ultrasonic Energy in Tendon Treatment” Operative Techniques in Orthopaedics, Volume 23 Issue 3 Aug 2013

Tenotomy and debridement of diseased tendon can resolve symptoms due to chronic degenerative tendinopathic lesions (i.e. tennis elbow). Recent improvements in musculoskeletal ultrasound imaging and the development of a minimally invasive ultrasound-guided ultrasonic energy debridement tool, the TX-1 MicroTip from Tenex Health, have created a viable less-invasive alternative to open tenotomy and debridement procedures. The rationale behind this novel and minimally invasive procedure is to first ultrasonographically visualize the diseased portion of the tendon. Next, a small ultrasonic cutting and debridement tool is percutaneously inserted and guided under dynamic sonographic imaging into the tendinopathic region to complete a percutaneous tenotomy or fasciotomy. The TX-1 MicroTip is safe and has demonstrated similar or better outcomes to open tenotomy and fasciotomy.

Khanna, Malini et al “A Novel Approach to the Treatment of Chronic Tendon Pathology: A Pilot Study”, Abstract Presentation at Annual Meeting of American Academy of Physical Medicine and Rehabilitation, Oct 2013

Chronic tendonopathy remains one of the most challenging orthopaedic conditions to treat. The purpose of the study it to evaluate the early efficacy of a novel percutaneous fasciotomy and surgical tenotomy technology and technique used to treat chronic patella tendonosis, Achilles tendonosis, rotator cuff tendonosis and lateral epicondylitis. Eighteen (18) patients with chronic tendonosis who failed conservative treatment were evaluated. These patients elected to go through a new treatment from Tenex Health which uses the TX1 MicroTip that delivers precise ultrasonic cutting energy through a percutaneous approach and ultrasound image guidance. The TX1 MicroTip is designed to cut and debride only the damaged tendon tissue. The average age of the patients were 48.2 years (SD 15.2) and the average duration of symptoms was 6.4 months (SD 2.4). At two weeks after the treatment, there was a significant improvement in pain/VAS score ($p < 0.05$) as well as an overall improvement in quality of life outcome measurements ($p = 0.004$). Sixteen of the eighteen (89%) patients were satisfied with the procedure at the follow-up visit.



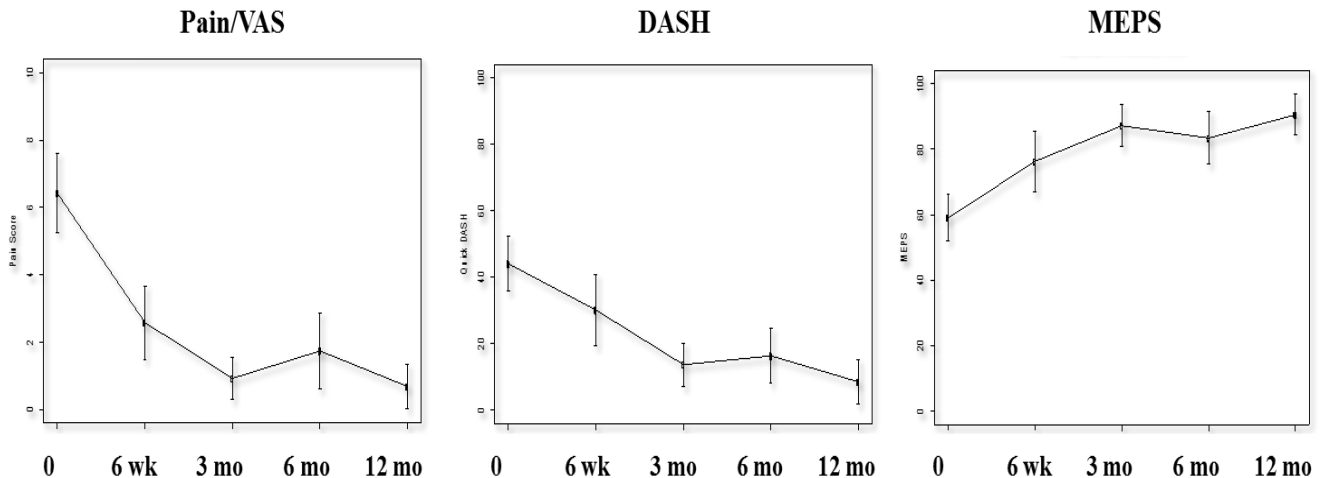
Patel, Mihir “A Novel Treatment Method for Refractory Plantar Fasciitis (Am Journal of Orthopedics, 2014)

Plantar fasciitis is a major healthcare problem world-wide, accounting for over 3 million physician visits in the US alone. Chronic pain at the site can develop as time goes on due to long standing inflammatory changes. Fibrotic tissue may develop at the site. A novel treatment method for plantar fasciitis was evaluated for efficacy and safety. Utilizing the TX1 ultrasonic instrument developed by Tenex Health Inc., eighteen (18) patients with symptoms of greater than 6 months underwent partial division of the plantar fascia at the site of the lesion. These patients were prospectively treated allowing patients to randomly continue in the non-intervention treatment method or an instrument and procedure that cuts and debrides plantar fascia with the TX1 instrument. Before treatment with TX1, fourteen patients had undergone conservative treatment and the remaining four patients had an open or endoscopic partial release at other institutions without any improvement in their symptoms prior to presentation. A percutaneous fasciotomy using the TX1 instrument was performed only once in an out-patient setting and no other treatment was performed. Complete resolution of the symptoms occurred in 17 of the 18 patients within 3 months and sustained at the 12 month post-procedure evaluation period. The mean AOFAS scores were pre-operatively 30.1 and post-operatively of 88.1. There were no wound complications or infections at the site. An ultrasound guided percutaneous fasciotomy using the TX1 instrument that delivers directed ultrasonic energy appears to be a safe, well tolerated and effective treatment option for a condition characterized by being refractory to current treatment programs.

October 2014

Darryl Barnes, Jim Beckley, and Jay Smith “Ultrasonic Percutaneous Tenotomy for Chronic Elbow Tendinosis: A Prospective Study (Journal of Shoulder and Elbow Surgery, 2014).

Clinical “lateral epicondylitis” or “tennis elbow” is the most common cause of elbow pain, affecting 2-3% of the population and resulting in significant activity restriction and economic burden. Although historically considered to be an inflammatory condition of the common extensor tendon, it is now well established that chronic symptoms are typically associated with tendon degeneration resulting from repetitive microtrauma. Although most patients respond to conservative medical treatment, the balance are refractory and considered candidates for surgical intervention with the goal of cutting and removing the “tendonotic” tissue and stimulating a healing response. The objective of this study was to test the hypothesis that ultrasound guided percutaneous tenotomy using the Tenex Health TX System would produce comparable outcomes to open surgical intervention at one year. Nineteen consecutive patients ages 38-67 years failing conservative management for > 6 months with either medial (7) or lateral (12) tendinopathy were prospectively studied. Patient assessment included: visual analog pain scale (VAS), the Disabilities of the Arm, Shoulder and Hand index (DASH), and the Mayo Elbow Performance Score (MEPS) by an independent observer pre-treatment and 6 weeks, 3 months, 6 months and 12 months post-procedure. Results revealed no procedural complications and a significant improvement in pain VAS scores from 6.4 pre-treatment to 2.6 at 6 weeks and sustained at 12 months post-procedure ($p < 0.0001$), pre-treatment DASH of 44.1 to 8.6 at 12 months ($p < 0.0001$), and MEPS pre-treatment score of 59.1 while at 12 months 83.4 ($p < 0.0001$). By localizing, tenotomizing and removing diseased tissue, ultrasonic percutaneous tenotomy appears to be a safe and definitive, treatment option for chronic, refractory lateral or medial elbow tendinopathy.



October 2014

Hilal Maradit-Kremers and Thomas Sanders. Epidemiology and the Healthcare Burden of Tennis Elbow: A Population Based Study. (accepted, American Journal of Sports Medicine)

Lateral epicondylitis is a common condition both in primary care and specialty clinics. The purpose of this study was to evaluate the natural history (i.e., incidence, recurrence and progression to surgery) of lateral epicondylitis in a large population

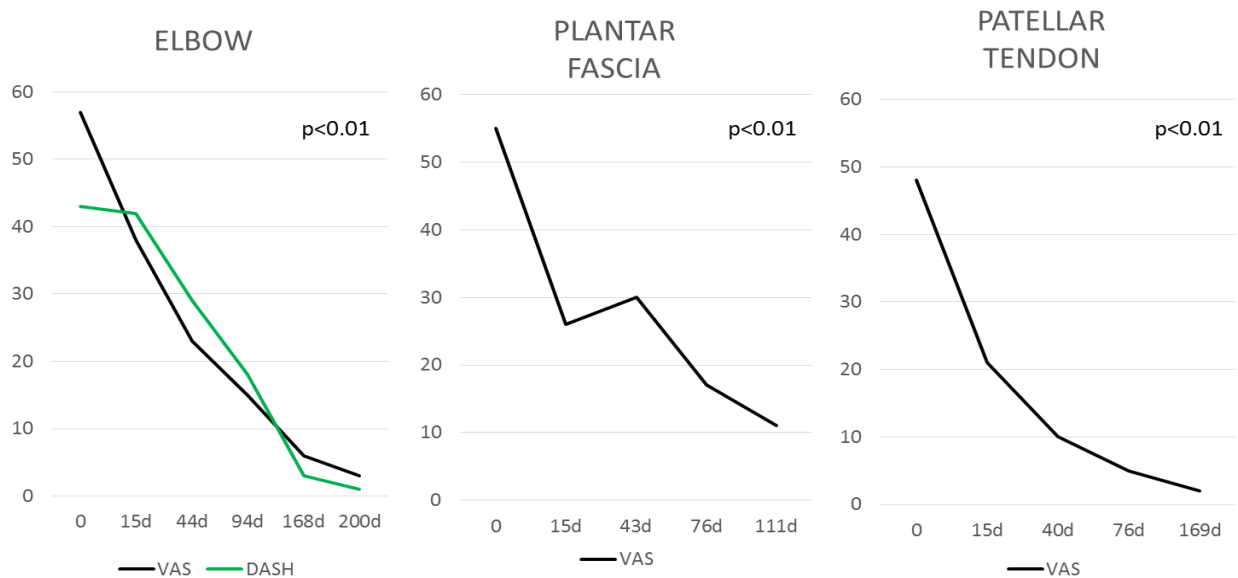
Study Design and Methods: This was a retrospective population-based analysis with a cohort consisting of all residents in Olmsted County, MN over a 12 year span using the Rochester Epidemiology Project to ascertain medical information. The study population was comprised of patients with new-onset lateral epicondylitis between 1/1/2000 and 12/31/2012. The medical records of a 10% random sample (n=576) were reviewed to ascertain information on patient and disease characteristics, treatment modalities, recurrence and progression to surgery. Age- and sex-specific incidence rates were calculated and adjusted to the 2010 United States population.

Results and Conclusion: Results from the study estimate that in absolute numbers there are approximately 1 million individuals with new onset lateral epicondylitis each year in the United States. This population-based study indicates that lateral epicondylitis is relatively common, particularly among individuals aged 40-59 years during their most productive years. Finally, the data suggest that those without resolution of symptoms within 6 months of onset and conservative treatment will tend to have a more prolonged course possibly requiring definitive procedural intervention.

October 2014

Traister, Lingor, Simons. The Effect of Percutaneous Tenotomy Using Tenex On Short Term Average Pain Scores in Refractory Tendinopathies (presented at Annual Meeting of American Medical Society for Sports Medicine, April 2014, submitted for publication)

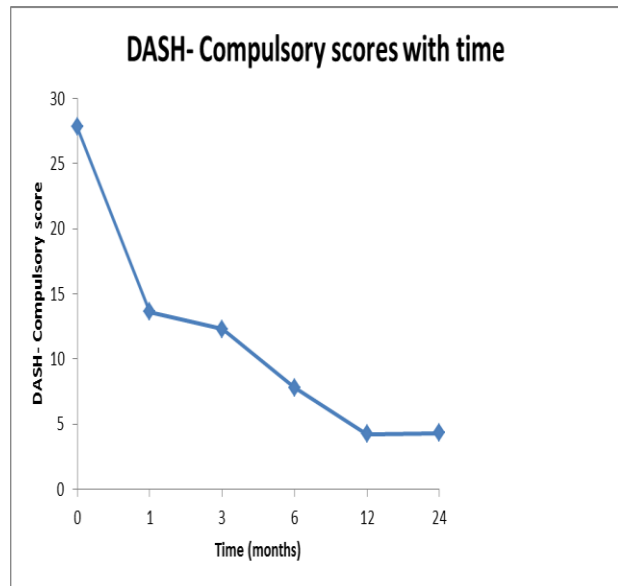
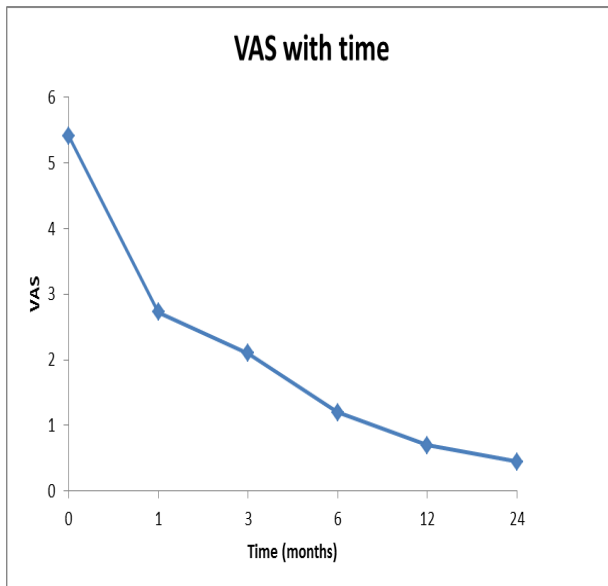
Patients presenting with pain due to chronic tendinopathy is common in primary care settings. Many of these patients have failed one or more conservative therapies. These therapies may include rest, physical therapy, bracing and cortisone injections. Percutaneous tenotomy via the Tenex Health TX system provides a novel technique for patients with recalcitrant tendinopathy. It combines ultrasound imaging for guidance and ultrasonic energy to precisely cut and remove degenerative tendon tissue. Given the novelty of this technology, there have been few studies looking at how patients' pain scores respond to this new procedure. The purpose of this study was to perform a review of average pain scores on a cohort of 43 patients that had recalcitrant tendinopathy and underwent percutaneous tenotomy via the Tenex Health TX system in an outpatient sports medicine clinic. Tenotomy sites included lateral epicondyle (24 patients), patellar tendon (8 patients) and plantar fascia (11 patients). These patients had failed at least one conservative measure and had a diagnostic ultrasound documenting pathology consistent with chronic tendinopathy. Pre-treatment pain scores were determined using a 100 point visual analogue scale (VAS). Patients were asked to follow-up at approximately 2, 6, 12 and 24 weeks post-treatment. A Disabilities of Arm, Shoulder and Hand (DASH) survey was also used for patients who underwent percutaneous tenotomies of the lateral epicondyle. Overall, the three tenotomy sites showed significant decline in pain scores from baseline and a similar improvement in DASH scores for the patients with elbow tendonosis. There were no adverse events reported by any patients and none of the patient's pain scores significantly worsened. The goal of this study was to look at the trends of pain scores. With the significant decline in average pain scores across all three tenotomy sites, further high powered studies are warranted to evaluate this promising technology and treatment.



October 2014

Koh et al, Two year clinical outcomes of percutaneous ultrasonic microresection for recalcitrant lateral elbow tendinopathy (submitted for publication)

Minimally invasive surgical techniques for recalcitrant lateral elbow tendinopathy have gained popularity in recent years. Ultrasound guided percutaneous microresection using ultrasonic energy of the diseased tendon is a novel procedure that can be performed safely in the office or ambulatory surgery setting and is well tolerated. Good clinical outcomes at 1 year have been documented previously. We aim to assess the efficacy and clinical outcomes of our patients who have undergone minimally invasive ultrasound guided percutaneous microresection for recalcitrant lateral elbow tendinopathy with the Tenex Health TX System at 2 years post procedure. As a follow up on the original study group reporting the 1 year clinical, we assessed outcomes of 7 male and 13 female patients with a mean age of 47 years who failed non-operative therapy. We interviewed all 20 original patients at a minimum of 2 years post procedure and documented outcomes of patient satisfaction; visual analog scale (VAS) pain scores; and Disabilities of the Arm, Shoulder and Hand (DASH) scores. Most of these patients reported no or minimal pain at 2 years, with median VAS score of 0.5 at 2 years (range 0-2.5, $p < 0.001$). Functional outcomes of patients also improved, with median DASH-Compulsory score of 5.6 at 2 years (range 0-10.8, $p < 0.001$). There were no cases of adverse complications and no recurrences. In conclusion, ultrasonic microresection of the diseased tissue using the Tenex Health TX System for recalcitrant lateral elbow tendinopathy is safe, well tolerated, minimally invasive, and can be conveniently performed in the outpatient or ambulatory setting. Our results showed good clinical outcomes and pain reduction in 19/20 (95%) of our patients that was sustained for at least 2 years. This novel treatment can be considered for early and definitive intervention of elbow tendinopathy.



October 2014

Rahul Razdan and Eric Vanderwoude. Ultrasound Guided Percutaneous Fasciotomy: A Novel Approach in Treating Chronic Plantar Fasciitis (submitted for publication)

The condition of plantar fasciitis is thought to arise from overuse or repetitive micro trauma of the tissue. After 3-4 months of conservative treatment, this condition is considered to be chronic and characterized by collagen degeneration and an increase in ground substance and vascularity. Diagnosis is usually based on clinical signs including: plantar heel pain when weight-bearing after a period on non-weight-bearing, pain that eases with initial activity, but then increases with further use, and localized pain on palpation. Chronic plantar fasciitis is one of the most commonly occurring foot complaints occurring in up to 10% of the population at some point in their lifetime. A safe and effective definitive treatment is highly desired by those treating this chronic disease process. This prospective study evaluated a novel way of treating chronic plantar fasciitis utilizing an ultrasound guided instrument (Tenex Health TX System) delivering a percutaneous fasciotomy. A total of 53 patients with a minimum of 6 month or more history of heel pain due to plantar fasciitis were treated in an out-patient setting. All had had conservative treatment of physiotherapy and shoe-support without significant pain relief and thus acted as their own controls for the purposes of the study. Pain (standard VAS) and functional disability was assessed utilizing the validated Foot and Ankle Disability Index (FADI). Data was collected before procedure, two and six weeks and 6 months following treatment. The VAS and FADI data showed a highly significant improvement at all time periods compared to baseline ($p < 0.0001$). There were no complications related to the procedure. Our study demonstrates that ultrasound guided percutaneous fasciotomy is highly effective in treating patients with chronic refractory heel pain due to chronic plantar fascia disease.

Mark Ellis, Kate Johnson, Lewis Freed, and Todd B. Haddon. Fasciotomy and Surgical Tenotomy for Chronic Achilles Insertional Tendinopathy: A Retrospective Study Using Ultrasound-Guided Percutaneous Tenotomy Approach.

Achilles insertional tendon pathology is a common condition affecting a broad range of patients. When conservative treatments are unsuccessful, the traditional open resection, debridement and reattachment of the Achilles tendon is a variably reliable procedure with significant risk for morbidity. Fasciotomy and surgical tenotomy using ultrasound-guided percutaneous tenotomy and microresection is used on various tendons in the body but the efficacy has not been examined specifically for the Achilles tendon. This retrospective review of 26 consecutive patients (7 male / 21 female) with chronic insertional tendinopathy who underwent percutaneous tenotomy using the Tenex Health TX System. The patients had failed an average of 5.8 (range 4 to 8) conservative treatments over an average period of 18 months. Patients were treated with the Tenex Health TX System in an out-patient setting with a mean energy time for cutting of the targeted tissue of 4 minutes and 24 seconds. There were no procedure or patient related complications. After completion of the procedure, patients were placed in a walking boot for one week. Patients were evaluated one week, one month and periodically up to 16 months after the procedure. Of the 26 patients treated, 23 (88.5%) described pain relief from the procedure and 24 (92.3%) would have the procedure done again or recommend the procedure. Ultrasound guided percutaneous tenotomy with the Tenex Health TX System is a safe and minimally-invasive alternative that can be used before proceeding to a more invasive open procedure.

October 2014

Connor Moore, Cathy Pinegar, Gregory Yanish. Percutaneous Ultrasonic Tenotomy with Ultrasound Guidance vs. Open Lateral Epicondylectomy: A Prospective Cost Comparative Analysis (submitted for publication)

Chronic lateral epicondylitis remains a significant problem in our working and recreational patients. Numerous interventions have been described with variable effectiveness. To date, there has not been a comparison of the cost effectiveness of definitive treatment when non operative measures have failed. This study aims to evaluate the cost effectiveness of the Tenex Health TX MicroTip surgical instrument when used to perform a percutaneous tenotomy procedure using ultrasound guidance as compared to standard open lateral epicondylectomy. A total of 45 patient diagnosed with lateral epicondylitis and treated by either the ultrasound guided percutaneous tenotomy approach or open lateral epicondylectomy were evaluated. Additional data not found within medical records was obtained by patient contact via telephone. Data for all patients includes information regarding the costs of: surgery center fees, anesthesia fees, ultrasound, MRI, custom brace/splint, work weeks missed, post-operative physical therapy, in-office visits, post-operative injections, as well as patient satisfaction with the procedure overall. Data revealed a statistically significant difference in the number of post-operative visits between the percutaneous tenotomy and open epicondylectomy groups (2.5 and 4.25, respectively; $p < 0.0001$). The average number of work weeks missed was shown to be 1.1 in the TENEX group as compared to 8.18 in the open surgery group, again showing statistically significant differences ($p < 0.0001$). Adding the total reimbursements and cost of work missed, the use of the TX MicroTip in the percutaneous tenotomy procedure, for the purposes of this study, showed to be an average of \$11,753.62 less expensive than the open epicondylectomy procedure. This study reveals a promising new technology utilizing ultrasonic energy to complete a percutaneous tenotomy using the Tenex Health TX System which reduces costs by 120% while maintaining an effectiveness as measured by pain relief of 90%.

Mihir Patel and Jake Daynes, Treatment of painful plantar fibromas with the Tenex Health TX System (submitted for publication)

Objective: Painful plantar fibromas may make ambulation difficult for patients. Treatment modalities may include conservative care, modified shoe wear and orthotics. Surgical treatment may include open excision. In this study, the Tenex Health TX System is a surgical instrument designed to deliver ultrasonic energy for soft tissue cutting was evaluated as a treatment modality for these painful lesions.

Methods: Eight consecutive patients who had painful plantar fibromas elected to undergo treatment for the fibromas using Tenex Health TX.. They all had had conservative care including modifications of shoes and either over the counter orthotics or custom orthotics. They all had advanced imaging tests (MRI or CT) preoperatively to help delineate the lesions. Treatment with the Tenex Health TX System was delivered in a percutaneous fashion in an outpatient setting. Excised tissue specimens were sent to pathology to confirm fibrotic tissue and no malignancy. Preoperative and postoperative AOFAS scores were obtained for quality of life assessment. Physical therapy was offered to patients postoperatively.

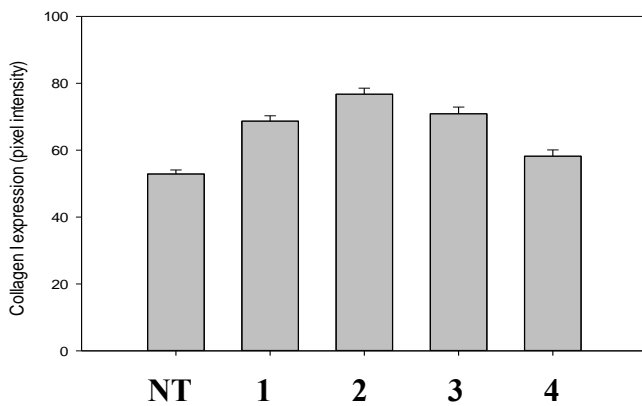
Results: Average age of patient was 51.3 years (17-71). Average time of painful symptoms was 15.1 months (3-36). All patients had had modified footwear or orthotics and no appearance of malignancy by tissue imaging. Preoperative AOFAS score improved from 30.8 (20-36) to 90.1 (85-92). Average time of resolution of symptoms was 63.5 days (30-112). One patient had a recurrence but it was in a different location than the index operation. No others have had a recurrence to date. Pathology specimens were all negative for malignancy. All patients were discharged from care and no infections were recorded. Three of eight patients underwent physical therapy and were discharged from physical therapy successfully.

Conclusion: The Tenex Health TX System appears to be an effective for removing painful plantar fibromas in patients who have failed all conservative measures.

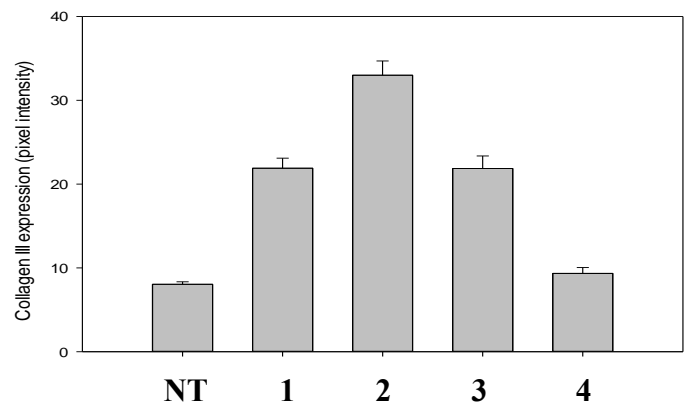
Srinath Kamineni, Ultrasonic Therapy To Promote Healing In Collagenase-Induced Achilles Tendinopathy In A Rabbit Model (submitted for publication)

Tendonosis is a common clinical pathology, with mixed treatment results, especially when chronic. Localization and treatment of a tendinopathic lesion by a non-invasive technique affords an opportunity for precise and a well-tolerated intervention. Treatment of such lesions by focused ultrasonic energy designed to cut and remove the necrotic tendon tissue is a novel and attractive treatment modality. In this study, we report the results of an ultrasonic treatment to promote healing of Achilles tendonosis, in a rabbit model. Mature female New Zealand White rabbits (n= 24) were treated by ultrasonography-guided injection of 0.150 ml of collagenase injected into the central region of the achilles tendon. The contralateral tendons were used as non-operative controls. A subset of the rabbits with the collagenase-induced Achilles tendonosis were exposed to an ultrasound guided percutaneous tenotomy of the hypoechoic region consistent with degenerated tendon tissue using the Tenex Health TX system. The rabbits were sacrificed at 1 and 3 weeks after treatment. The achilles tendons were harvested and these were subjected to biochemical (collagen content) and histological assessment. Histopathological examination revealed that tendons injected with collagenase showed focal areas of hypercellularity, loss of normal tissue architecture, and regions of tendon disorganization and degeneration, when compared to control tendons. Collagenase induced tendinopathy resulted in significantly greater detection of collagens I and III, with a decrease in detection of Collagen X. In animals treated with the TX System, expression of collagens I, III, and X, returned to levels similar to a normal tendon. In conclusion, tendinopathic lesions demonstrated higher detectable quantities of collagen I and III, which qualitatively normalized 3 weeks following ultrasonic treatment with the Tenex Health TX System of the degenerative lesion. These early results are encouraging for the consistent treatment of a chronic tendinopathic lesion, based on the cutting and removal of degraded tendon material.

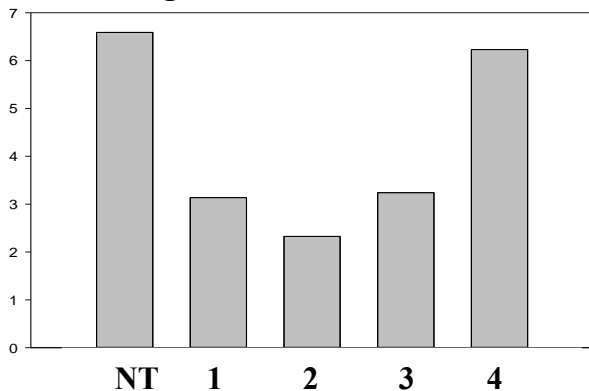
Collagen I



Collagen III



Collagen X



NT: Normal Tendon

Group 1: Tendon analysis 1 wk after collagenase

Group 2: Tendon analysis 3 wk after collagenase

Group 3: Tendon analysis 1 wk after collagenase and TX1

Group 4: Tendon analysis 3 wk after collagenase and TX1

Note: TX1 treatment was performed 1 week after collagenase injection