

Technical Note With Video Illustration

Arthroscopic Trans-capsular Axillary Nerve Decompression: Indication and Surgical Technique

Peter J. Millett, M.D., M.Sc., and Trevor R. Gaskill, M.D.

Abstract: Symptomatic axillary nerve compression is rare yet results in debilitating pain, weakness, and decreased athletic performance in some patients. If nonoperative modalities fail, surgical intervention is necessary to reduce symptoms and avoid functional decline. Traditionally, open techniques have been described to decompress the axillary nerve and are reported to provide satisfactory results. Similar to suprascapular nerve decompression, recent advances have provided the opportunity to develop all-arthroscopic axillary nerve decompression techniques. Although direct comparisons between open and arthroscopic techniques do not exist, arthroscopic axillary nerve decompression may provide some benefits over open techniques. Therefore we present a technique and early results for all-arthroscopic trans-capsular axillary nerve decompression.

The deltoid and teres minor are critical for normal shoulder function and are innervated by the axillary nerve. Compression of the axillary nerve can result in pain, weakness, and atrophy in some patients.^{1,2} Humeral osteophytes, malignancies, hypertrophied musculature, malunited scapular fractures, and fibrous bands in quadrilateral space syndrome have all been identified as causes of axillary nerve compression (Table 1).¹⁻⁸ Although axillary nerve compression is infrequent, accurate and timely diagnosis is critical to prevent chronic atrophy and weakness of the shoulder girdle.

When axillary nerve compression is present, pa-

tients often describe posterior shoulder pain, weakness, and decreased athletic performance.^{2,9} In chronic cases, deltoid atrophy and weakness may be present on examination.² Magnetic resonance imaging can be useful to confirm the diagnosis by showing neurogenic edema or fatty infiltration of the deltoid or teres minor.¹⁰⁻¹² It also provides the opportunity to evaluate soft-tissue causes of compression and the presence of concomitant shoulder pathology.¹⁰

The indications for axillary nerve decompression are not completely defined and continue to evolve. For this reason, the initial treatment of patients diagnosed with axillary nerve compression is usually nonoperative.^{9,13,14} Patients are directed to discontinue aggravating activities, and a general shoulder rehabilitation program is initiated that includes shoulder strengthening and scapular stabilization exercises. Failure to improve over a 3- to 6-month period or the presence of large compressive lesions may necessitate surgical intervention. Arthroscopic axillary nerve decompression is a novel procedure that we have primarily used to treat recalcitrant quadrilateral space syndrome and as a joint preservation procedure in young patients with large impinging humeral osteophytes.

Axillary nerve decompression is traditionally described using open surgical techniques.^{1,2,8} Similar

From The Steadman Philippon Research Institute, Vail, Colorado, U.S.A.

The authors report no conflict of interest.

Received February 19, 2011; accepted May 5, 2011.

Address correspondence to Peter J. Millett, M.D., M.Sc., The Steadman Clinic, 181 W Meadow Dr, Suite 400, Vail, CO 81657, U.S.A. E-mail: drmillett@steadmanclinic.net

*© 2011 by the Arthroscopy Association of North America
0749-8063/11122/\$36.00*

doi:10.1016/j.arthro.2011.05.003

Note: To access the video accompanying this report, visit the October issue of *Arthroscopy* at www.arthroscopyjournal.org.

TABLE 1. Key Points

- Axillary nerve compression can be caused by fibrous bands, scar tissue, or bony abnormalities
- Axillary nerve compression typically presents as posterior or lateral shoulder pain, and chronic cases may result in muscular atrophy
- Though technically demanding, arthroscopic techniques may provide a less invasive method of surgical axillary nerve decompression

to decompression of the suprascapular nerve, recent arthroscopic advances have provided an opportunity to develop all-arthroscopic techniques for axillary nerve decompression. To date, clinical studies directly comparing arthroscopic and open techniques do not exist to our knowledge. Yet, similar to other arthroscopic procedures, it is reasonable to believe that an arthroscopic approach may facilitate visualization, create less soft-tissue disruption, and accelerate rehabilitation. We present a technique for arthroscopic trans-capsular axillary nerve decompression. When performed by experienced shoulder surgeons, it provides a relatively facile method to reliably decompress the axillary nerve.

TECHNIQUE

Arthroscopic axillary nerve decompression can be performed with the patient in either the beach-chair or lateral position, and standard preparation and draping are performed. A standard posterior portal is first made approximately 1 cm medial to and 2 cm inferior

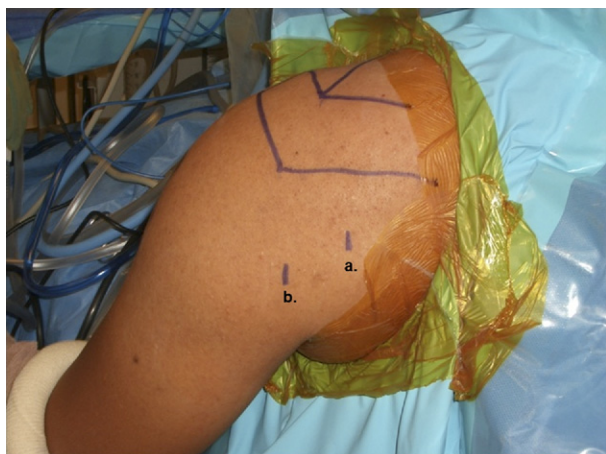


FIGURE 1. Standard posterior viewing portal (a) and posteroinferolateral working portal (b) used to perform trans-capsular axillary nerve decompression, shown in left shoulder viewed from posteriorly in beach-chair position. The posteroinferolateral portal is placed 5 cm inferior to the posterolateral border of the acromion.

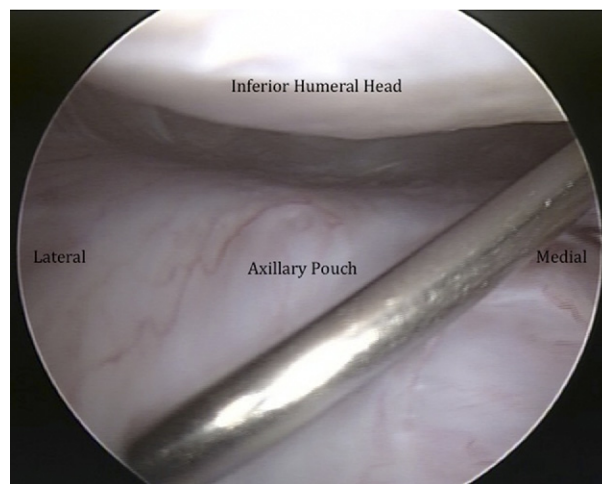


FIGURE 2. A spinal needle is placed at the junction of the medial and central thirds of the inferior capsular pouch, just anterior to the posterior band of the inferior glenohumeral ligament.

to the posterolateral corner of the acromion (Video 1, available at www.arthroscopyjournal.org). A 30° arthroscope is then advanced into the glenohumeral joint, and a full diagnostic arthroscopy is performed. An anterior portal is placed through the rotator interval to address identified articular pathology.

When indicated, the axillary nerve is decompressed by a trans-capsular approach. The inferior glenohumeral recess (axillary pouch) is first visualized from the standard posterior portal. With an 18-gauge spinal needle, a posteroinferolateral portal is localized. This is typically placed approximately 5 cm inferior to and in line with the posterolateral angle of the acromion (Fig 1). The axillary nerve runs from anterior-medial to posterior-lateral as it traverses the axillary space. Therefore the safest area for the spinal needle to enter the inferior recess of the glenohumeral joint is roughly at the junction of the medial and central thirds of the inferior capsular pouch, just anterior to the posterior band of the inferior glenohumeral ligament (Fig 2). Once this portal is appropriately placed, a blunt switching stick is inserted. The portal is then dilated over this switching stick and a 5.5-mm cannula placed to facilitate instrument placement (Fig 3). As debris accumulates, this cannula can be used as a shield to protect soft tissues while an oscillating shaver with suction is used to clear the inferior capsular recess.

While viewing from the standard posterior portal, the surgeon uses a radiofrequency device or handheld biting instruments to perform a capsulotomy, working from posterior near the cannula insertion site to ante-

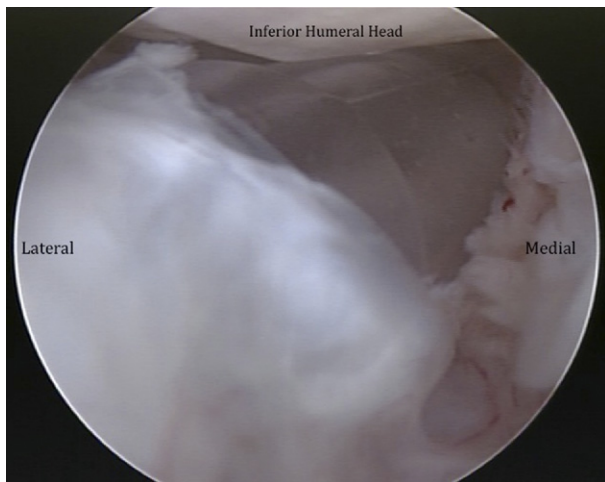


FIGURE 3. After dilation over a switching stick, a 5.5-mm cannula is carefully placed into the inferior capsular recess.

rior (Fig 4). A blunt trocar can be used to gently separate the glenohumeral capsule from underlying soft tissue (Fig 5). A straight biting basket can also be used to carefully open the inferior glenohumeral joint capsule in a posterior-to-anterior direction. The axillary nerve is typically located at the junction of the middle and anterior thirds of the inferior capsular pouch. The long head of the triceps is visualized to ensure that the quadrilateral space has been adequately decompressed. It is not infrequent to identify multiple branches of the axillary nerve as it arborizes toward its innervation sites (Fig 6).

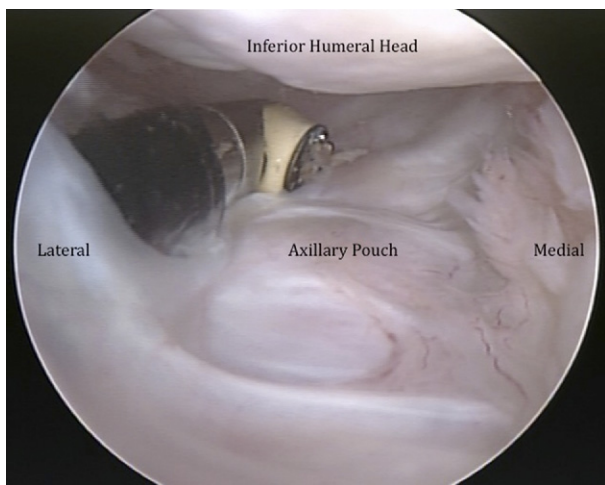


FIGURE 4. A radiofrequency device is used to carefully create an opening in the inferior capsular pouch.

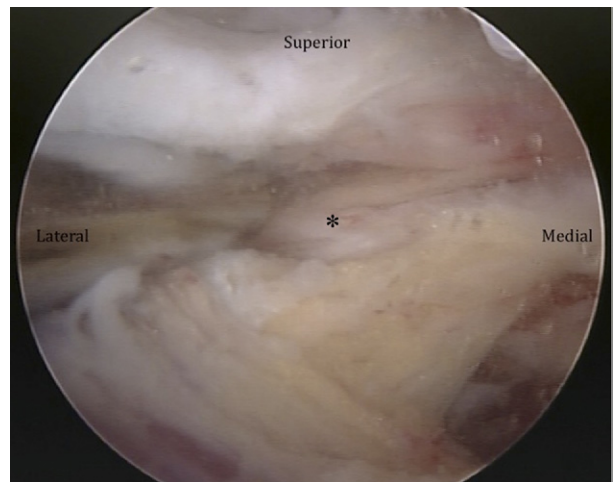


FIGURE 5. A large amount of scar tissue was encountered. With a blunt trocar, it is carefully lifted from the neurovascular bundle (asterisk).

In some patients, a large amount of scar tissue may be present. In these cases the axillary nerve can be closely adherent to the inferior joint capsule, placing the axillary nerve at higher risk for injury. A blunt trocar should be used in these instances to gently tease scar tissue away from the nerve. It is best to work from proximal to distal along the course of the nerve to prevent iatrogenic injury. Hemostasis is maintained with adequate pump pressure, relative anesthetic hypotension, and judicious use of a thermal device.

Decompression is adequate when the axillary nerve

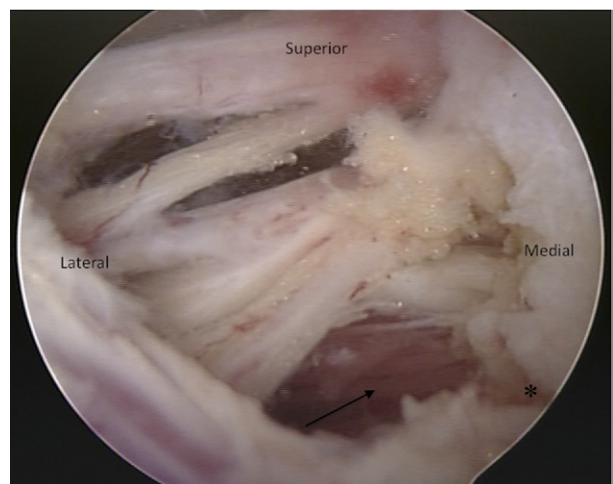


FIGURE 6. The axillary nerve branches and the accompanying neurovascular bundle are completely exposed. One should note arborization of the axillary nerve, as well as the long head of the triceps (asterisk) and teres major (arrow) musculature.

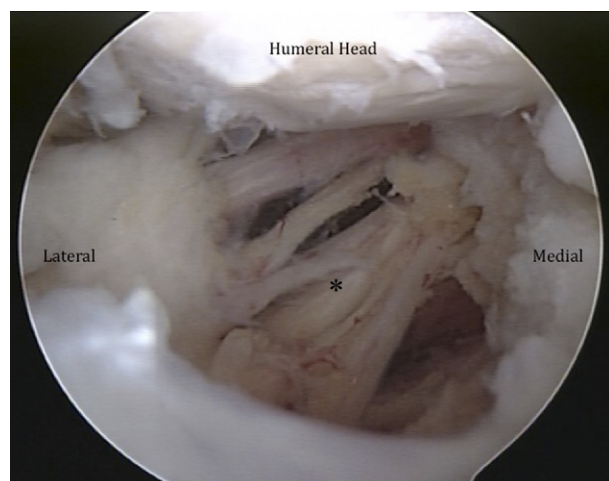


FIGURE 7. Completed trans-capsular axillary nerve neurolysis. The asterisk shows the axillary neurovascular bundle.

is easily visualized within the inferior pouch and no soft tissue remains tethering the nerve at its proximal or distal extent (Fig 7). The pump pressure is reduced and hemostasis is ensured before removal of arthroscopic equipment. The portals are closed in a standard fashion.

PRELIMINARY RESULTS

From January to December 2010, we performed 9 arthroscopic trans-capsular axillary nerve decompressions because of recalcitrant posterior or lateral shoulder pain in 8 patients. The mean age of these patients was 52 years (range, 37 to 72 years) at the time of surgery. All patients presented with severe posterior or lateral shoulder pain, and at a mean of 3 months (range, 1 to 8 months) postoperatively, all patients reported decreased pain and improved shoulder function and were highly satisfied with their surgical outcome. Recurrent symptoms developed 3 months postoperatively in 1 patient after initially having complete symptomatic relief, and after revision axillary nerve decompression, this patient reported satisfactory symptomatic relief. In addition, in 1 patient posterior capsular tightness developed, which is improving with physical therapy. No iatrogenic axillary nerve injury or other major complications have occurred (Table 2).

DISCUSSION

Safe arthroscopic decompression of the axillary nerve requires a detailed knowledge of the axillary

nerve anatomy. The axillary nerve is accompanied by the posterior humeral circumflex artery and vein. This artery arises from the axillary artery at the lower border of the subscapularis and runs posteriorly through the quadrilateral space before anastomosing with the anterior humeral circumflex artery.

The axillary nerve is a branch of the posterior cord of the brachial plexus. It passes medial and inferior to the coracoid and winds, just inferior to the subscapularis muscle belly, as it enters the axillary space. From this location, it traverses inferior to the glenohumeral capsule to enter the quadrilateral space.¹⁵ As the axillary nerve courses inferior to the glenohumeral capsule, it arborizes, forming several smaller branches near the long head of the triceps insertion. The more anterior branch wraps around the humeral neck and innervates the middle and anterior deltoid. The posterior branch is typically responsible for posterior deltoid innervation and gives rise to a branch innervating the teres minor. A cutaneous branch also usually arises from the posterior branch and serves the joint capsule and lateral shoulder.¹⁶

It is apparent from cadaveric studies that the axillary nerve runs in close proximity to the glenohumeral capsule. From the inferior glenoid rim, the axillary neurovascular bundle can be within 10 to 25 mm.¹⁶⁻¹⁸ Its proximity to the inferior capsular recess, however, may be 3 mm or less and may vary by arm position.^{19,20} Therefore the surgeon must dissect the inferior glenohumeral capsule cautiously, expecting to encounter multiple branches and with the understanding that the nerve may be adherent to the overlying capsule.

Decompression of the axillary nerve using an open technique has been reported by a number of authors with satisfactory outcomes.^{1,2,8,14} The etiology of axillary nerve compression is thought to be the result of fibrous bands, muscular hypertrophy, venous distention, or space-occupying lesions such as labral cysts, neoplastic processes, or large humeral bone lesions.^{6,8} These lesions have been decompressed through a posterior approach with lateral reflection of the deltoid. The insertion of the teres minor can be detached as necessary to provide visualization and facilitate de-

TABLE 2. Surgical Risks

- Axillary fluid extravasation
- Iatrogenic injury to axillary nerve
- Incomplete axillary nerve decompression
- Re-formation of scar tissue

compression. In a series by Cahill and Palmer,¹ 16 of 18 patients reported dramatic or complete symptomatic relief after this procedure. More recently, McAdams and Dillingham⁸ reported on 4 overhead athletes with quadrilateral space syndrome. Each patient was able to return to full activities without pain at 12 weeks postoperatively. Smaller case reports have also documented successful surgical outcomes.^{2,3,14}

These reports show that surgical decompression can be successful in patients with quadrilateral space syndrome when nonoperative measures fail to sufficiently relieve symptoms. Though technically challenging, this arthroscopic axillary nerve decompression technique provides a less invasive method of decompression in patients with large inferior humeral osteophytes or in patients diagnosed with quadrilateral space syndrome. Analogous to arthroscopic suprascapular nerve decompression, arthroscopic axillary nerve decompression has the potential to decrease surgical morbidity as compared with open procedures and may facilitate accelerated rehabilitation protocols. It will be necessary to compare open procedures with arthroscopic techniques to determine whether the efficacy of arthroscopic decompression is equivalent to reported outcomes of open decompression techniques.

Axillary nerve compression is a rare cause of shoulder dysfunction. Nevertheless, the ability to make a timely diagnosis is critical to prevent significant muscular atrophy of the deltoid and teres minor especially in overhead athletes. Though technically challenging, arthroscopic axillary nerve decompression provides excellent visualization, may decrease the morbidity associated with open surgical decompression, and could accelerate postoperative rehabilitation. An all-arthroscopic technique to decompress the axillary nerve is therefore described.

REFERENCES

1. Cahill BR, Palmer RE. Quadrilateral space syndrome. *J Hand Surg Am* 1983;8:65-69.
2. Francel TJ, Dellon AL, Campbell JN. Quadrilateral space syndrome: Diagnosis and operative decompression technique. *Plast Reconstr Surg* 1991;87:911-916.
3. McClelland D, Hoy G. A case of quadrilateral space syndrome with involvement of the long head of the triceps. *Am J Sports Med* 2008;36:1615-1617.
4. Robinson P, White LM, Lax M, Salonen D, Bell RS. Quadrilateral space syndrome caused by glenoid labral cyst. *AJR Am J Roentgenol* 2000;175:1103-1105.
5. Amin MF, Berst M, el-Khoury GY. An unusual cause of the quadrilateral space impingement syndrome by a bone spike. *Skeletal Radiol* 2006;35:956-958.
6. Cirpar M, Gudemez E, Cetik O, Uslu M, Eksioglu F. Quadrilateral space syndrome caused by a humeral osteochondroma: A case report and review of literature. *HSS J* 2006;2:154-156.
7. Ishima T, Usui M, Satoh E, Sakahashi H, Okamura K. Quadrilateral space syndrome caused by a ganglion. *J Shoulder Elbow Surg* 1998;7:80-82.
8. McAdams TR, Dillingham MF. Surgical decompression of the quadrilateral space in overhead athletes. *Am J Sports Med* 2008;36:528-532.
9. Ligh CA, Schulman BL, Safran MR. Case reports: Unusual cause of shoulder pain in a collegiate baseball player. *Clin Orthop Relat Res* 2009;467:2744-2748.
10. Elsayes KM, Shariff A, Staveteig PT, et al. Value of magnetic resonance imaging for muscle denervation syndromes of the shoulder girdle. *J Comput Assist Tomogr* 2005;29:326-329.
11. Linker CS, Helms CA, Fritz RC. Quadrilateral space syndrome: Findings at MR imaging. *Radiology* 1993;188:675-676.
12. Sanders TG, Tirman PF. Paralabral cyst: An unusual cause of quadrilateral space syndrome. *Arthroscopy* 1999;15:632-637.
13. Hoskins WT, Pollard HP, McDonald AJ. Quadrilateral space syndrome: A case study and review of the literature. *Br J Sports Med* 2005;39:e9.
14. Lester B, Jeong GK, Weiland AJ, Wickiewicz TL. Quadrilateral space syndrome: Diagnosis, pathology, and treatment. *Am J Orthop (Belle Mead NJ)* 1999;28:718-722, 725.
15. Duparc F, Bocquet G, Simonet J, Freger P. Anatomical basis of the variable aspects of injuries of the axillary nerve (excluding the terminal branches in the deltoid muscle). *Surg Radiol Anat* 1997;19:127-132.
16. Yoo JC, Kim JH, Ahn JH, Lee SH. Arthroscopic perspective of the axillary nerve in relation to the glenoid and arm position: A cadaveric study. *Arthroscopy* 2007;23:1271-1277.
17. Ball CM, Steger T, Galatz LM, Yamaguchi K. The posterior branch of the axillary nerve: An anatomic study. *J Bone Joint Surg Am* 2003;85:1497-1501.
18. Price MR, Tillett ED, Acland RD, Nettleton GS. Determining the relationship of the axillary nerve to the shoulder joint capsule from an arthroscopic perspective. *J Bone Joint Surg Am* 2004;86:2135-2142.
19. Bryan WJ, Schauder K, Tullos HS. The axillary nerve and its relationship to common sports medicine shoulder procedures. *Am J Sports Med* 1986;14:113-116.
20. Uno A, Bain GI, Mehta JA. Arthroscopic relationship of the axillary nerve to the shoulder joint capsule: An anatomic study. *J Shoulder Elbow Surg* 1999;8:226-230.