

# Association Between Acromial Index and Outcomes Following Arthroscopic Repair of Full-Thickness Rotator Cuff Tears

James B. Ames, MD, MSc, Marilee P. Horan, MPH, Olivier A.J. Van der Meijden, MD,  
Melissa J. Leake, ATC, and Peter J. Millett, MD, MSc

*Investigation performed at the Steadman Philippon Research Institute, Vail, Colorado*

**Background:** The purposes of this study were to evaluate the association between the acromial index and full-thickness rotator cuffs and to determine if the size of the acromial index was associated with outcomes in a cohort of patients who had had arthroscopic repair of full-thickness rotator cuff tears.

**Methods:** The acromial index was calculated for three groups by individual researchers: 115 patients (120 shoulders) who had arthroscopically repaired full-thickness rotator cuff tears without osteoarthritis (Group I); sixty-four patients (sixty-eight shoulders) who had intact rotator cuffs with osteoarthritis (Group II); and twenty-one patients (twenty-one shoulders) who had intact rotator cuffs, without osteoarthritis, and were managed for other pathology (Group III). The acromial index is the distance between the glenoid plane and the lateral border of the acromion divided by the distance between the glenoid plane and the lateral aspect of the humeral head. Ninety-two patients (ninety-three shoulders) from Group I met inclusion criteria for subjective follow-up. Minimum two-year subjective data were obtained on 86% (seventy-nine patients [eighty shoulders]) of these ninety-two patients to determine the association of the acromial index on surgical outcomes. Surgical factors were also analyzed. Significance was set at  $p < 0.05$ .

**Results:** The acromial index demonstrated high intraobserver agreement (kappa, 0.960; 95% confidence interval, 0.940 to 0.984) and high interobserver agreement (kappa, 0.960; 95% confidence interval, 0.922 to 0.979). The mean acromial index (and standard deviation) was  $0.687 \pm 0.08$  for Group I,  $0.685 \pm 0.11$  for Group II, and  $0.694 \pm 0.07$  for Group III. No significant differences were found. At an average duration of follow-up of 3.0 years (range, 2.0 to 5.4 years), the mean American Shoulder and Elbow Surgeons scores improved from 59 to 93 points ( $p = 0.001$ ) in the seventy-nine patients from Group I who had minimum two-year duration of subjective follow-up. The mean postoperative scores were 10.4 points (range, 0 to 54.5 points) for the Quick Disabilities of the Arm, Shoulder and Hand Outcome Measure and 9.2 points (on a scale of 1 to 10 points) for patient satisfaction. When the patients with a large acromial index ( $>0.682$ ) were compared with those with a small acromial index ( $\leq 0.682$ ), the patients in the former group had a greater likelihood of having a tear involving two or more rotator cuff tendons ( $p = 0.017$ ), required more anchors to achieve repair ( $p = 0.007$ ), had slightly lower patient satisfaction scores (mean, 8.9 compared with 9.5 points;  $p = 0.055$ ) and Short Form-12 Physical Component Summary scores (mean, 49.1 compared with 55.2 points;  $p = 0.04$ ), and had higher Quick Disabilities of the Arm, Shoulder and Hand scores (mean, 12.9 compared with 7.4 points;  $p = 0.042$ ).

**Conclusions:** An association between the size of the acromial index and that of full-thickness rotator cuff tears was not confirmed; however, a larger acromial index was associated with an increased number of tendons torn and anchors used for repair. In addition, patients with a larger acromial index had more disability as recorded by the Quick Disabilities of the Arm, Shoulder and Hand Outcome Measure and poorer physical health as measured by the Short Form-12 Physical Component Summary score.

**Disclosure:** None of the authors received payments or services, either directly or indirectly (i.e., via his or her institution), from a third party in support of any aspect of this work. One or more of the authors, or his or her institution, has had a financial relationship, in the thirty-six months prior to submission of this work, with an entity in the biomedical arena that could be perceived to influence or have the potential to influence what is written in this work. No author has had any other relationships, or has engaged in any other activities, that could be perceived to influence or have the potential to influence what is written in this work. The complete **Disclosures of Potential Conflicts of Interest** submitted by authors are always provided with the online version of the article.

The pathogenesis of rotator cuff disease remains controversial, with several intrinsic (genetic) and extrinsic (anatomical) causes suggested as possible contributing factors. The theory of extrinsic compression leading to rotator cuff disease was first proposed by Neer<sup>1</sup>. Proposed extrinsic factors in the development of rotator cuff disease include the morphology of the anterior acromion<sup>2</sup>, the lateral acromial angle, the coracohumeral interval, the internal impingement of the posterior rotator cuff on the posterosuperior border of the glenoid, and the glenoid version<sup>1,3-5</sup>. Intrinsic factors associated with rotator cuff tears, encompassing mechanisms occurring within the rotator cuff itself and first proposed by Codman<sup>6</sup> in 1934, include tissue degeneration, alterations in metabolism, and oxidative stress-related change<sup>7-9</sup>.

Many prognostic factors affecting outcomes following full-thickness rotator cuff repairs have been reported. Predictors of poor outcomes include age, tear size, tear chronicity, and fatty infiltration and atrophy of the torn rotator cuff muscle<sup>10-16</sup>.

Recently, an association among the lateral extension of the acromion, the acromial index, and rotator cuff disease has been described<sup>17</sup>. It has been reported that in open rotator cuff repair, a large acromial index is associated with an increased risk of retearing<sup>18</sup>. Combined with the findings of several studies that have shown better subjective and objective results of rotator cuff repair when the tendon has been documented to heal<sup>19-21</sup>, these results have led to a perception that a large acromial index may be a poor prognostic factor following surgical repair of a torn rotator cuff. We recognize that most rotator cuff tears are now repaired arthroscopically. Therefore, we elected to study this relationship in greater detail in arthroscopic rotator cuff repairs.

The objective of the present study was to evaluate the association between acromial index size and rotator cuff tears and to determine if an increasing acromial index is associated with poor outcomes after arthroscopic full-thickness rotator cuff repairs. Our hypotheses were that a large acromial index would have an association with full-thickness rotator cuff tear repair and it would have a negative association with short to intermediate-term outcomes following arthroscopic rotator cuff repair.

## Materials and Methods

### Study Cohort

In this institutional review board-approved study, surgical and subjective data on patients undergoing rotator cuff repair at a sports medicine referral clinic were collected prospectively and were reviewed retrospectively. The senior author (P.J.M.) performed rotator cuff-related procedures on 214 patients from October 2005 through December 2008. Patients were excluded from this study for the following reasons: open cuff repair (thirty-six patients), previous shoulder surgery (seventeen patients), the presence of massive tears that were only debrided (fourteen patients), a rotator cuff tear associated with a proximal humeral fracture (three patients), a repair associated with a prior shoulder replacement (four patients), and repairs requiring allograft augmentation (four patients). In addition, ten patients were excluded from the cohort because of unavailability for a minimum two-year subjective follow-up period: two patients (three shoulders) died, two refused to participate, one was incarcerated, and five required a second surgery (two of whom had revision rotator cuff tear repairs). The acromial index could not be determined in thirty-three of the remaining patients because of inadequate radiographs, inflammatory disease, or morphologic deformity affecting the measurement (e.g., humeral head collapse, glenoid erosion).

Therefore, the final study cohort consisted of ninety-two patients (sixty-two men and thirty women; ninety-three shoulders) with full-thickness rotator cuff tears that were arthroscopically repaired with no evidence at arthroscopy of glenohumeral osteoarthritis. The mean age of this cohort was sixty years (range, thirty-four to seventy-eight years). Intraoperative findings and concomitant pathologies treated at the time of rotator cuff repair were recorded, along with the type of rotator cuff repair, the number of tendons torn, and the number of anchors used for repair. Whenever possible, a double-row repair construct was utilized (SutureBridge or SpeedBridge 4.75mm BioComposite SwiveLock anchors, with FiberTape; Arthrex, Naples, Florida). If there was insufficient cuff tissue for compression with the use of a double row, then a simple single row was utilized. Single-row repairs were used for very small tears in which only a single anchor was used. Side-to-side repairs were used in L-shaped and massive U-shaped tears.

### Measurement of the Acromial Index

The acromial index was calculated with use of the technique described by Nyffeler et al.<sup>17</sup>. Standardized radiographs (anteroposterior views in the plane of the scapula, with the arm in neutral rotation) were made with the patient standing. On an anteroposterior shoulder radiograph, the distance from the glenoid plane to the lateral border of the acromion was divided by the distance from the glenoid plane to the lateral aspect of the humeral head (Fig. 1). All

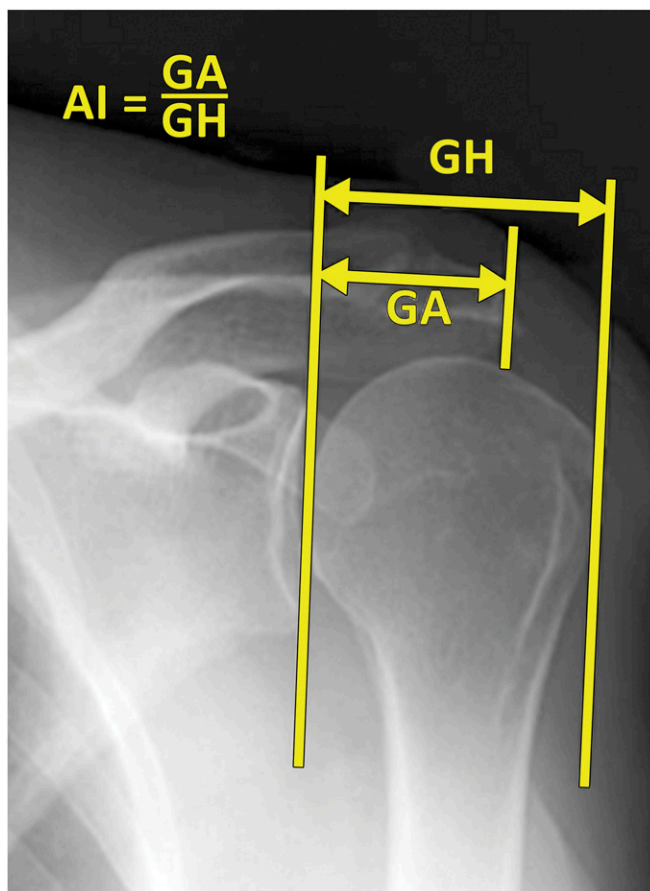


Fig. 1  
Anteroposterior shoulder radiograph showing the calculation of the acromial index (AI) based on the method described by Nyffeler et al.<sup>17</sup>. The acromial index equals the distance from the glenoid plane to the lateral border of the acromion (GA) divided by the distance from the glenoid plane to the lateral aspect of the humeral head (GH).

**TABLE I** Distribution of Surgical Variables Between the Acromial Index Groups

	Small Acromial Index Group ( $\leq 0.682$ ) (N = 47)	Large Acromial Index Group ( $> 0.682$ ) (N = 46)	P Value*
Acromial index†	0.625 (0.611 to 0.639)	0.746 (0.732 to 0.761)	
Male sex	76.6%	58.7%	0.065
Time from injury to surgery‡ (d)	539 (8 to 7366)	779 (3 to 5023)	0.60
SLAP§ lesions (Types II to IV)	29.8%	21.4%	0.075
Biceps tenotomy or tenodesis	59.6%	82.2%	0.029
Acromial morphology			0.412
Type I	7.1%	11.6%	
Type II	71.4%	76.7%	
Type III	21.4%	11.6%	
Supraspinatus and infraspinatus tears	27.6%	52.2%	0.016
Subscapularis tears	10.6%	17.0%	0.348
Repairs			0.123
Side-to-side	4.3%	0.0%	
Single-row	17.0%	4.3%	
Double-row	61.7%	78.3%	
Double-row and side-to-side	17.0%	17.4%	
Anchors			0.007
Fewer than three	17.4%	2.2%	
Three	39.1%	26.1%	
More than three	43.5%	71.7%	

\*The level of significance was set at  $p < 0.05$ . †The values are given as the mean, with the 95% CI in parentheses. ‡The values are given as the mean, with the range in parentheses. §SLAP = superior labral anterior-posterior.

acromial index measurements were performed in October 2010. The researchers performing the measurements did not have any knowledge of the size of the rotator cuff tears, the occurrence of any surgical difficulties, or the findings at the time of the latest follow-up. For additional analysis, the acromial index was dichotomized on the basis of the median acromial index to have equal groups. Forty-seven patients (forty-seven shoulders) were assessed as having a small acromial index ( $\leq 0.682$ ), and forty-five patients (forty-six shoulders) were assessed as having a large acromial index ( $> 0.682$ ) (Table I).

### Acromial Index Comparison Groups

To confirm the results of published reports<sup>17,18</sup>, the acromial index was calculated for 115 patients (120 shoulders) and compared with two additional groups of patients with different pathology. The first comparison group (Group II) consisted of sixty-four patients (sixty-eight shoulders) who had surgically confirmed osteoarthritis (changes from Outerbridge Grades III to IV<sup>22</sup>) and a surgically proven intact rotator cuff. The second comparison group (Group III) consisted of twenty-one patients (twenty-one shoulders) assessed with biceps and/or labral pathology who had surgically proven intact rotator cuffs with no osteoarthritis (Fig. 2 and Table II). This analysis was done to evaluate the previously reported association between a large acromial index and rotator cuff disease<sup>17,18</sup>.

### Measurement Validity

The reproducibility of the acromial index measurement was examined with the intraclass correlation coefficient for both interobserver reliability (measurements made by different observers) and intraobserver reliability (measurements repeated at different points in time by the same observer) for repeated

measurements. For the first fifty patients, two independent observers calculated the acromial index (J.B.A. and M.J.L.). In addition, one observer (M.J.L.) repeated these calculations after a one-month interval. The remaining calculations were made by a single observer (J.B.A.).

### Outcome Parameters

Patient outcomes for the study cohort were measured with the validated shoulder-specific outcome measures: the American Shoulder and Elbow Surgeons (ASES) score (in which 100 points denotes the best score possible)<sup>23</sup>, the Quick Disabilities of the Arm, Shoulder and Hand (QuickDASH) score<sup>24</sup> (in which 0 denotes the best score possible), and a validated general health

**TABLE II** Acromial Indices and Patient Demographic Characteristics per Study Group

	Acromial Index*	Age* (yr)	Male Sex
Group I†	0.687 $\pm$ 0.08	60 $\pm$ 9.6	69%
Group II‡	0.685 $\pm$ 0.11	61 $\pm$ 8.5	62%
Group III§	0.694 $\pm$ 0.07	53 $\pm$ 9.2	71%

\*The values are given as the mean and the standard deviation. †Group I consisted of 115 patients (120 shoulders). ‡Group II consisted of sixty-four patients (sixty-eight shoulders). §Group III consisted of twenty-one patients (twenty-one shoulders).

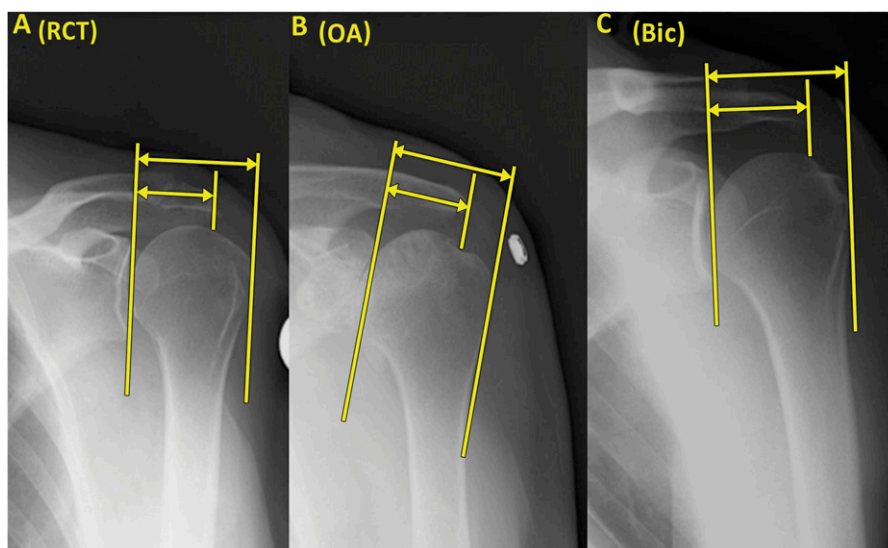


Fig. 2  
Radiographs showing examples of acromial indices for Group I (the rotator cuff tear [RCT] group) (Fig. 2-A), Group II (the osteoarthritis [OA] group) (Fig. 2-B), and Group III (the biceps [Bic] and/or labral pathology group) (Fig. 2-C).

questionnaire, Short Form-12 (SF-12)<sup>25</sup>, which included SF-12 Physical Component Summary (SF-12 PCS) and SF-12 Mental Component Summary (SF-12 MCS). In addition, data on patient satisfaction with surgical outcome (a 10-point visual analog scale in which 10 points denotes very satisfied and 1 point denotes very unsatisfied) were collected<sup>26,27</sup>.

### Statistics

Statistical data analysis was done with use of the Statistical Package (SPSS) version 11.0 (SPSS, Chicago, Illinois). Intraclass correlation was measured with use of the kappa coefficient. The preoperative SF-12 PCS, SF-12 MCS, and ASES scores were normally distributed. Comparisons of these scores between the large acromial index group and the small acromial index group were done with use of the independent t test. The postoperative QuickDASH, ASES, SF-12 MCS, SF-12 PCS, and patient satisfaction scores were not normally distributed. These scores were compared between the large acromial index group and the small acromial index group with use of the Mann-Whitney U test. For analysis of the dichotomized variables, bivariate chi-square tests were used.

The level of significance for statistical analysis was set at  $p < 0.05$ .

### Source of Funding

There was no external funding source for this study.

### Results

The measurement of the acromial index had high agreement<sup>28</sup>, both for intraobserver (kappa, 0.960 [95% confidence interval (CI), 0.940 to 0.984] and interobserver (kappa, 0.960 [95% CI, 0.922 to 0.979]). No significant difference in acromial index was found between the groups; however, the analyses lacked statistical power (Fig. 3).

All ninety-three shoulders in Group I had a full-thickness tear of the supraspinatus tendon; in addition, thirty-seven had a full-thickness tear of the infraspinatus tendon and thirteen had a full-thickness tear of the subscapularis tendon. Eight of these thirteen subscapularis tears were located in the upper one-third of the tendon.

Seventy-six cuff repairs were performed with use of anchors with a double-row interconnected bridging configuration<sup>29</sup>. Fifteen other cuff repairs were single-row or single-anchor repairs. Sixteen of these ninety-one cuff repairs were performed in conjunction with side-to-side suture repair. Only two cuff repairs were isolated side-to-side repairs. Twenty-three shoulders underwent no treatment of the long head of the biceps tendon, five underwent debridement, eight underwent tenotomy, and fifty-seven underwent tenodesis.

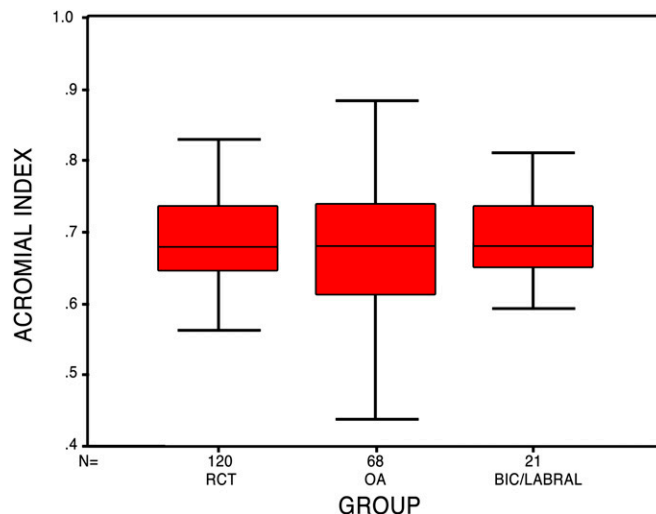


Fig. 3  
Box plot representing the average acromial index per study group. The horizontal line indicates the median, the box extends from the 25th to the 75th percentile, and the bars indicate the largest and smallest observed values. RCT = rotator cuff tear group, OA = osteoarthritis group, and Bic/Labral = bicep and/or labral pathology group.

TABLE III Postoperative Outcomes per Acromial Index Group with Normative Data for Each Score

Postoperative Scores	Small Acromial Index Group ( $\leq 0.682$ )* (points)	Large Acromial Index Group ( $> 0.682$ )* (points)	Published Normalized Data† (points)	P Value‡
ASES	93.5 (33 to 100)	91.9 (50 to 100)	92.2 ± 14.5 <sup>41</sup>	0.179
QuickDASH	7.4 (0 to 54)	12.9 (0 to 45)	10.10 ± 14.68 <sup>42</sup>	0.042
SF-12 PCS	55.2 (37.5 to 63.6)	49.1 (27.5 to 59.4)	46.9 <sup>25</sup>	0.04
Patient satisfaction	9.5 (1 to 10)	8.9 (1 to 10)	9.0 <sup>27</sup> (1 to 10)	0.055

\*The values for the ASES, QuickDASH, SF-12 PCS, and patient satisfaction are given as the mean, with the range in parentheses. †The values for the ASES and QuickDASH are given as the mean and the standard deviation. The value for the SF-12 PCS is given as the mean. The value for normalized patient satisfaction is given as the median, with the range in parentheses. ‡The level of significance was set at  $p < 0.05$ .

Five patients in Group I underwent reoperations. Two patients had documented failure of the rotator cuff repair. The acromial indices for these patients were 0.718 and 0.675. Both patients had supraspinatus and infraspinatus tears, with one also having a tear of the upper one-third of subscapularis; each of these two patients had the initial repair performed with a double-row construct. Both patients underwent rotator cuff augmentation surgery at the time of revision. The other three patients had isolated supraspinatus tears repaired with a double-row configuration with a concomitant biceps tenodesis. The acromial indices for these three patients were 0.691, 0.768, and 0.731. Of these three patients, two also underwent surgical treatment for stiffness and one had release of a suprascapular nerve entrapment. No difference was found in the mean acromial index between patients who required a second procedure and those who did not (0.717 compared with 0.682) ( $p = 0.207$ ).

When the acromial index was analyzed as a continuous variable, a larger acromial index was significantly associated ( $p < 0.017$ ) with an increasing number of tendons torn. In addition, an odds ratio showed that patients with a large acromial index ( $> 0.682$ ) were 2.6 times (95% CI, 1.0 to 6.9 times) more likely to have two or more tendons torn compared with patients with a small acromial index ( $\leq 0.682$ ). Patients in the large acromial index group had a significantly greater ( $p = 0.007$ ) number of anchors inserted to achieve repair of the tear when compared with the small acromial index group (4.1 compared with 2.98 anchors per repair). Patients in the large acromial index group were more likely to undergo a biceps tenotomy or tenodesis than those in the small acromial index group ( $p = 0.029$ ). No other surgical variables (injured shoulder, labral lesions, instability, chondral damage, acromioclavicular morphology, subscapularis tears, coracoid impingement, repair type [anchors, side-to-side, double row, or single row]) were associated with acromial index size, showing homogeneity between the groups.

Minimum two-year subjective data were obtained on seventy-nine patients (eighty shoulders) from the study cohort of ninety-two patients (ninety-three shoulders) for a follow-up rate of 86%. The average subjective duration of follow-up for these patients was 3.0 years (range, 2.0 to 5.4 years). For the

cohort as a whole, the mean ASES score significantly improved ( $p < 0.001$ ) from 59 to 93 points. At the time of the final follow-up examination, the mean QuickDASH score was 10.4 points (range, 0 to 54.5 points). The mean SF-12 PCS score significantly improved ( $p = 0.013$ ) from 44.7 points (range, 25 to 58 points) preoperatively to 52.7 points (range, 28 to 63 points) postoperatively. No significant change was observed in the SF-12 MCS score from 54.8 points (range, 30.7 to 68.4 points) preoperatively to 54.3 points (range, 17.6 to 63.2 points) postoperatively. Both ratings of "pain today" and "worst pain" improved significantly postoperatively ( $p < 0.001$ ). The mean score of patient satisfaction with surgical outcomes was 9.2 points on a scale of 1 to 10 points. None of the individual surgical factors analyzed had a significant association with the scores for QuickDASH, patient satisfaction, or SF-12 PCS.

When the acromial index size was dichotomized, a significant difference was seen in the QuickDASH ( $p = 0.042$ ) and SF-12 PCS ( $p = 0.04$ ) scores, with a trend toward diminished patient satisfaction in the large acromial index group ( $p = 0.055$ ) (Table III).

## Discussion

Contrary to previously published reports, we did not find a significant difference in the acromial index size when patients with full-thickness rotator cuff tears were compared with patients with intact rotator cuffs with or without osteoarthritis. Moreover, as has been shown in other studies, short to intermediate-term outcomes following arthroscopic rotator cuff repair showed significant improvement postoperatively, with an average ASES score of 93 points. At an average follow-up duration of three years, when compared with patients with a small acromial index, patients with a large acromial index had more disability as determined by means of QuickDASH, a lower SF-12 PCS score, and more decreased satisfaction scores. However, despite having lower scores than the small acromial index group, the large acromial index group still achieved excellent clinical results with regard to the scores for ASES, QuickDASH, SF-12 PCS, and patient satisfaction (Table III).

One of the strengths of this study was that it compared patients who had full-thickness rotator cuff tears with those who had surgically proven intact rotator cuff tears. Previous studies

have relied on imaging modalities, including magnetic resonance imaging (MRI) and ultrasound, to establish the competence of the rotator cuff. Although generally accurate, there is still an error rate with any imaging modality<sup>30</sup>. Surgical assessment of the integrity of the rotator cuff at the time of the index arthroscopic surgery provided a more accurate assessment. Our study also compared the acromial index with validated shoulder outcome measures (ASES and QuickDASH scores), a general health questionnaire (SF-12), and patient satisfaction with surgical outcomes, and found excellent clinical results when these measurements were compared with normalized data.

The acromial index was first introduced by Nyffeler et al.<sup>17</sup>. In that study, lateral extension of the acromion was quantified by measuring the acromial index. The average reported acromial index was 0.73 in patients who had full-thickness rotator cuff tears, 0.60 in patients who had osteoarthritis and an intact rotator cuff, and 0.64 in normal control patients who had a rotator cuff that was proven to be intact by means of an ultrasound. Therefore, Nyffeler et al. suggested an association between a larger acromial index with rotator cuff tears and a smaller acromial index with osteoarthritis of the shoulder. The Nyffeler theory regarding the association of a large acromial index and full-thickness rotator cuff tears has been supported by multiple studies<sup>31-33</sup>. In the present study, the median acromial index in our rotator cuff tear group was 0.682 and was used as the cutoff to dichotomize the acromial index, a continuous variable, into large and small groups for ease of use in clinical interpretation. This study shows that a group with a large acromial index has inferior results compared with a group with a small acromial index.

In their original study, Nyffeler et al.<sup>17</sup> proposed a biomechanical theory in which a larger lateral extension of the acromion creates a more vertical ascending force component of the middle deltoid. Consequently, the pressure between the humeral head and the acromion increases, which may lead to subacromial impingement and rotator cuff tears. A smaller lateral extension of the acromion was theorized to result in a more horizontal force vector for the middle deltoid and a higher compression force between the humeral head and the glenoid cavity, favoring the formation of osteoarthritis. In contrast to this theory, in an MRI study of rotator cuff disease, Baechler and Kim<sup>34</sup> found that the percentage of the humeral head not covered superiorly by the anterolateral acromion may be a factor in the pathogenesis of full-thickness rotator cuff tears. Baechler and Kim<sup>34</sup> defined “uncoverage” of the humeral head as the percentage of the humeral head not covered superiorly by the anterolateral acromion. They showed a significantly greater uncoverage in men with a full-thickness rotator cuff tear as compared with those without, essentially the opposite conclusion of Nyffeler et al.<sup>17</sup>. Baechler and Kim theorized that greater uncoverage allows hinging of the humeral head on the anterolateral edge of the acromion during early shoulder abduction, causing impingement of the supraspinatus tendon between these two structures<sup>34</sup>.

Recently, the theoretical relationship between a small acromial index and osteoarthritis was questioned in a report by

Kircher et al.<sup>35</sup>. They calculated the acromial index following the same technique reported by Nyffeler et al.<sup>17</sup> in three groups of patients: those with instability, those with calcifying tendinitis, and those with osteoarthritis. Kircher et al. did not report any correlation between the acromial index and osteoarthritis. In fact, in their analysis, patients with osteoarthritis had an acromial index of 0.73, similar to the acromial index that Nyffeler et al.<sup>17</sup> found in their group of patients with a rotator cuff tear. In addition, Kappe et al.<sup>36</sup> reported that there was no difference in the acromial index of patients who had calcifying tendinitis, partial-thickness rotator cuff tears, or full-thickness rotator cuff tears. In an evaluation of radiographs of patients with rotator cuff tear arthropathy, Middernacht et al.<sup>37</sup> did not find any significant relationship between the location and/or site of the rotator cuff tear and the acromial index.

Miyazaki et al.<sup>38</sup> recently concluded that acromial index size may be a predictor of rotator cuff tears in some populations, but not in others. They found an association between a large acromial index and rotator cuff tears in a Brazilian population, but not in a Japanese population<sup>38</sup>. In addition, Torrens et al.<sup>39</sup> reported that patients in Spain with rotator cuff tears had a significantly larger acromial index of 0.72 compared with 0.68 in patients without cuff pathology, and that there were differences between the sexes. Neither of these findings was significant in our study.

Combined with the findings of Kircher et al.<sup>35</sup> and Miyazaki et al.<sup>38</sup>, our study called into question the biomechanical theory proposed by Nyffeler et al.<sup>17</sup> of the association between a large acromial index and rotator cuff disease and that between a small acromial index and osteoarthritis. These conflicting reports suggest that further, more sophisticated biomechanical research may be needed to evaluate the validity of this theory.

Recently, Zumstein et al.<sup>18</sup> reported that a higher acromial index is associated with a higher rate of retearing following open repair of massive rotator cuff tears. They also confirmed that patients with retears have worse outcomes<sup>18</sup>. Our findings show an increase in the number of tendons torn and a decrease in outcome measures following rotator cuff repairs in patients with a large lateral extension of the acromion. These inferior outcomes were not attributable to the increase in the number of tendons torn in the large acromial index group, as there was no association between the number of tendons torn and our outcome measures.

One limitation of our study was that we did not have imaging follow-up data to assess structural integrity of the repairs. Therefore, it was unclear if the acromial index was associated with retears in our patients or if some other factor was the cause of the diminished outcomes.

Arthroscopic visualization and repair of the rotator cuff in a patient with a large acromial index is technically challenging (Fig. 4-A). One might suspect that the inferior outcomes achieved in patients with large acromial indices were due to less robust repairs in those patients. However, to improve exposures of the repair site over time, the senior surgeon (P.J.M.) had the assistant place a hand on the patient axilla to create a lateral force on the proximal humerus, thereby functionally decreasing the acromial index and restoring visualization

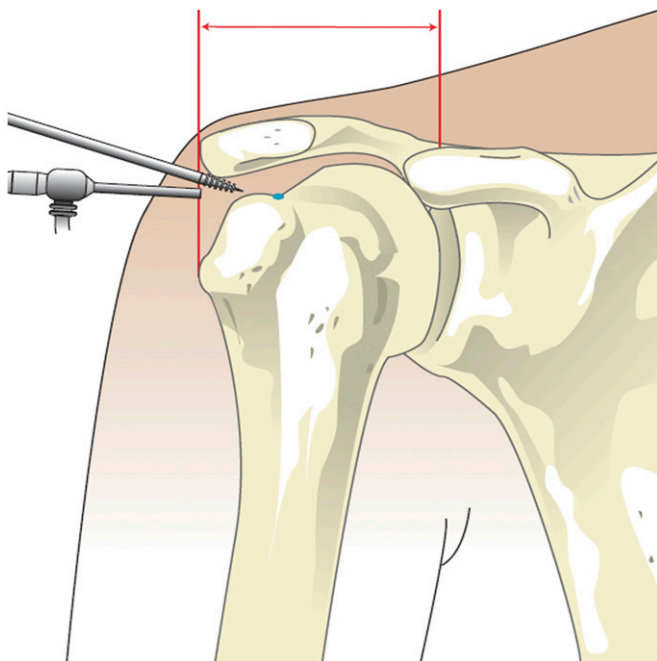


Fig. 4-A

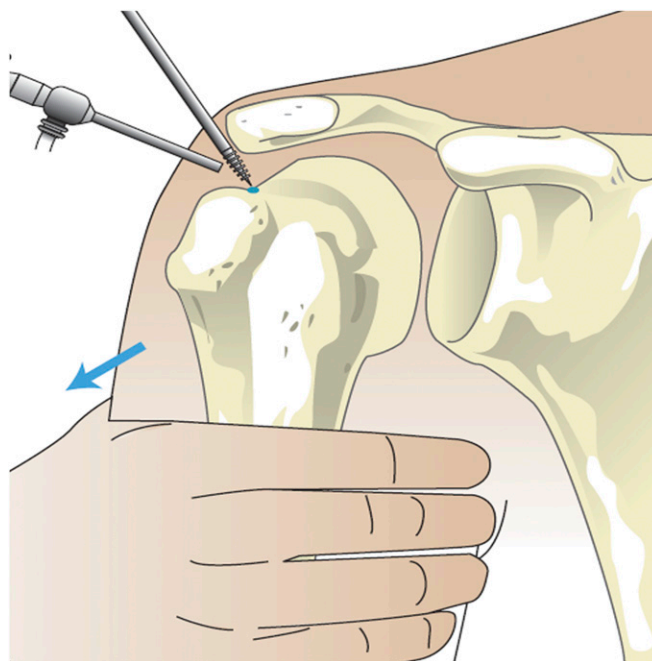


Fig. 4-B

**Fig. 4-A** Illustration showing the technical difficulty of rotator cuff repair visualizing the ideal position for anchor placement at the articular margin (blue dot) in a patient with a large lateral extension of the acromion (red arrow). **Fig. 4-B** Illustration showing the creation of an inferolateral traction force on the proximal humerus (blue arrow) that can decrease the acromial index and restore visualization of the ideal position for anchor placement at the articular margin (blue dot).

(Fig. 4-B). With this technique, we believed that we had adequate visualization in patients with large acromial indices and were able to achieve comparable repairs in patients with small acromial indices.

This study had several limitations that were inherent to a retrospective analysis. The measurements of distances on shoulder radiographs were certainly subject to projection errors arising from patient positioning and direction of the radiographic beam<sup>40</sup>. Inpatient variability of preoperative radiographs was not performed. However, the influence of possible projection errors was limited when considering that the acromial index is expressed as a percentage and is not quantified in a numeric value<sup>17</sup>. Our analysis concluded that there was no significant difference in the size of the acromial index between our shoulder pathology groups, but the analysis was underpowered, which seems to be a factor in many of the recent acromial index papers. We used data from the study by Nyffeler et al.<sup>17</sup> to run an a priori power analysis using their means and standard deviations and determined that thirteen patients were needed in each group for our study to achieve 80% power. We increased our group sizes to more than double the number of patients needed. However, our post hoc analysis among the groups remained underpowered because of our larger standard deviation compared with that of Nyffeler et al.<sup>17</sup>.

We were unable to confirm a significant association between the acromial index and full-thickness rotator cuff tears. However, we did find that in patients with full-thickness rotator cuff tears, a large acromial index was associated with an

increase in the number of tendons torn and the number of anchors required for repair. Patients with full-thickness rotator cuff tears and high acromial indices had more disability as recorded by the QuickDASH and poorer physical health as measured by the SF-12 PCS composite score. Despite higher disability scores and lower physical health scores, patients with a rotator cuff tear and a large acromial index can still expect excellent postoperative satisfaction and increased function following arthroscopic rotator cuff repair.

The routine measurement of the acromial index may assist the treating physician in preparing for the greater technical challenge of managing these patients. In addition, despite a technically sound repair, patients with a large acromial index can expect slightly diminished short to intermediate-term results compared with patients with a small acromial index. ■

James B. Ames, MD, MSc  
Marilee P. Horan, MPH  
Olivier A.J. Van der Meijden, MD  
Steadman Philippon Research Institute,  
181 West Meadow Drive, Suite 1000, Vail, CO 81657

Melissa J. Leake, ATC  
Peter J. Millett, MD, MSc  
The Steadman Clinic, 181 West Meadow Drive,  
Suite 400, Vail, CO 81657.  
E-mail address for P.J. Millett: drmillett@thesteadmanclinic.com

## References

1. Neer CS 2nd. Anterior acromioplasty for the chronic impingement syndrome in the shoulder: a preliminary report. *J Bone Joint Surg Am.* 1972 Jan;54(1):41-50.
2. Bigliani LU, Ticker JB, Flatow EL, Soslowky LJ, Mow VC. The relationship of acromial architecture to rotator cuff disease. *Clin Sports Med.* 1991 Oct;10(4):823-38.
3. Davidson PA, Elattrache NS, Jobe CM, Jobe FW. Rotator cuff and posterior-superior glenoid labrum injury associated with increased glenohumeral motion: a new site of impingement. *J Shoulder Elbow Surg.* 1995 Sep-Oct;4(5):384-90.
4. Jobe CM. Posterior superior glenoid impingement: expanded spectrum. *Arthroscopy.* 1995 Oct;11(5):530-6.
5. Nové-Josserand L, Edwards TB, O'Connor DP, Walch G. The acromioclavicular and coracohumeral intervals are abnormal in rotator cuff tears with muscular fatty degeneration. *Clin Orthop Relat Res.* 2005 Apr;433:90-6.
6. Codman EA. *The shoulder.* Boston: Thomas Todd Co; 1934.
7. Dröge W. Oxidative stress and aging. *Adv Exp Med Biol.* 2003;543:191-200.
8. Hashimoto T, Nobuhara K, Hamada T. Pathologic evidence of degeneration as a primary cause of rotator cuff tear. *Clin Orthop Relat Res.* 2003 Oct;415:111-20.
9. Kannus P, Józsa L. Histopathological changes preceding spontaneous rupture of a tendon. A controlled study of 891 patients. *J Bone Joint Surg Am.* 1991 Dec;73(10):1507-25.
10. Gazielly DF, Gleyze P, Montagnon C. Functional and anatomical results after rotator cuff repair. *Clin Orthop Relat Res.* 1994 Jul;304:43-53.
11. Harryman DT 2nd, Mack LA, Wang KY, Jackins SE, Richardson ML, Matsen FA 3rd. Repairs of the rotator cuff. Correlation of functional results with integrity of the cuff. *J Bone Joint Surg Am.* 1991 Aug;73(7):982-9.
12. Nakagaki K, Tomita Y, Sakurai G, Oshiro O, Tamai S, Ozaki J. [Anatomical study on the atrophy of supraspinatus muscle belly with cuff tear]. *Nihon Seikeigeka Gakkai Zasshi.* 1994 Jul;68(7):516-21. Japanese.
13. Nho SJ, Brown BS, Lyman S, Adler RS, Altchek DW, MacGillivray JD. Prospective analysis of arthroscopic rotator cuff repair: prognostic factors affecting clinical and ultrasound outcome. *J Shoulder Elbow Surg.* 2009 Jan-Feb;18(1):13-20. Epub 2008 Sep 16.
14. Shen PH, Lien SB, Shen HC, Lee CH, Wu SS, Lin LC. Long-term functional outcomes after repair of rotator cuff tears correlated with atrophy of the supraspinatus muscles on magnetic resonance images. *J Shoulder Elbow Surg.* 2008 Jan-Feb;17(1 Suppl):1S-7S. Epub 2007 Nov 1.
15. Thomazeau H, Boukobza E, Morcet N, Chaperon J, Langlais F. Prediction of rotator cuff repair results by magnetic resonance imaging. *Clin Orthop Relat Res.* 1997 Nov;344:275-83.
16. Zanetti M, Gerber C, Hodler J. Quantitative assessment of the muscles of the rotator cuff with magnetic resonance imaging. *Invest Radiol.* 1998 Mar;33(3):163-70.
17. Nyffeler RW, Werner CM, Sukthar A, Schmid MR, Gerber C. Association of a large lateral extension of the acromion with rotator cuff tears. *J Bone Joint Surg Am.* 2006 Apr;88(4):800-5.
18. Zumstein MA, Jost B, Hempel J, Hodler J, Gerber C. The clinical and structural long-term results of open repair of massive tears of the rotator cuff. *J Bone Joint Surg Am.* 2008 Nov;90(11):2423-31.
19. Anderson K, Boothby M, Aschenbrener D, van Holsbeeck M. Outcome and structural integrity after arthroscopic rotator cuff repair using 2 rows of fixation: minimum 2-year follow-up. *Am J Sports Med.* 2006 Dec;34(12):1899-905. Epub 2006 Jul 26.
20. Cole BJ, McCarty LP 3rd, Kang RW, Alford W, Lewis PB, Hayden JK. Arthroscopic rotator cuff repair: prospective functional outcome and repair integrity at minimum 2-year follow-up. *J Shoulder Elbow Surg.* 2007 Sep-Oct;16(5):579-85. Epub 2007 Jul 12.
21. Flurin PH, Landreau P, Gregory T, Boileau P, Brassart N, Courage O, Dagher E, Graveleau N, Guillo S, Kempf JF, Lafosse L, Laprelle E, Toussaint B; et la Société Française d'Arthroscopie. [Arthroscopic repair of full-thickness cuff tears: a multicentric retrospective study of 576 cases with anatomical assessment.] *Rev Chir Orthop Reparatrice Appar Mot.* 2005 Dec;91(S8):31-42. French.
22. Outerbridge RE. The etiology of chondromalacia patellae. *J Bone Joint Surg Br.* 1961 Nov;43-B:752-7.
23. Richards RR, An KN, Bigliani LU, Friedman RJ, Gartsman GM, Gristina AG. A standardized method for the assessment of shoulder function. *J Shoulder Elbow Surg.* 1994 Nov;3(6):347-52.
24. Beaton DE, Wright JG, Katz JN; Upper Extremity Collaborative Group. Development of the QuickDASH: comparison of three item-reduction approaches. *J Bone Joint Surg Am.* 2005 May;87(5):1038-46.
25. Ware JE, Kosinski M, Keller SD. SF-12: how to score the SF-12 Physical and Mental Health Summary Scales. 2nd ed. Boston, MA: The Health Institute, New England Medical Center; 1995.
26. Kocher MS, Horan MP, Briggs KK, Richardson TR, O'Holleran J, Hawkins RJ. Reliability, validity, and responsiveness of the American Shoulder and Elbow Surgeons subjective shoulder scale in patients with shoulder instability, rotator cuff disease, and glenohumeral arthritis. *J Bone Joint Surg Am.* 2005 Sep;87(9):2006-11.
27. Millett PJ, Horan MP, Maland KE, Hawkins RJ. Long-term survivorship and outcomes after surgical repair of full-thickness rotator cuff tears. *J Shoulder Elbow Surg.* 2011 Jun;20(4):591-7. Epub 2011 Mar 12.
28. Landis JR, Koch GG. The measurement of observer agreement for categorical data. *Biometrics.* 1977 Mar;33(1):159-74.
29. Vaishnav S, Millett PJ. Arthroscopic rotator cuff repair: scientific rationale, surgical technique, and early clinical and functional results of a knotless self-reinforcing double-row rotator cuff repair system. *J Shoulder Elbow Surg.* 2010 Mar;19(2 Suppl):83-90.
30. Naqvi GA, Jadaan M, Harrington P. Accuracy of ultrasonography and magnetic resonance imaging for detection of full thickness rotator cuff tears. *Int J Shoulder Surg.* 2009 Oct;3(4):94-7.
31. Lee KW, Lee SH, Jung SH, Kim HY, Ahn JH, Kim KJ, Choy WS. The effect of the acromion shape on rotator cuff tears. *J Korean Orthop Assoc.* 2008 Apr;43(2):181-6.
32. Miyazaki AN, Fregoneze M, Santos PD, da Silva LA, Martel EM, Debom LG, Andrade ML, Checchia SL. Radiographic analysis of the acromion index and its association with rotator cuff tears. *Rev Bras Ortop.* 2010;45(2):151-4.
33. Sukthar A, Werner CM, Brucker P, Nyffeler RW, Gerber C. Lateral extension of the acromion and rotator cuff tears—a prospective study. *J Bone Joint Surg Br.* 2009;91-B(Suppl 1):123.
34. Baechler MF, Kim DH. "Uncoverage" of the humeral head by the anterolateral acromion and its relationship to full-thickness rotator cuff tears. *Mil Med.* 2006 Oct;171(10):1035-8.
35. Kircher J, Morhard M, Gavriilidis I, Magosch P, Lichtenberg S, Habermeyer P. Is there an association between a low acromion index and osteoarthritis of the shoulder? *Int Orthop.* 2010 Oct;34(7):1005-10. Epub 2009 Nov 6.
36. Kappe T, Cakir B, Lippacher S, Reichel H, Elsharkawi M. Intraarticular lesions in calcifying tendinitis: incidence and association with the acromion index. *Arch Orthop Trauma Surg.* 2011 Mar;131(3):325-9. Epub 2011 Jan 20.
37. Middernacht B, Winnock de Grave P, Van Maele G, Favard L, Molé D, De Wilde L. What do standard radiography and clinical examination tell about the shoulder with cuff tear arthropathy? *J Orthop Surg Res.* 2011 Jan 5;6:1.
38. Miyazaki AN, Itoi E, Sano H, Fregoneze M, Santos PD, da Silva LA, Sella Gdo V, Martel EM, Debom LG, Andrade ML, Checchia SL. Comparison between the acromion index and rotator cuff tears in the Brazilian and Japanese populations. *J Shoulder Elbow Surg.* 2011 Oct;20(7):1082-6. Epub 2011 Aug 4.
39. Torrens C, López JM, Puente I, Cáceres E. The influence of the acromial coverage index in rotator cuff tears. *J Shoulder Elbow Surg.* 2007 May-Jun;16(3):347-51. Epub 2006 Nov 16.
40. Rozing PM, Obermann WR. Osteometry of the glenohumeral joint. *J Shoulder Elbow Surg.* 1999 Sep-Oct;8(5):438-42.
41. Sallay PI, Reed L. The measurement of normative American Shoulder and Elbow Surgeons scores. *J Shoulder Elbow Surg.* 2003 Nov-Dec;12(6):622-7.
42. Hunsaker FG, Cioffi DA, Amadio PC, Wright JG, Caughlin B. The American Academy of Orthopaedic Surgeons outcomes instruments: normative values from the general population. *J Bone Joint Surg Am.* 2002 Feb;84-A(2):208-15.