

## Technical Note

# The Comprehensive Arthroscopic Management Procedure for Treatment of Glenohumeral Osteoarthritis

William R. Mook, M.D., Maximilian Petri, M.D., Joshua A. Greenspoon, B.Sc., and Peter J. Millett, M.D., M.Sc.

**Abstract:** Younger, high-demand patients who are less suitable for joint replacement procedures are often affected by advanced glenohumeral osteoarthritis. There are several alternatives to total joint arthroplasty for the treatment of these patients. However, the outcomes of these procedures are less predictable and have limited durability. The comprehensive arthroscopic management procedure, which includes a combination of arthroscopic glenohumeral debridement, chondroplasty, synovectomy, loose body removal, humeral osteoplasty with excision of the goat's beard osteophyte, capsular releases, subacromial and subcoracoid decompressions, axillary nerve decompression, and biceps tenodesis, has been shown to reduce pain, improve function, and provide a predictable short-term joint-preserving option for patients with advanced glenohumeral osteoarthritis. A unique feature of the comprehensive arthroscopic management procedure is the indirect and direct decompression of the axillary nerve, which may explain the difference in outcomes with this technique compared with other approaches. Furthermore, the technique is technically demanding and associated with several notable pitfalls that are preventable when using the meticulous surgical technique detailed in this article and accompanying video.

**T**otal shoulder arthroplasty (TSA) offers a predictable solution for many patients who have end-stage glenohumeral arthrosis. However, the outcomes of TSA have been reported to be less favorable in younger patients because of higher activity demands, heightened expectations, concerns for implant longevity, and the potential need for multiple revision operations over the course of the patients' lifetimes.<sup>1,2</sup> As a result, arthroscopic techniques have evolved in an attempt to postpone the need for joint replacement by improving pain and function.<sup>3-10</sup> We have described a comprehensive arthroscopic management (CAM)

technique that addresses the known pain generators in the shoulder. The CAM technique includes arthroscopic glenohumeral debridement, chondroplasty, synovectomy, loose body removal, inferior humeral osteoplasty, axillary nerve neurolysis, and capsular releases when indicated ([Video 1](#)). In addition, subacromial and/or subcoracoid decompression and biceps tenodesis are performed. The purpose of this report is to provide a detailed description of the technical aspects of our method.

## Surgical Technique

### Setup

An interscalene block is placed before surgery to help with analgesia immediately postoperatively and during the initial rehabilitation process. The patient receives anesthesia with a general anesthetic and is placed in a beach-chair positioner (Tenet T-Max Beach Chair and Spider arm positioner; Smith & Nephew, Memphis, TN) because this position facilitates manipulation of the arm, as well as access to the inferior capsular regions, when compared with the lateral position. The surgeon performs examination of both shoulders with the patient under anesthesia, taking special note of the patient's preoperative range of motion. Range-of-motion

*From The Steadman Clinic (W.R.M., M.P., P.J.M.) and Steadman Philippon Research Institute (M.P., J.A.G., P.J.M.), Vail, Colorado, U.S.A.*

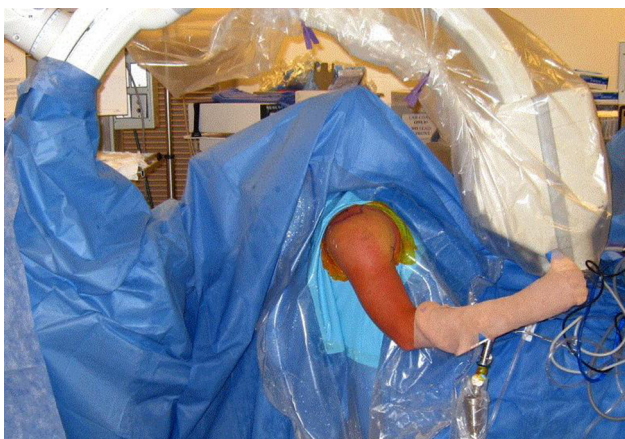*The authors report the following potential conflict of interest or source of funding: Steadman Philippon Research Institute receives corporate support from Smith & Nephew, Ossur, Siemens, and Arthrex. P.J.M. receives support from Arthrex, Myos, GameReady, and VuMedi.*

*Received January 22, 2015; accepted April 9, 2015.*

*Address correspondence to Peter J. Millett, M.D., M.Sc., Center for Outcomes-Based Orthopaedic Research, Steadman Philippon Research Institute, 181 W Meadow Dr, Ste 1000, Vail, CO 81657, U.S.A. E-mail: [drmillett@thesteadmanclinic.com](mailto:drmillett@thesteadmanclinic.com)*

© 2015 by the Arthroscopy Association of North America  
2212-6287/1570/\$36.00

<http://dx.doi.org/10.1016/j.eats.2015.04.003>



**Fig 1.** A fluoroscopic C-arm is draped into the surgical field. Fluoroscopic images should be taken to ensure that the full extent of the inferior humeral osteophyte can be visualized with internal and external rotation of the arm.

deficits due to capsular contracture are noted to assist with planning of subsequent capsulotomies. A deficit of more than  $15^\circ$  in any plane is consistent with capsular contracture. In our experience, the loss of abduction seems to correlate with the size of the inferior goat's beard osteophyte and removal of the osteophyte can improve range of motion. A fluoroscopic C-arm is then positioned to allow for fluoroscopic examination of the glenohumeral joint (Fig 1). Fluoroscopic images are obtained to ensure that the full extent of the inferior humeral osteophyte can be visualized with internal and external rotation of the arm. Standard preparation and draping to include the C-arm in the field are then performed.

A standard arthroscopic posterior viewing portal is placed approximately 2 cm medial and 2 cm inferior to the posterolateral corner of the acromion, followed by an anterosuperior working portal. A low-profile 5-mm  $\times$  7-cm cannula (Arthrex, Naples, FL) is inserted through the rotator interval to facilitate instrumentation. A standard  $30^\circ$  arthroscope is introduced, and a diagnostic arthroscopy is performed. Entry into the subacromial space is avoided until the decision to perform inferior humeral osteoplasty, capsular release, and axillary nerve neurolysis is made. This is done to avoid excessive extra-articular fluid extravasation that can make the safe completion of these procedures within the inferior capsular recess more difficult.

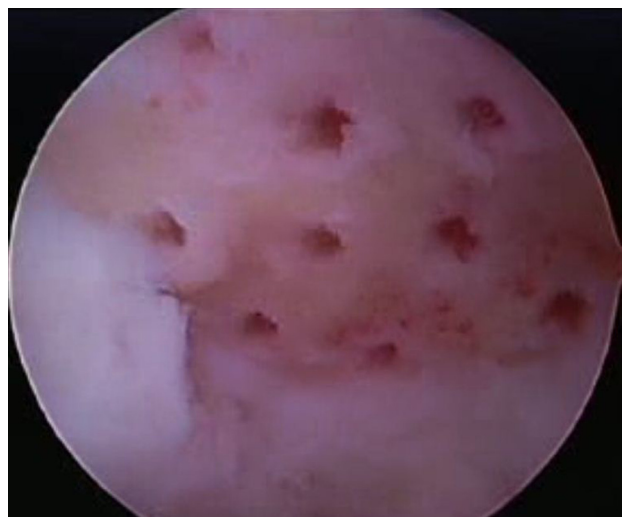
#### **Glenohumeral Debridement, Chondroplasty, Microfracture, Loose Body Removal, and Synovectomy**

When encountered, chondral loose bodies are removed with an arthroscopic grasper or morselized and suctioned from the joint with a mechanical shaver. Unstable chondral margins and degenerative

fraying of the labrum are carefully stabilized with a mechanical shaver. A 3.75-mm suction radio-frequency (RF) cautery device (Super TurboVac 90; ArthroCare, Austin, TX) is used to debride synovial hypertrophy and synovitis and to release adhesions within the rotator interval. When appreciated, well-shouldered isolated Outerbridge grade IV chondral lesions are treated with microfracture.<sup>7</sup> The calcified cartilage layer is debrided with a curette, and then, the underlying bone is perforated with microfracture picks (Arthrex) close enough to one another so that the subchondral plate between each hole is maintained at a depth of 2 to 4 mm (Fig 2). After perforation, inflow is temporarily stopped to ensure that the holes are deep enough to allow the egress of marrow, fat droplets, and blood. Then, the long head of the biceps tendon is examined by drawing it into the joint with an arthroscopic probe. If degeneration, pulley injury, hourglass deformity, or a degenerative SLAP injury is appreciated, then, tenotomy is performed about the origin with the RF device for later open subpectoral biceps tenodesis.

#### **Humeral Osteoplasty**

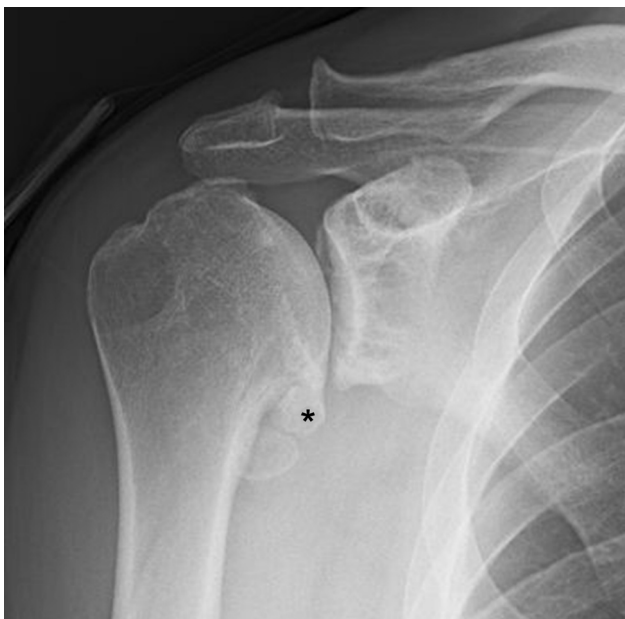If a large inferior humeral osteophyte (goat's beard deformity) is identified radiographically (Fig 3) or the patient has pain in the posterior or lateral shoulder corresponding to the axillary nerve distribution, humeral osteoplasty, inferior capsulotomy, and axillary nerve neurolysis are performed. An accessory posteroinferolateral or 7-o'clock portal is created approximately 5 cm inferior to the posterolateral aspect of the



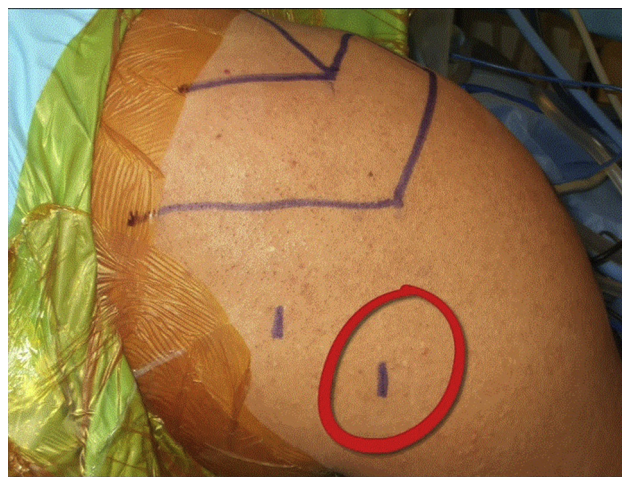
**Fig 2.** View of the posterior glenoid after microfracture has been performed in a left shoulder through the posterior viewing portal. The Powerpick (Arthrex) can be used when harder subchondral bone is encountered. In women and older adults, manual placement of the perforations is easily achieved with Chondro Picks (Arthrex).

acromion to facilitate access to the inferior axillary capsular recess (Fig 4). This portal is created after localization with an 18-gauge spinal needle approximately at the junction of the medial and central thirds of the inferior capsule, just anterior to the posterior band of the inferior glenohumeral ligament. A superficial skin incision is made, and a 2.6-mm switching stick is then used to bluntly re-create the path of the spinal needle to avoid iatrogenic injury to the axillary nerve. Once the trajectory of the path is established bluntly, dilators are used to allow access with an 8.25-mm Gemini Cannula (Arthrex), which has deployable wings to prevent back-out.

By use of the 7-o'clock portal, the inferior osteophyte is examined and resected with a shielded burr. The inferior capsular tissue is preserved during osteophyte resection to protect the axillary nerve from injury from the arthroscopic instruments and bony debris, as well as to prevent excessive fluid extravasation. The arm is periodically internally and externally rotated and examined fluoroscopically to help guide the resection (Fig 5A). Curved curettes can be used to help with osteophyte removal and are particularly useful in removing hypertrophic bone from the anteroinferior areas that are more difficult to access with motorized instruments. The goal is to remove enough bone so that the axillary nerve is decompressed throughout the range of motion of the shoulder, as well as to restore full mobility (Fig 5B). The final resection is smoothed with a rasp.



**Fig 3.** A large humeral inferior osteophyte (goat's beard osteophyte) (asterisk) can be visualized on the radiograph. Live fluoroscopy with dynamic examination of the arm with internal and external rotation is an excellent adjunct to direct arthroscopic visualization of the axillary capsular recess to ensure that the osteophyte is completely resected.

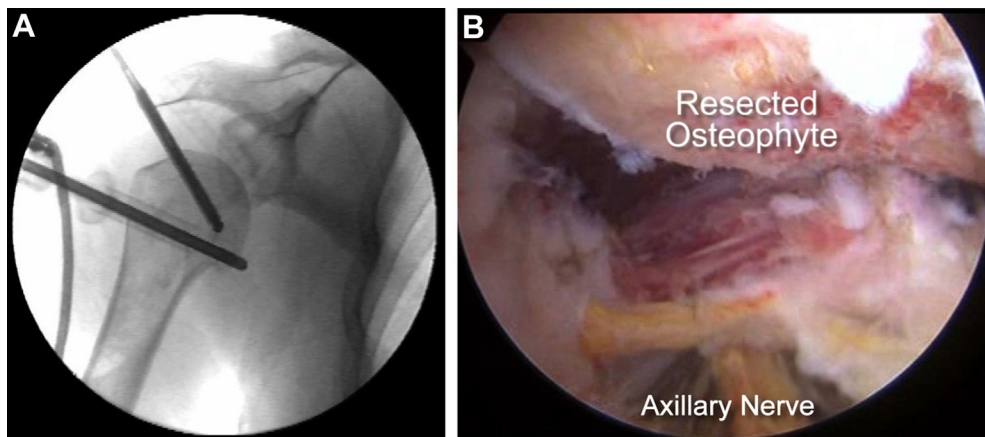


**Fig 4.** An accessory posteroinferolateral or 7-o'clock portal (circle) is created to facilitate access to the inferior axillary capsular recess. Precise placement of this portal is achieved under direct visualization by localizing the junction of the medial and central thirds of the inferior capsule just anterior to the posterior band of the inferior glenohumeral ligament with an 18-gauge spinal needle. Localization of its position under direct visualization and maintaining its placement with a Gemini Cannula is critical to avoid iatrogenic nerve injury.

### Capsular Releases and Axillary Nerve Neurolysis

The extent of the capsular releases is determined by preoperative evaluation of the patient's motion and the need to access the axillary nerve for neurolysis. After completion of the humeral osteoplasty, the inferior capsule is divided. The capsulotomy is started posteriorly near the cannula insertion site with a monopolar hook-tip RF device (CoolCut; Arthrex) or arthroscopic scissors under direct visualization (Fig 6). Both 30° and 70° arthroscopes can be used to facilitate visualization. The surgeon then performs neurolysis, releasing the axillary nerve from proximal, as it courses inferiorly to the subscapularis tendon, to distal, as it courses between the teres minor and major tendons (Fig 7). The neurolysis is performed bluntly under direct visualization with a probe and arthroscopic punches, moving along the axillary nerve's course from proximal to distal to prevent iatrogenic injury as it arborizes. The neurolysis is complete when the nerve is visualized to be free of surrounding soft-tissue adhesions and bony impingement.

Anterior and posterior capsulotomies are performed as indicated. After debridement of scar and synovitis within the rotator interval, the anterior capsule is divided from the rotator interval to the 5-o'clock position with an RF probe just lateral to the labrum. The muscle fibers of the subscapularis can be visualized, and it is important to work carefully to avoid damage to the subscapularis. If necessary, the arthroscope is



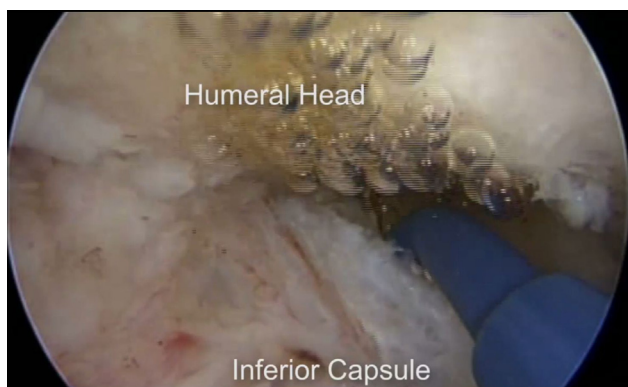
**Fig 5.** (A) Fluoroscopic guidance is used during osteophyte resection to guide resection of the inferior humeral osteophyte. The inferior capsule should be preserved during resection to protect the axillary nerve from injury. To facilitate resection, the arm should be periodically internally and externally rotated. Curved curettes can be used to remove bone from anteroinferior areas that are difficult to access with motorized instruments. (B) View of the resected osteophyte through the posterior portal in a right shoulder. The proximity of the axillary nerve to the resected osteophyte should be noted.

repositioned in the anterosuperior portal and posterior capsular release is performed from the 7- to 11-o'clock position in a similar fashion (Fig 8). The arm is then re-examined and gently manipulated to show restoration of passive motion.

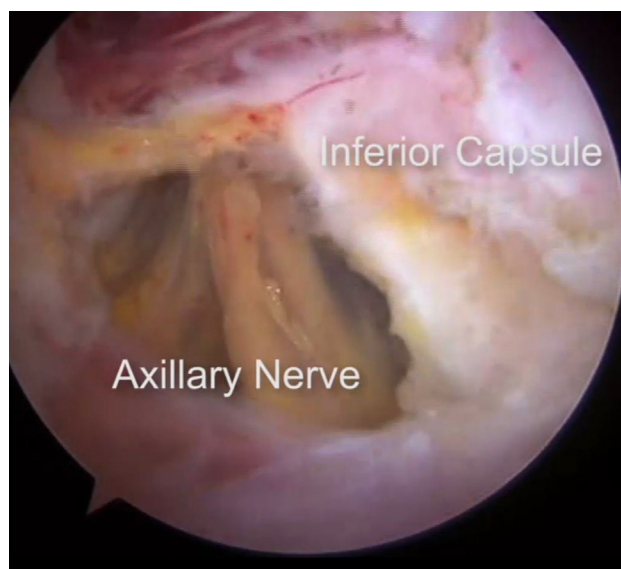
#### Additional Procedures

Subacromial decompression, subcoracoid decompression, and biceps tenodesis are performed selectively based on the patient's pathoanatomy. The coracohumeral interval is examined. If the interval is less than 8 mm in female patients or less than 10 mm in male patients, coracoplasty is performed to re-establish

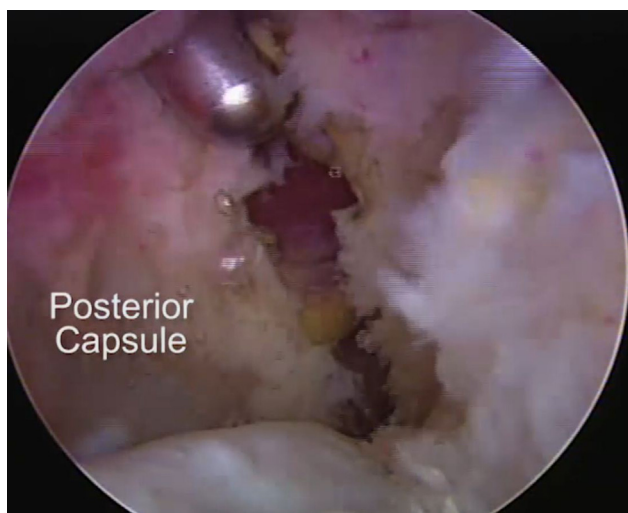
the dimensions of the interval by anteriorizing, medializing, and superiorizing the margins of the coracoid with an arthroscopic burr. The arthroscope is then inserted into the subacromial space through the posterior portal, and a liberal subacromial bursectomy is performed. Acromioplasty is performed with a modified



**Fig 6.** View through the posterior portal with instrumentation in the 7-o'clock portal in a right shoulder. An inferior capsular release is performed, the extent of which is determined by preoperative evaluation of the patient's motion and the need to access the axillary nerve for neurolysis. The release should be started posteriorly near the cannula insertion site.



**Fig 7.** The inferior capsule and axillary nerve are visualized through the posterior portal in a left shoulder. Axillary nerve neurolysis should be performed bluntly under direct visualization with a probe and arthroscopic punches. It should be performed from proximal to distal to prevent iatrogenic injury. The neurolysis is considered complete when the nerve is visualized to be free of surrounding soft-tissue adhesions and bony impingement.



**Fig 8.** Posterior capsular release, viewed through the anterior portal with instrumentation in the posterior portal in a right shoulder. After the release has been performed, the arm is re-examined and gently manipulated to show restoration of passive motion.

cutting block technique if a type III acromion or impingement lesion is identified. If pathology of the long head of the biceps was identified during intra-articular debridement and it was tenotomized, the procedure is concluded with an open subpectoral biceps tenodesis. Our preferred technique is to place a small cosmetic incision in the axillary fold (Fig 9A), identify

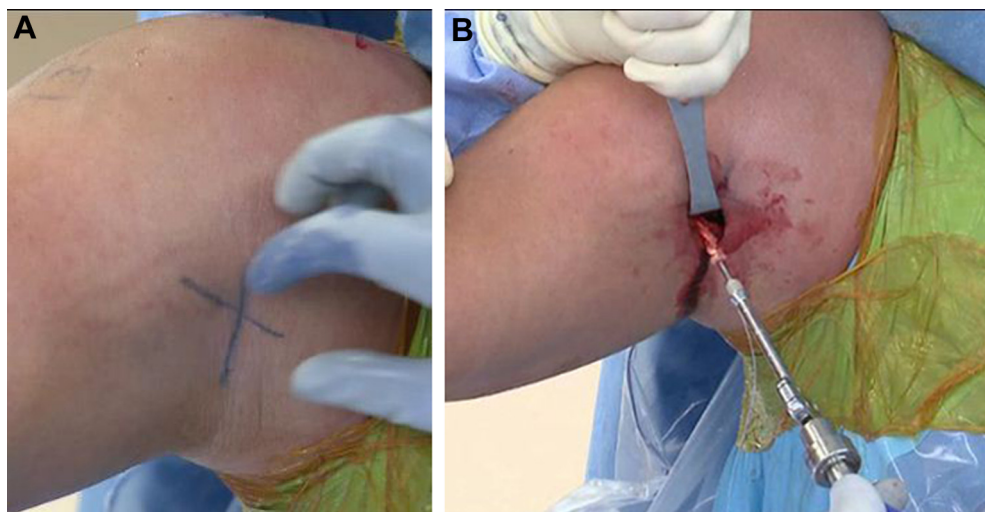
and deliver the tendon from the interval between the pectoralis major and conjoint tendons, and fix the tendon in a 7- or 8-mm unicortical socket with a PEEK (polyether ether ketone) tenodesis screw (Arthrex) (Fig 9B).

### Postoperative Care

The rehabilitation program is initiated immediately postoperatively and is facilitated in most cases by the preoperative placement of a regional block for pain control. The goals of rehabilitation are to improve and maintain motion, prevent recurrent scarring and contracture, and improve glenohumeral and scapulothoracic mechanics. The first of 3 phases emphasizes passive and active-assisted motion. The second phase, focusing on strengthening, ensues around 4 to 6 weeks. The final phase, focusing on functional return to activities, is initiated at approximately 3 months. Maximal recovery can be expected by 4 to 6 months.

### Discussion

Arthroscopic management of the pain generators of the shoulder in young, active patients with advanced glenohumeral osteoarthritis has been shown to reduce pain, improve function, and in many patients, delay the need for joint replacement (Table 1).<sup>3-6,8-10</sup> Careful patient selection is important for successful outcomes. A Markov decision analysis has shown that arthroscopic management may be better suited for patients younger than 47 years and TSA may be



**Fig 9.** (A) The incision for the subpectoral biceps tenodesis is made in the axillary fold distal to the inferior margin of the pectoralis major tendon. The plane between the conjoint and pectoralis tendons is then developed. (B) The previously tenotomized biceps tendon is retrieved. It is whipstitched with a No. 2 FiberWire (Arthrex) from the musculotendinous junction, extending approximately 3 cm proximally. A 7-mm unicortical socket is created in women, whereas an 8-mm unicortical socket is created in men. The biceps tendon is loaded onto a PEEK tenodesis screw for interference fixation.

**Table 1.** Summary of Outcomes After Arthroscopic Management of Glenohumeral Osteoarthritis

Authors	Year	Shoulders, n	Age, yr	Technique	Revisions and Complications	Change in Status
Millett et al. <sup>6</sup>	2013	30	Mean, 52	Debridement with or without capsular releases, humeral osteoplasty, axillary neurolysis, and acromioplasty	Arthroplasty (n = 6) at mean of 1.9 yr	ASES score, 25 SF-12 PCS score, 6.6 FE, 54.7° ER, 48.8° ER at 90°, 48.1° IR, 37°
Van Thiel et al. <sup>9</sup>	2010	81	Mean, 47	Debridement with or without capsular releases, tenotomy, microfracture, and acromioplasty	Arthroplasty (n = 16) at mean of 10.1 mo	ASES score, 20.9 SST score, 2.9 VAS score, 2.1
De Beer et al. <sup>4</sup>	2010	31	Median, 57.5	Debridement, glenoid resurfacing, and tenotomy	Axillary paresis (n = 1) Material failure (n = 2) Synovitis (n = 1) Contusion from MUA (n = 1)	Median Constant-Murley score, 24.5
Kerr and McCarty <sup>5</sup>	2008	20	Mean, 38	Debridement with or without tenotomy and microfracture	NR	ASES score,* 75.3 SANE score,* 63%
Richards and Burkhart <sup>8</sup>	2007	8	Mean, 55	Debridement with or without capsular releases	NR	FE, 21.4° IR, 31.1° ER, 16.7°
Cameron et al. <sup>3</sup>	2002	70	Mean, 50	Debridement with or without capsular releases	NR	Functional score (0-60), 14.7 FE, 38°
Weinstein et al. <sup>10</sup>	2000	25	Mean, 46	Debridement	None	Pain improved

ASES, American Shoulder and Elbow Surgeons; ER, external rotation; FE, forward elevation; IR, internal rotation; MUA, manipulation under anesthesia; NR, not reported; SANE, Single Assessment Numeric Evaluation; SF-12 PCS, Short Form 12 Physical Component Summary; SST, Simple Shoulder Test; VAS, visual analog scale.

\*Postoperative scores only.

preferred in patients older than 66 years. However, between 47 and 66 years of age, a clear advantage to one technique over the other is not evident.<sup>11</sup> Management decisions in these borderline scenarios must strongly consider the patient expectations, physiological age, and activity demands. The outcomes may be less predictable and durable if there is less than 2 mm of glenohumeral joint space present on preoperative imaging or if limitations of range of motion, especially internal rotation, are minimal.<sup>7</sup> In addition, a recently presented study identified that patients with a low critical shoulder angle, Kellgren-Lawrence grade III or IV arthritis, and Walch type B2 or C glenoid were more likely to fail the CAM procedure and progress to

a TSA.<sup>12</sup> Other authors have also shown that large osteophytes and bipolar chondral lesions are predictive of inferior outcomes with arthroscopic techniques.<sup>9,10</sup>

A unique feature of the CAM procedure is the indirect and direct decompression of the axillary nerve. This may explain the difference in outcomes with this technique compared with other approaches,<sup>13,14</sup> as well as findings that have shown that large osteophytes were associated with inferior outcomes.<sup>10</sup> Furthermore, the technique is technically demanding and associated with several notable pitfalls that are preventable with meticulous surgical technique (Table 2).

**Table 2.** Summary of Surgical Risks and Technical Pearls

Surgical Risks	Technical Pearls
Iatrogenic axillary nerve damage	Work from medial to lateral and proximal to distal while decompressing the axillary nerve. Use a blunt trocar to separate the axillary nerve from scar tissue and capsule. A cannula can be used to shield the neurovascular structures.
Fluid extravasation into axillary space	Perform capsular releases after inferior humeral osteoplasty and axillary nerve neurolysis. Use moderate arthroscopic pump pressures.
Incomplete humeral osteoplasty	Use fluoroscopy and both 30° and 70° arthroscopes to assist visualization; use long curettes to remove bone. There are, however, some cases in which a complete excision may not be safe or possible.

## References

1. Cheung EV, Sperling JW, Cofield RH. Revision shoulder arthroplasty for glenoid component loosening. *J Shoulder Elbow Surg* 2008;17:371-375.
2. Deutsch A, Abboud JA, Kelly J, et al. Clinical results of revision shoulder arthroplasty for glenoid component loosening. *J Shoulder Elbow Surg* 2007;16:706-716.
3. Cameron BD, Galatz LM, Ramsey ML, Williams GR, Iannotti JP. Non-prosthetic management of grade IV osteochondral lesions of the glenohumeral joint. *J Shoulder Elbow Surg* 2002;11:25-32.
4. de Beer JF, Bhatia DN, van Rooyen KS, Du Toit DF. Arthroscopic debridement and biological resurfacing of the glenoid in glenohumeral arthritis. *Knee Surg Sports Traumatol Arthrosc* 2010;18:1767-1773.
5. Kerr BJ, McCarty EC. Outcome of arthroscopic debridement is worse for patients with glenohumeral arthritis of both sides of the joint. *Clin Orthop Relat Res* 2008;466:634-638.
6. Millett PJ, Horan MP, Pennock AT, Rios D. Comprehensive arthroscopic management (CAM) procedure: Clinical results of a joint-preserving arthroscopic treatment for young, active patients with advanced shoulder osteoarthritis. *Arthroscopy* 2013;29:440-448.
7. Millett PJ, Huffard BH, Horan MP, Hawkins RJ, Steadman JR. Outcomes of full-thickness articular cartilage injuries of the shoulder treated with microfracture. *Arthroscopy* 2009;25:856-863.
8. Richards DP, Burkhart SS. Arthroscopic debridement and capsular release for glenohumeral osteoarthritis. *Arthroscopy* 2007;23:1019-1022.
9. Van Thiel GS, Sheehan S, Frank RM, et al. Retrospective analysis of arthroscopic management of glenohumeral degenerative disease. *Arthroscopy* 2010;26:1451-1455.
10. Weinstein DM, Bucchieri JS, Pollock RG, Flatow EL, Bigliani LU. Arthroscopic debridement of the shoulder for osteoarthritis. *Arthroscopy* 2000;16:471-476.
11. Spiegl UJ, Faucett SC, Horan MP, Warth RJ, Millett PJ. The role of arthroscopy in the management of glenohumeral osteoarthritis: A Markov decision model. *Arthroscopy* 2014;30:1392-1399.
12. Warner BT, Horan MP, Raynor MB, Millett PJ. Arthroscopic management of glenohumeral osteoarthritis: Prospective evaluation of factors associated with success. Presented at the Arthroscopy Association of North America Annual Meeting, Los Angeles, CA, 2015.
13. Skelley NW, Namdari S, Chamberlain AM, Keener JD, Galatz LM, Yamaguchi K. Arthroscopic debridement and capsular release for the treatment of shoulder osteoarthritis. *Arthroscopy* 2015;31:494-500.
14. Namdari S, Skelley N, Keener JD, Galatz LM, Yamaguchi K. What is the role of arthroscopic debridement for glenohumeral arthritis? A critical examination of the literature. *Arthroscopy* 2013;29:1392-1398.