



ELSEVIER

# Clinical outcomes after autograft reconstruction for sternoclavicular joint instability

Maximilian Petri, MD<sup>a,b</sup>, Joshua A. Greenspoon, BSC<sup>a</sup>, Marilee P. Horan, MPH<sup>a</sup>, Frank Martetschläger, MD<sup>a,b,c,d</sup>, Ryan J. Warth, MD<sup>a</sup>, Peter J. Millett, MD, MSc<sup>a,b,\*</sup>

<sup>a</sup>The Steadman Philippon Research Institute, Vail, CO, USA

<sup>b</sup>The Steadman Clinic, Vail, CO, USA

<sup>c</sup>Department of Shoulder and Elbow Surgery, ATOS Clinic Munich, Munich, Germany

<sup>d</sup>Department of Orthopaedic Sports Medicine, Clinic rechts der Isar, Technical University Munich, Munich, Germany

**Background:** Instability of the sternoclavicular (SC) joint is a rare condition. However, in some cases, SC joint instability may lead to persistent pain and impairment of shoulder function that requires surgical management. This study evaluated clinical outcomes after SC joint reconstruction with hamstring tendon autograft in patients with SC joint instability.

**Methods:** From December 2010 to January 2014, 21 reconstructions of the SC joint with hamstring tendon autograft were performed. Outcomes data were prospectively collected and retrospectively reviewed. Data analyzed included American Shoulder and Elbow Surgeons score, Quick Disability of the Arm, Shoulder and Hand, physical component of the Short Form 12, and Single Assessment Numeric Evaluation scores. Pain with activities of daily living, work, and sleep were separately analyzed along with painless use of arm for activities. Patients were also questioned regarding postoperative satisfaction.

**Results:** Nine women and 10 men (2 bilaterals), with a mean age of 30 years (range, 15-56 years), were monitored for a mean of 2 years (range, 12-36 months) postoperatively. Mean American Shoulder and Elbow Surgeons, Quick Disability of the Arm, Shoulder and Hand, and Single Assessment Numeric Evaluation scores significantly improved ( $P < .001$ ). Pain scores also improved over preoperative baselines, including pain with activities of daily living, work, and sleep ( $P < .001$ ). Median satisfaction at final follow-up was 8.5 (range, 7-10). There were no intraoperative or postoperative complications and no cases of recurrent instability.

**Conclusion:** Free hamstring tendon autograft reconstruction for SC joint instability resulted in significantly improved clinical outcomes with high patient satisfaction and no intraoperative or postoperative complications.

**Level of evidence:** Level IV, Case Series, Treatment Study.

© 2015 Journal of Shoulder and Elbow Surgery Board of Trustees.

**Keywords:** Sternoclavicular joint; instability; autograft; reconstruction; SC

The Vail Valley Medical Center Institutional Review Board approved this study (protocol 2002-03).

\*Reprint requests: Peter J. Millett, MD, MSc, The Steadman Clinic, 181 West Meadow Drive, Suite 400, Vail, CO 81657, USA.

E-mail address: [drmillett@thesteadmanclinic.com](mailto:drmillett@thesteadmanclinic.com) (P.J. Millett).

Sternoclavicular (SC) joint stability relies on the presence of intact capsular, costoclavicular and interclavicular ligaments.<sup>6,7,17</sup> Direct or indirect high-energy trauma is most often responsible for disruption of SC joint-stabilizing structures, thereby resulting in anterior or

posterior dislocation or subluxation.<sup>7,9,20</sup> Injuries to the SC joint are rare and account for only 3% of all shoulder girdle injuries and 1% of all dislocations, making it one of the least commonly disrupted joints in the body.<sup>16,18,21</sup>

In contrast to anterior dislocations, posterior dislocations are less common and represent potentially life-threatening injuries.<sup>25,30</sup> Locked posterior dislocations require emergency surgical treatment due to potential for injury of the retrosternal structures such as major vessels, the trachea, esophagus and mediastinum. Most anterior dislocations are treated nonsurgically with minimal risk for long-term sequelae<sup>9</sup>; however, pain resulting from SC instability or post-traumatic osteoarthritis may lead to discomfort and limit functional activities.<sup>15,18,21,28</sup> Surgical treatment may therefore be necessary in patients with persistent, symptomatic SC joint instability despite appropriate nonsurgical measures.<sup>3,8,9</sup>

Numerous techniques are available for reconstruction of the SC joint, but many of these procedures are associated with high complication rates. A current gold standard for reconstruction of the SC joint does not exist.<sup>1,2,5,8,10,11,14,20-22,24,27</sup> Surgical treatment options require deep dissection of the SC joint, putting at risk the adjacent structures such as the trachea, the brachiocephalic vein, the brachiocephalic trunk, the subclavian artery, and the common carotid artery.<sup>4,19</sup> Therefore, an intimate knowledge of the surrounding anatomy and anatomic relationships is crucial before an SC joint reconstruction is performed to prevent potentially life-threatening complications from occurring.<sup>17</sup>

A biomechanical study conducted by Spencer and Kuhn<sup>26</sup> suggested that SC joint reconstruction using graft material oriented in a figure-of-eight fashion with 2 drill holes in the clavicle and 2 in the sternum was superior to other methods when comparing graft integrity, load to failure, and translation of the medial clavicle. However, in the case where a proximal clavicle excision has been done previously, establishing 2 drill tunnels in the clavicle may not be possible. In this setting, a single-looped reconstruction can be performed. The hypothesis of this study was that patients with persistent symptomatic SC joint instability reconstructed with a hamstring tendon autograft would demonstrate good clinical outcomes with high patient satisfaction and a low complication rate.

## Materials and methods

### Patient population

All patients who underwent SC joint reconstruction by the senior surgeon (P.J.M.) between December 2010 and January 2014 were assessed for eligibility. The primary indication for surgery was continued, painful SC joint instability that had failed nonoperative treatment consisting of rest, physical therapy, and activity modification. All patients were counseled regarding the inherent risks and potential complications related to the surgical procedure,

including death. Only patients with severe symptoms were considered eligible for surgery. The study excluded patients who underwent SC joint reconstruction with allografts or concomitant acromioclavicular joint reconstructions.

### Surgical technique

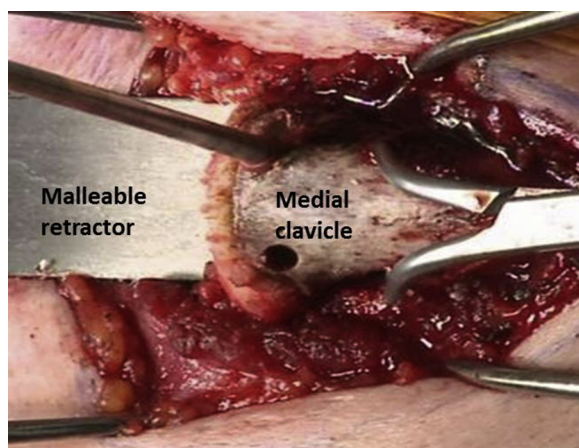
All patients were medically cleared before surgical intervention, and a thoracic surgeon was notified of the procedure. Preoperative planning included a computed tomography angiogram to determine the relationship to major mediastinal vessels. After the induction of general anesthesia, patients were placed supine in approximately 30° of reverse Trendelenburg. Examination under anesthesia confirmed the hypermobility of the medial clavicle on the injured side. A 6-cm to 8-cm incision was made in line with the center of the medial clavicle to ensure adequate exposure. The sternocleidomastoid muscle was elevated and preserved to allow for repair during closure.<sup>17</sup> Subperiosteal dissection exposed the most medial 8 to 10 cm of the clavicle. When the SC joint was arthritic, a medial clavicle excision of 8 to 10 mm was performed.<sup>17</sup> The retrosternal space was carefully dissected with a curved periosteal elevator so that a malleable retractor could be carefully placed beneath the medial clavicle and sternum before the bone tunnels were drilled.

The hamstring autograft was harvested using standard techniques. The harvested tendon was selected based on the desired graft diameter. The gracilis tendon was generally harvested if a figure-of-eight reconstruction was to be used. The semitendinosus was harvested if a single loop reconstruction was to be used in cases when there was insufficient bone stock to drill 2 tunnels in the medial clavicle. The autograft was then whipstitched at both ends with No. 2 FiberWire suture (Arthrex, Naples, FL, USA) and measured to determine the appropriate drill tunnel diameter (typically 3.5 or 4.5 mm).

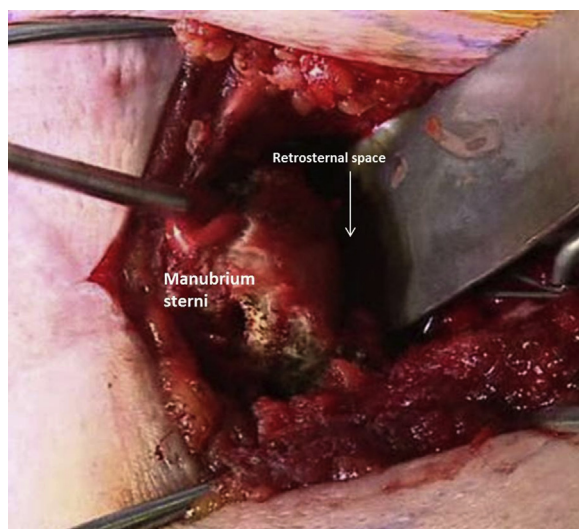
A figure-of-eight reconstruction was performed in most cases according to the technique suggested by Spencer and Kuhn.<sup>26</sup> Superior and inferior tunnels, spaced approximately 1.5 cm apart, were drilled in the medial clavicle at the level of the condylar flare (Fig. 1). Similarly, 2 tunnels were drilled in the sternum (Fig. 2). After the insertion of guide pins, the tunnels were drilled with a 3.5-mm or 4.5-mm cannulated drill according to the graft diameter and bone size. All drilling was performed with the malleable retractor beneath the sternum and clavicle to avoid injury to retrosternal structures and the subclavian vessels (Figs. 1 and 2). Passing sutures were placed in the bone tunnels, and the graft was shuttled through them in a figure-of-eight (Fig. 3). The 2 whipstitched free ends of the graft were knotted together (Fig. 4), and the construct was secured with No. 2 permanent sutures through the tendon knot (Fig. 5).

When there was insufficient bone stock to establish 2 drill tunnels in the medial clavicle, such as after medial clavicle excision, a single-looped reconstruction was performed, and a large semitendinosus graft was used.

In all cases performed since 2012, demineralized bone matrix was injected around the bone tunnels in an effort to enhance tendon incorporation and minimize tunnel widening. After the graft was secured, stability was tested by pulling and pushing on the clavicle and by placing the arm through a range of motion while directly visualizing the repair. The periosteum, joint



**Figure 1** Left sternoclavicular joint reconstruction: Exposure of the medial clavicle and drilling of the second tunnel over the guidewire. The retroclavicular space is protected by the malleable retractor.



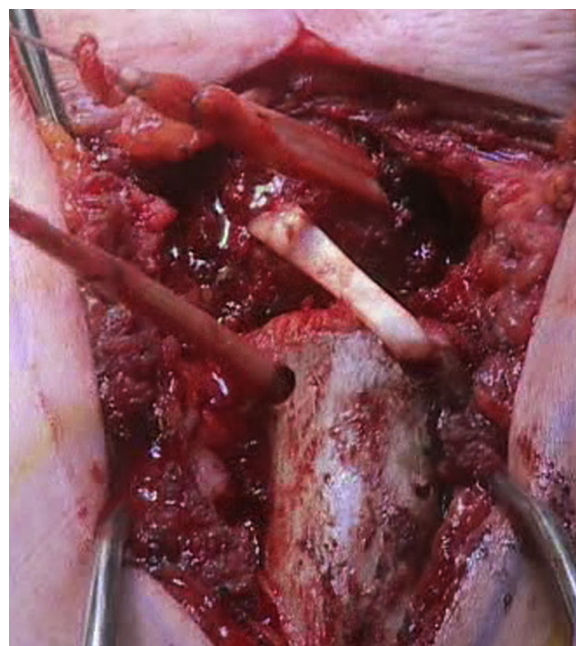
**Figure 2** Left sternoclavicular joint reconstruction: Exposure of the manubrium sterni and drilling of the second tunnel over the guidewire. The retrosternal space is protected by the malleable retractor.

capsule, and sternocleidomastoid insertion were meticulously repaired, and the skin was closed in a standard manner.

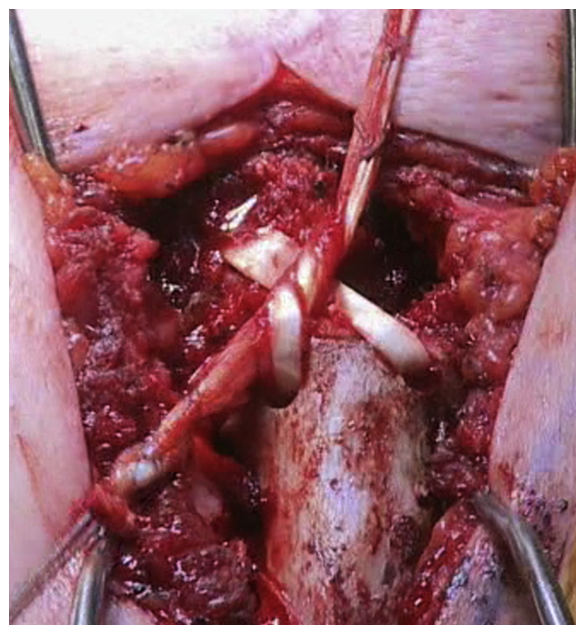
The shoulder was immobilized postoperatively in a sling for 6 weeks. Formal physical therapy was initiated during this time, beginning with pendulum and passive range of motion exercises. Protraction and retraction of the scapula were not permitted. Active-assisted range of motion exercises were begun at approximately 6 weeks, followed by strengthening at 8 weeks. Patients were typically allowed to return to full activity after 6 months.

### Data collection

All data were prospectively collected, stored in a registry, and retrospectively analyzed. These included demographic

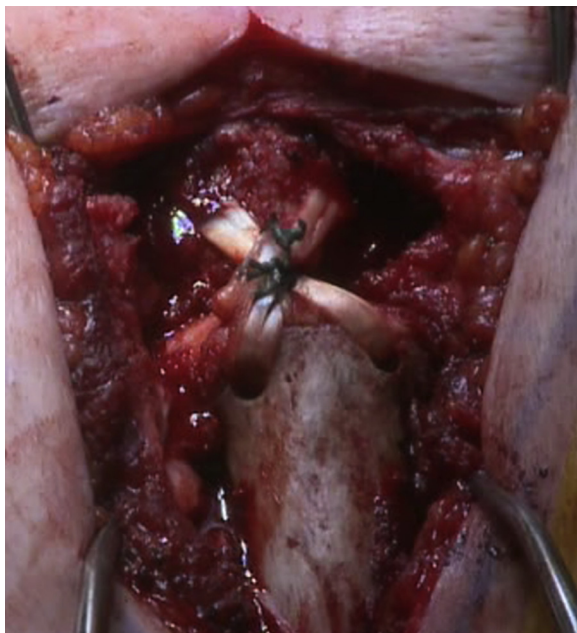


**Figure 3** Left sternoclavicular joint reconstruction: Passage of the gracilis tendon autograft in a figure-of-eight configuration. The posterior strands are parallel, while the anterior strands cross over.



**Figure 4** Left sternoclavicular joint reconstruction: The two whipstitched free ends of the graft are knotted together.

information (age, gender, dominant shoulder, affected shoulder), characteristics of injury (mechanism, duration of symptoms), prior surgeries, treatment history, additional pathologies, adjuvant treatments, and perioperative complications. Patient-centered outcomes scores were collected preoperatively and postoperatively and included the American Shoulder and Elbow Surgeons (ASES) score, the 11-item version of the Disabilities of the Arm, Shoulder and Hand (QuickDASH) score, the physical



**Figure 5** Left sternoclavicular joint reconstruction: View on the final reconstruction site after securing the tendon knot with No. 2 Ethibond (Ethicon, Somerville, NJ, USA) sutures and shortening the grafts ends.

component summary of the Short Form 12, and the Single Assessment Numeric Evaluation (SANE) score. The visual analog scale (VAS) was used to measure overall preoperative and postoperative pain on a scale of 0 to 10, where 0 indicated no pain and 10 indicated maximal pain. Pain with activities of daily living, work, and recreation was measured on a scale of 0 to 3, where 0 represented no pain and 3 represented maximal pain. At the final follow-up, patients were also asked questions regarding satisfaction with surgical outcomes (scale 1-10, 10 = very satisfied) and activity modification (yes or no).

## Statistical analysis

Statistical analysis was performed using SPSS 11.0 software (IBM Corp, Armonk, NY, USA). The paired Student *t* test was used to measure differences between preoperative and postoperative outcome measures. Univariate and nonparametric analyses were performed, where appropriate, depending on whether the involved outcomes data were normally distributed. For all statistical analyses, a resulting *P* value of  $<.05$  indicated a statistically significant difference between the measured variables.

## Results

The senior surgeon performed 24 SC joint reconstructions (2 bilateral) during the study period. Two patients were excluded due to concomitant acromioclavicular joint reconstructions, and 1 patient was excluded because the reconstruction was performed with an allograft. The remaining 21 SC reconstructions were included in this

study. The surgeries were performed in 9 women and 10 men (2 bilateral). The patient cohort was a mean age of 30 years (range, 15-56 years). Acute trauma resulted in 17 of 21 injuries (81%). Gracilis autograft was used in 18 of 21 patients (86%) and semitendinosus autograft was used in 3 (14%). A figure-of-eight reconstruction was performed in 18 of 21 patients (86%), and a single loop reconstruction was performed in 3 (14%). Demineralized bone matrix was used in 12 of 21 patients (57%).

Importantly, there were no perioperative complications related to the reconstruction technique or graft harvesting. One patient underwent a subsequent exploratory surgery of the SC joint due to sudden onset of joint pain after lifting a heavy weight. The SC joint was stable and the reconstruction was intact. The patient's pain subsequently diminished with physical therapy. The SC joint remained reduced postoperatively in all patients.

Mean 2-year follow up data (range, 1-3 years) were available for 18 of 21 patients (86%). The mean ASES scores significantly improved from 51.9 preoperatively to 82.5 postoperatively ( $P < .001$ ). Significant improvements in QuickDASH scores and SANE scores were also found ( $P < .001$ ; Table I). Overall pain significantly improved over the preoperative baseline, including pain with activities of daily living, work and sleep ( $P < .02$ ). Median satisfaction at final follow-up was 8.5 (range, 7-10).

Four patients reported a 7 of 10 satisfaction with their outcome. These patients also reported significantly greater postoperative pain on the VAS (4 vs 1;  $P = .003$ ), significantly lower ASES scores (71.6 vs 85.6;  $P = .032$ ), and significantly lower Short Form 12 physical component summary scores (38.6 vs 49.1;  $P = .035$ ) compared with those patients who reported a satisfaction score of 8 or higher. These 4 patients had preoperative concomitant injuries, comprising 1 cervical spine fracture, 1 clavicle fracture, and 2 superior labrum anteroposterior tears, that might have affected their pain or outcomes scores postoperatively.

## Discussion

The most important finding of this study was that reconstruction of the SC joint with a hamstring autograft yielded high patient satisfaction rates and significant improvements in clinical outcomes scores over the preoperative baseline. As evident by the absence of perioperative complications in this cohort, this surgical procedure may be performed safely in selected patients when appropriate, meticulous technique is used.

Several reconstructive techniques for the SC joint have been evaluated, with most studies reporting significant complications and inconsistent outcomes.<sup>2,4,12,22,23</sup> The applicability of their results is furthermore compromised by low patient numbers and heterogeneous cohorts of both SC joint resection arthroplasties and reconstructions.<sup>3,21,22</sup>

**Table I** Summary of reported outcomes\*

Outcomes	Preoperative	Postoperative	P value
ASES (0-100, 100 = best)	51.9 (27-80)	82.5 (57-98)	<0.001
SANE (0-100, 100 = best)	45.0 (10-89)	81.3 (60-99)	<0.001
QuickDASH (0-100, 0 = best)	46.1 (27-80)	16.0 (0-34)	<0.001
SF-12 PCS	38.9 (29-52)	46.7 (32-63)	.97
Satisfaction†	–	8.5 (7-10)	–

ASES, American Shoulder and Elbow Surgeons; QuickDASH, 11-item version of the Disabilities of Arm, Shoulder and Hand Outcome Measure; SANE, Single Assessment Numeric Evaluation; SF-12 PCS, Short Form 12 Physical Component Score.

\* Data are presented as means (range) unless otherwise noted.

† Satisfaction data are presented as the median (range); scale: 1 = unsatisfied; 10 = completely satisfied.

Rockwood et al<sup>22</sup> reported excellent outcomes in only 3 of 7 patients (43%) after intramedullary reconstruction of the costoclavicular ligament after failed SC joint resection arthroplasty at an average of 7.7 years postoperatively. The importance of the costoclavicular ligament for SC joint stability was recently confirmed by a qualitative and quantitative study investigating the surgical anatomy of the SC joint.<sup>17</sup> The study confirmed the need to leave the costoclavicular ligament intact during resection arthroplasty by not resecting more than 10 mm of the proximal clavicle.<sup>17</sup> The surgical technique used in this study strictly followed this recommendation, preserving the costoclavicular ligament by a subperiosteal dissection and subsequent repair, which may have contributed to the good overall clinical results.

Spencer and Kuhn<sup>26</sup> biomechanically determined anteroposterior load to failure after SC joint reconstruction using 3 different techniques—intramedullary ligament reconstruction, subclavius tendon reconstruction, and semitendinosus figure-of-eight reconstruction—in a cadaveric study. The load to failure for the semitendinosus figure-of-eight reconstruction was nearly 3-times higher than that of the other 2 reconstruction techniques. This study popularized the concept of a figure-of-eight reconstruction to provide anterior and posterior stabilization of the joint.

Bae et al<sup>3</sup> evaluated the outcomes after SC joint resection or figure-of-eight hamstring autograft reconstruction for SC joint instability in a series of 24 patients. They used several reconstruction techniques, and 8 of 24 patients (33%) underwent a figure-of-eight reconstruction. These patients had a mean Simple Shoulder Test score of 11.4 (perfect score = 12), although 7 of 8 patients reported physical limitations after a mean 55-month follow-up period.<sup>3</sup>

Transfixation of the SC joint with Kirschner wires was traditionally used to treat SC joint instability. Ferrandez

et al<sup>12</sup> reported significant residual deformity in 4 of 6 patients (67%) after a 2.5-year follow-up period. In 2 patients, the Kirschner wires migrated into mediastinal organs, with the potential for fatal complications.

In another heterogeneous cohort, Panzica et al<sup>21</sup> compared the outcomes in 11 patients after medial clavicle resection or SC joint reconstruction with Kirschner wires or polydioxanone sulfate sutures at minimum 1-year follow-up (range, 1-27 years). In those patients whose SC joint was reconstructed, the mean ASES score was 91.7, the mean DASH score was 5.3, and the mean Constant score was 87.8 postoperatively.

Franck et al<sup>13</sup> used a Balsaer plate fixation method and reported a mean postoperative Constant score of 90.2. However, due to thin soft tissue coverage of the SC joint, plating usually requires a second surgery for hardware removal after healing of the SC joint capsule and supporting ligaments is complete.<sup>13</sup>

As an alternative fixation device, suture anchors have been suggested for SC joint reconstruction. Abiddin et al<sup>1</sup> used suture anchors to reconstruct the SC joint in 8 shoulders with a mean 4.5-year follow-up and reported a mean postoperative Constant score of 74.9. Also using suture anchors, Bak and Fogh<sup>4</sup> recently reported outcomes for 32 patients with a median follow-up of 4.5 years operated on in a novel technique, modified from the Spencer figure-of-eight.<sup>26</sup> They used a palmaris longus autograft in 7 patients and a gracilis autograft in 25 patients. For the clavicle, they drilled 2 holes according to the Spencer technique, and inserted a single suture anchor into the manubrium sterni to avoid retrosternal surgical dissection. The median Western Ontario Shoulder Instability score in their cohort improved from 44% preoperatively to 75% at follow-up. The procedure failed in 2 patients (7.4%) who required revision surgery, after which they remained stable. However, 17 of 25 patients (68%) in their study complained of donor site morbidity, and 10 (40%) had residual discomfort at the final follow-up.<sup>4</sup>

Using 2 tenodesis screws instead of suture anchors as another modification of the Spencer figure-of-eight technique, Sabatini et al<sup>23</sup> recently evaluated the clinical outcomes of 10 patients undergoing SC joint reconstruction with allograft tendons at an average follow-up of 3 years. In their cohort, the mean ASES score improved from 35.3 preoperatively to 84.7 at follow-up. The mean VAS score improved from 7.0 to 1.2 at follow-up. They reported minor postoperative complications in 2 patients (20%).<sup>23</sup> The improvement in ASES score in this cohort was comparable to our study. However, they reported a much higher complication rate of 20%.

In a study with a comparable technique, Singer et al<sup>25</sup> monitored 6 patients for a minimum of 14 months after figure-of-eight SC joint reconstruction using hamstrings (semitendinosus or gracilis tendon autografts). The DASH score significantly improved from 54.3 preoperatively to 28.8 postoperatively. Because only DASH scores were

reported, outcomes could not be comprehensively evaluated, thereby limiting the generalizability of the study. However, their results do suggest that residual dysfunction is likely present more than 1 year after surgery. The improvement of the QuickDASH score was more pronounced in our cohort.

As an alternative to hamstring autografts, sternocleidomastoid autografts have been suggested for SC joint reconstruction. Armstrong and Dias<sup>2</sup> used the medial sternocleidomastoid tendon as an autograft in 7 patients, with rather poor results. Only 2 of 7 patients (29%) had stable SC joints at a mean 39.7 months of follow-up. Uri et al<sup>29</sup> also recently used the tendon of the sternal head of the ipsilateral sternocleidomastoid muscle for SC joint reconstruction and monitored 32 patients for a mean of 3.5 years. Contradictory to the findings of Armstrong and Dias,<sup>2</sup> a stable joint with no functional limitation was achieved in their cohort of 11 of 14 patients with post-traumatic instability, in 6 of 7 patients with generalized hyperlaxity, and in 8 of 11 patients with degenerative instability. Two patients reported persistent postoperative instability and declined further surgical intervention. No other complications occurred.<sup>29</sup>

This study has several limitations. First, due to its rare occurrence and risk potential for patients, a rather small number of patients were available for analysis. However, our cohort is still relatively large compared with previously published studies, and—of particular importance—homogeneous in the applied surgical technique. Before this surgical repair is attempted, it is important for the surgeon to have an intimate knowledge of the SC joint anatomy, thereby avoiding potentially life-threatening complications.

Second, although minimum 2-year data are not reported here, at a mean of 2 years, these patients remained stable and pain free, with minimal complications.

Lastly, the outcomes measures used in this study have not been validated for use in SC joint disorders; however, they have been used in other studies on the SC joint.

## Conclusion

Free hamstring tendon autograft reconstruction for SC joint instability resulted in significantly improved clinical outcomes compared with preoperative baselines, with high patient satisfaction, and no intraoperative or postoperative complications.

## Disclaimer

This research was supported by the Steadman Philippon Research Institute. The Institute receives research support from Smith & Nephew Endoscopy, Inc, Arthrex, Siemens Medical Solutions USA, Inc, Ossur Americas,

Inc, and Opedix, Inc. This work was not supported directly by outside funding or grants.

Peter J. Millett has received something of value (exceeding the equivalent of US \$500) from Arthrex not related to this manuscript or research. He is a consultant and receives payments from Arthrex and has stock options in GameReady and VuMedi. He is also a consultant for Myos. Arthrex has funded the research positions of Maximilian Petri and Frank Martetschläger at the Steadman Philippon Research. The other authors receive support from the Steadman Philippon Research Institute.

## References

1. Abiddin Z, Zinopidis C, Grocock CJ, Yin Q, Frostick SP. Suture anchors for treatment of sternoclavicular joint instability. *J Shoulder Elbow Surg* 2006;15:315-8. <http://dx.doi.org/10.1016/j.jse.2005.07.005>
2. Armstrong AL, Dias JJ. Reconstruction for instability of the sternoclavicular joint using the tendon of the sternocleidomastoid muscle. *J Bone Joint Surg Br* 2008;90:610-3. <http://dx.doi.org/10.1302/0301-620X.90B5.20293>
3. Bae DS, Kocher MS, Waters PM, Micheli LM, Griffey M, Dichtel L. Chronic recurrent anterior sternoclavicular joint instability: results of surgical management. *J Pediatr Orthop* 2006;26:71-4. <http://dx.doi.org/10.1097/01.bpo.0000187998.91837.b2>
4. Bak K, Fogh K. Reconstruction of the chronic anterior unstable sternoclavicular joint using a tendon autograft: medium-term to long-term follow-up results. *J Shoulder Elbow Surg* 2014;23:245-50. <http://dx.doi.org/10.1016/j.jse.2013.05.010>
5. Barth E, Hagen R. Surgical treatment of dislocations of the sternoclavicular joint. *Acta Orthop Scand* 1983;54:746-53.
6. Bearn JG. Direct observations on the function of the capsule of the sternoclavicular joint in clavicular support. *J Anat* 1967;101:159-70.
7. Bontempo NA, Mazzocca AD. Biomechanics and treatment of acromioclavicular and sternoclavicular joint injuries. *Br J Sports Med* 2010;44:361-9. <http://dx.doi.org/10.1136/bjism.2009.059295>
8. Castropil W, Ramadan LB, Bitar AC, Schor B, de Oliveira D'Elia C. Sternoclavicular dislocation—reconstruction with semitendinosus tendon autograft: a case report. *Knee Surg Sports Traumatol Arthrosc* 2008;16:865-8. <http://dx.doi.org/10.1007/s00167-008-0527-9>
9. de Jong KP, Sukul DM. Anterior sternoclavicular dislocation: a long-term follow-up study. *J Orthop Trauma* 1990;4:420-3.
10. Eskola A. Sternoclavicular dislocation. A plea for open treatment. *Acta Orthop Scand* 1986;57:227-8.
11. Eskola A, Vainionpaa S, Vastamaki M, Slati P, Rokkanen P. Operation for old sternoclavicular dislocation. Results in 12 cases. *J Bone Joint Surg Br* 1989;71:63-5.
12. Ferrandez L, Usabiaga J, Ramos L, Ybero J, No L. Migration of Kirschner wires into the mediastinum after stabilization of sternoclavicular lesions. A report of two cases. *Chir Organi Mov* 1991;76:301-4.
13. Franck WM, Jannasch O, Siassi M, Hennig FF. Balsaer plate stabilization: an alternate therapy for traumatic sternoclavicular instability. *J Shoulder Elbow Surg* 2003;12:276-81. [http://dx.doi.org/10.1016/S1058-2746\(02\)86802-1](http://dx.doi.org/10.1016/S1058-2746(02)86802-1)
14. Friedrich L, Afifi FK, Skarvan J, Friederich NF, Hirschmann MT. Combined gracilis tendon autograft reconstruction and discus repair of a chronic anterior-superior sternoclavicular joint dislocation. *Knee*

- Surg Sports Traumatol Arthrosc 2012;20:1978-82. <http://dx.doi.org/10.1007/s00167-011-1852-y>
15. Glass ER, Thompson JD, Cole PA, Gause TM II, Altman GT. Treatment of sternoclavicular dislocations: a systematic review of 251 dislocations in 24 case series. *J Trauma* 2011;70:1294-8. <http://dx.doi.org/10.1097/TA.0b013e3182092c7b>
  16. Groh GI, Wirth MA. Management of traumatic sternoclavicular joint. *J Am Acad Orthop Surg* 2011;19:1-7.
  17. Lee JT, Campbell KJ, Michalski MP, Wilson KJ, Spiegl UJ, Wijidicks CA, Millett PJ. Surgical anatomy of the sternoclavicular joint: a qualitative and quantitative anatomical study. *J Bone Joint Surg Am* 2014;96:e166. <http://dx.doi.org/10.2106/JBJS.M.01451>
  18. Martetschläger F, Warth RJ, Millett PJ. Instability and degenerative arthritis of the sternoclavicular joint: a current concepts review. *Am J Sports Med* 2014;42:999-1007. <http://dx.doi.org/10.1177/0363546513498990>
  19. Merriman JA, Villacis D, Wu B, Patel D, Yi A, Hatch GF 3rd. Does patient sex affect the anatomic relationships between the sternoclavicular joint and posterior vascular structures? *Clin Orthop Relat Res* 2014;472:3495-506. <http://dx.doi.org/10.1007/s11999-014-3853-x>
  20. Omer GE Jr. Osteotomy of the clavicle in surgical reduction of anterior sternoclavicular dislocation. *J Trauma* 1967;7:584-90.
  21. Panzica M, Zeichen J, Hankemeier S, et al. Long-term outcome after joint reconstruction or medial resection arthroplasty for anterior SCJ instability. *Arch Orthop Trauma Surg* 2010;130:657-65. <http://dx.doi.org/10.1007/s00402-009-0911-z>
  22. Rockwood CA Jr, Groh GI, Wirth MA, Grassi FA. Resection arthroplasty of the sternoclavicular joint. *J Bone Joint Surg Am* 1997;79:387-93.
  23. Sabatini JB, Shung JR, Clay TB, Oladeji LO, Minnich DJ, Ponce BA. Outcomes of augmented allograft figure-of-eight sternoclavicular joint reconstruction. *J Shoulder Elbow Surg* 2015;24:902-7. <http://dx.doi.org/10.1016/j.jse.2014.10.001>
  24. Salvatore JE. Sternoclavicular joint dislocation. *Clin Orthop Relat Res* 1968;58:51-5.
  25. Singer G, Ferlic P, Kraus T, Eberl R. Reconstruction of the sternoclavicular joint in active patients with the figure-of-eight technique using hamstrings. *J Shoulder Elbow Surg* 2013;22:64-9. <http://dx.doi.org/10.1016/j.jse.2012.02.009>
  26. Spencer EE Jr, Kuhn JE. Biomechanical analysis of reconstructions for sternoclavicular joint instability. *J Bone Joint Surg Am* 2004;86-A:98-105.
  27. Thacker MM, Patankar JV, Goregaonkar AB. A safe technique for sternoclavicular stabilization. *Am J Orthop (Belle Mead NJ)* 2006;35:64-6.
  28. Thut D, Hergan D, Dukas A, Day M, Sherman OH. Sternoclavicular joint reconstruction: a systematic review. *Bull NYU Hosp Jt Dis* 2011;69:128-35.
  29. Uri O, Barmpagiannis K, Higgs D, Falworth M, Alexander S, Lambert SM. Clinical outcome after reconstruction for sternoclavicular joint instability using a sternocleidomastoid tendon graft. *J Bone Joint Surg Am* 2014;96:417-22. <http://dx.doi.org/10.2106/JBJS.M.00681>
  30. Wasylenko MJ, Busse EF. Posterior dislocation of the clavicle causing fatal tracheoesophageal fistula. *Can J Surg* 1981;24:626-7.