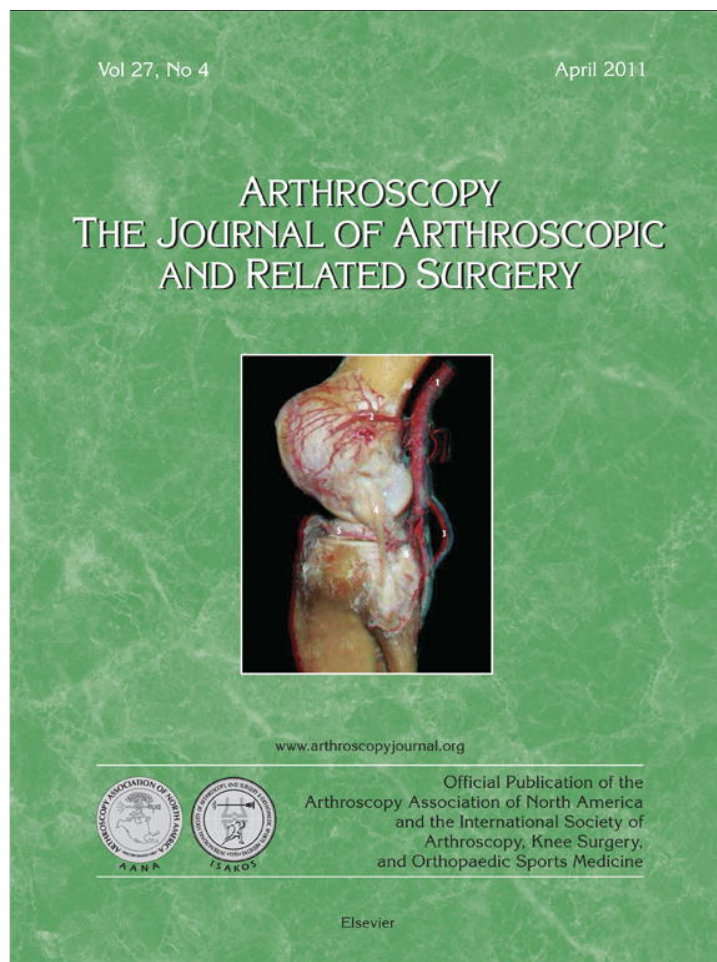


Provided for non-commercial research and education use.
Not for reproduction, distribution or commercial use.



This article appeared in a journal published by Elsevier. The attached copy is furnished to the author for internal non-commercial research and education use, including for instruction at the authors institution and sharing with colleagues.

Other uses, including reproduction and distribution, or selling or licensing copies, or posting to personal, institutional or third party websites are prohibited.

In most cases authors are permitted to post their version of the article (e.g. in Word or Tex form) to their personal website or institutional repository. Authors requiring further information regarding Elsevier's archiving and manuscript policies are encouraged to visit:

<http://www.elsevier.com/copyright>

Level V Evidence

Anatomy, Function, Injuries, and Treatment of the Long Head of the Biceps Brachii Tendon

Florian Elser, M.D., Sepp Braun, M.D., Christopher B. Dewing, M.D., J. Erik Giphart, Ph.D., and Peter J. Millett, M.D., M.Sc.

Abstract: Lesions of the long head biceps tendon (LHB) are frequent causes of shoulder pain and disability. Biceps tenotomy and tenodesis have gained widespread acceptance as effective procedures to manage both isolated LHB pathology and combined lesions of the rotator cuff and biceps-labral complex. The function of the LHB tendon and its role in glenohumeral kinematics presently remain only partially understood because of the difficulty of cadaveric and in vivo biomechanical studies. The purpose of this article is to offer an up-to-date review of the anatomy and biomechanical properties of the LHB and to provide an evidence-based approach to current treatment strategies for LHB disorders.

The long head of the biceps (LHB) tendon has long been considered a troublesome pain generator in the shoulder. Biceps tenotomy and tenodesis have gained widespread acceptance as quick, easy, and cost-effective procedures to manage both isolated LHB pathology and combined lesions of the rotator cuff and biceps-labral complex. Although these procedures have documented success in most outcomes studies, controversy persists as to the possible functional contributions of the LHB to shoulder stability and motion. This article offers an up-to-date review of the anatomy and biomechanical properties of the LHB

and current strategies for successful treatment of LHB pathology (Tables 1-3).

ANATOMY

The LHB originates from the supraglenoid tubercle of the scapula with an intra-articular portion that passes over the humeral head before exiting the glenohumeral joint through the bicipital groove.^{1,2} The tendon is approximately 5 to 6 mm in diameter and approximately 9 cm in length. The size of the tendon varies, and the intra-articular portion is typically wide and flat whereas the extra-articular portion is both rounder and smaller.³ The anterior circumflex humeral artery provides blood supply to the articular portion of the LHB. The more distal portion of the LHB is fibrocartilaginous and avascular to accommodate its sliding motion within its sheath in the groove, whereas the proximal tendon is more richly vascularized.

Alpantaki et al.⁴ found a “net-like pattern” of rich sensory and sympathetic innervations of the LHB, which was concentrated at the biceps tendon anchor and became attenuated at the distal musculotendinous junction.

A soft-tissue sling stabilizes the extra-articular LHB as it enters the bicipital groove (Figs 1 and 2). This

From the Steadman Philippon Research Institute (F.E., S.B., C.B.D., J.E.G., P.J.M.), Vail, Colorado, and Department of Orthopaedic Surgery, Naval Medical Center San Diego (C.B.D.), San Diego, CA, U.S.A; Klinikum rechts der Isar (F.E., S.B.), Technical University Munich, Munich, Germany.

F.E., S.B., and P.J.M. have received support from Arthrex exceeding \$500 related to this research.

Received September 15, 2010; accepted October 20, 2010.

Address correspondence to Peter J. Millett, M.D., M.Sc., Steadman Philippon Research Institute, 181 West Meadow Dr, Ste 100, Vail, CO 81657, U.S.A. E-mail: drmillett@steadmanclinic.net

*© 2011 by the Arthroscopy Association of North America
0749-8063/10547/\$36.00*

doi:10.1016/j.arthro.2010.10.014

TABLE 1. Overall Key Points

Cadaveric biomechanical studies suggest that the LHB has stabilizing effects on the glenohumeral joint in all directions. In vivo studies have yet to establish this stabilizing effect. EMG studies have further questioned the role of the LHB in shoulder kinematics, showing little or no activation when the elbow is immobilized. Further in vivo investigations using advanced imaging for increased precision are needed to better define the role of the LHB in glenohumeral kinematics.

biceps reflection pulley (BRP) is built by fibers of the coracohumeral ligament, superior glenohumeral ligament (SGHL), and parts of the subscapularis tendon, as shown by anatomic dissection and histology.⁵ The LHB is subject to mechanical stresses in the groove, at the pulley, and by pathology of the rotator cuff and subacromial space. Braun et al.⁶ have shown in a biomechanical study that the tendon slides up to 18 mm in and out of the glenohumeral joint in forward flexion and internal rotation compared with a reference of neutral arm position and neutral rotation. Habermeyer et al.⁷ described a 30° to 40° turn of the biceps tendon as it exits the joint and stabilization of the tendon by a pulley sling.

The depth and morphology of the bicipital groove may also play a role in function, stability, and not least of all, pathology of the LHB. Pfahler et al.⁸ described the bicipital groove anatomy in a radiographic study. The medial wall of the bicipital groove was higher, with an opening angle from 30° to 40° in most patients without LHB pathology. The total opening angle between the lateral and medial wall was found to be 101° to 120° in most asymptomatic shoulders.

FUNCTION OF LHB TENDON

A majority of biomechanical studies investigating the role of the LHB have focused on its contributions

TABLE 2. Key Points of LHB Pathologies

Instability of the LHB varies from subluxation to dislocation and is usually associated with rotator cuff tears, especially subscapularis tendon tears. High shear forces to the biceps reflection pulley occur in forward flexion and internal rotation and may result in "hidden" pulley lesions. Proximal biceps tenodesis may result in residual pain in the bicipital groove. Coracoid impingement is an often overlooked cause of anterior shoulder pain.

TABLE 3. Key Points of Current Treatment Strategies

Although LHB tenotomy has shown excellent results for pain relief, tenodesis has been shown to better restore supination strength and endurance, in addition to maintaining normal biceps contour. In patients with coracoid impingement and limited CHI, a coracoidplasty may be considered. Subpectoral biceps tenodesis yields excellent outcomes with a low complication rate. There is evidence to suggest that functional outcomes and return to sport may be improved with biceps tenodesis compared with SLAP repair, but further studies are needed.

to glenohumeral stability, restraining abnormal translations. With few exceptions,^{9,10} these studies have relied on cadaveric models to examine this interaction.

Cadaveric Biomechanical Studies

Pagnani et al.¹¹ tested the effect of simulated contraction of the LHB (55 N) in 10 cadaveric shoulders and showed significantly decreased humeral head translations anteriorly, superiorly, and inferiorly when load was applied to the biceps, especially in lower angles of elevation.

Itoi et al.¹² concluded from their biomechanical studies that both the LHB and the short head of the biceps brachii are anterior stabilizers to the glenohumeral joint in abduction and external rotation when loaded with 1.5 kg and 3 kg. According to their work,

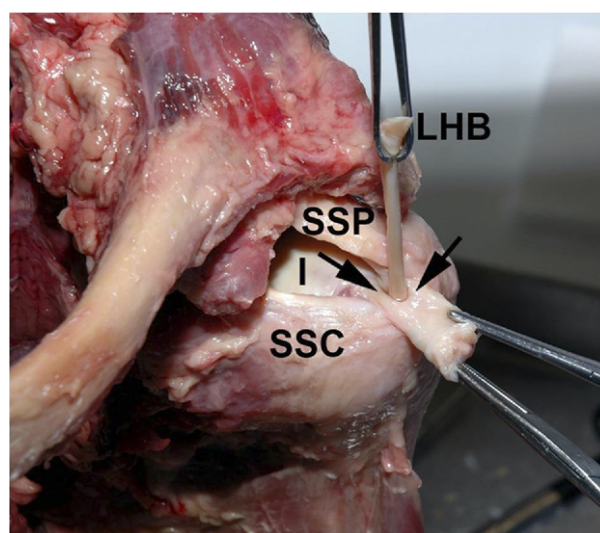


FIGURE 1. Cadaver (left shoulder) showing pulley sling (arrows). The rotator interval (I) has been dissected from the supraspinatus (SSP) and subscapularis (SSC) tendons. The LHB has been dissected from its origin at the glenoid.

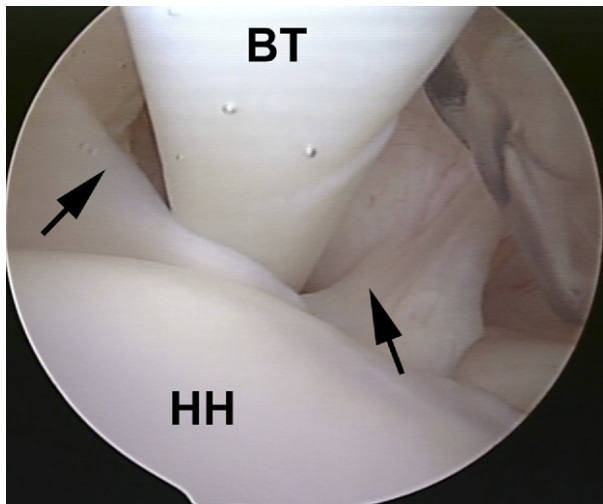


FIGURE 2. Arthroscopic view of a left shoulder from posterior showing intact biceps pulley (arrows). (BT, biceps tendon; HH, humeral head.)

the role of both tendons increases in a setting of instability.

Rodosky et al.¹³ performed a study using a dynamic cadaveric shoulder model that simulated the forces of the rotator cuff and LHB muscles. Their data suggest that the long head of the biceps muscle contributes to anterior stability of the glenohumeral joint by increasing the shoulder's resistance to torsional forces in the vulnerable abducted and externally rotated position. Furthermore, the authors found significantly less torsional rigidity and significantly increased strain to the inferior glenohumeral ligament in a setting of detachment of the biceps-labral complex at the superior glenoid.

Payne et al.¹⁴ applied a 40-N load to the biceps tendon and found a significant decrease in anterolateral contact pressure in 6 shoulders whereas the contact pressures in 3 shoulders with type III acromions were unchanged. Kumar et al.¹⁵ showed that tensioning of the short head of the biceps alone caused significant upward migration of the humeral head whereas tensioning of the LHB alone or of both heads did not cause any difference in a setting of simulated powerful elbow flexion and supination. When the LHB was cut, there was also a significant upward migration noted. The authors concluded that the LHB therefore plays a stabilizing role in the glenohumeral joint in powerful elbow flexion and supination.

Youm et al.¹⁶ showed in a recently published biomechanical study that the loaded LHB (22 N) significantly affects glenohumeral translation (anterior,

posterior, superior, and inferior), kinematics, and rotational range of motion in a simulated position of 90° of arm abduction and different angles of internal and external rotation.

Su et al.¹⁷ applied 55 N of load to the LHB in differently sized rotator cuff tears. They found significantly decreased anterosuperior and superior glenohumeral translation when loading the LHB for all sizes of rotator cuff tears.

The conclusion is that biomechanical studies indicate that the LHB contributes to stability of the glenohumeral joint in all directions. However, considerable variability exists with regard to the load applied to the tendon (11 to 55 N). The maximum load of 55 N has been predicted by multiplying the physiologic cross-sectional area of the LHB by an accepted conversion factor.¹⁸ Closer examination of this report shows that the mean potential moment generated by LHB was 16.8 Ncm⁻¹ and the mean moment arm was 2.4 cm. This produces a load of 40.32 N and not 55 N. Some authors found this load to be extremely high¹⁶ and therefore incorporated electromyographic (EMG) data showing the percentage of maximum voluntary contractions for the positions or motions tested to calculate the proper biceps load. Interestingly, Youm et al.¹⁶ calculated a biceps load of 11 N for their model but did not find significant changes with that load. The conclusion is that we do not know to date how much load is physiologic for the LHB tendon. However, the amount of load is critical for all biomechanical studies. It is therefore possible that some studies that applied higher loads showed significant changes because of nonphysiologic high loads.

EMG Studies

There are many studies in the literature that document activity of the biceps brachii during shoulder motion.¹⁹⁻²⁴ The important question for all EMG studies is how the recorded biceps activity affects glenohumeral joint kinematics.

There are 2 EMG studies that examined the effects of the biceps on the shoulder. In both studies the elbow joint was immobilized with a brace to minimize elbow-related biceps activity. Interestingly, the findings of these studies appear to be contradictory. Sakurai et al.²² found that LHB activity stabilized the humeral head, whereas Levy et al.²¹ found that the LHB either had a passive role or served as a functional stabilizer only when tensioned in association with elbow and forearm activity.

Jobe et al.²⁵ evaluated pitching biomechanics and showed that the biceps predominantly activates during cocking to accomplish elbow flexion and then reactivates during follow-through to decelerate the forearm. In a recent study Rojas et al.²⁶ found that biceps activity was higher during windmill pitch than during overhead throw, especially before and after ball release between 9 o'clock and the follow-through phase. In this position it is likely that most of the biceps activity is attributed to elbow and not shoulder function.

These are important findings for interpretation not only of EMG but also of biomechanical cadaveric studies that assume that there is bicipital activity associated with shoulder activities.

The conclusion from EMG data on LHB function remains controversial. On the basis of the current literature, it is not clear whether the biceps activity during shoulder movements is partly, mainly, or completely from the activation at the elbow joint. However, these data, as stated previously, are critical for all biomechanical studies, because they form the foundation for the amount to which the LHB should be loaded.

In Vivo Biomechanical Studies

Warner and McMahon¹⁰ performed a radiographic study on 7 patients with loss of the proximal attachment of the LHB compared with the healthy contralateral control. In this study true anteroposterior radiographs were made in 0°, 45°, 90°, and 120° of abduction in the scapular plane. The authors found a significant superior translation of the humeral head at all degrees of abduction in patients with rupture of the LHB.

Intraoperative electrical stimulation of the biceps muscle during arthroscopy in 5 patients showed a compression of the glenohumeral joint.⁹ Kido et al.²⁷ documented higher humeral head positions in patients with rotator cuff tears without contraction of the biceps. In this study the humeral head depressed significantly at different angles of abduction when the biceps muscle was activated in a radiographic model. The authors concluded that the LHB has an active depressor function of the humeral head.

The conclusion from in vivo studies is that because of a lack of applicable methods, there is almost no evidence about the function of the LHB in vivo. Both the studies of Warner and McMahon¹⁰ and Kido et al.²⁷ are based on a radiographic model with true anteroposterior radiographs. There are concerns about

the accuracy of these models for several reasons. First, in different angles of scaption, the scapula moves around the thorax and the orientation of the glenoid changes with that movement. It is therefore difficult to generate true anteroposterior radiographs with any consistency. Second, these methods fail to capture 3-dimensional movements. Finally, the accuracy of such measurements remains quite limited.

Although the existing body of biomechanical work suggests that the loaded LHB may restrain the shoulder from abnormal translations, many researchers have admitted the limitations of cadaveric testing in re-creating the dynamic interplay of anatomy that occurs in vivo. Further in vivo investigations must be undertaken with advanced imaging technology to elucidate the biomechanical role of the LHB.

We have recently performed a biplane fluoroscopy in vivo study on LHB function in 5 patients (10 shoulders) to assess LHB function during various arm movements. In contrast to the findings in previous studies,^{10,27} we did not find an increase in superior migration for shoulders when the LHB was absent (subjects with isolated subpectoral tenodesis) when compared with their healthy contralateral controls. We did find that the shoulders that had undergone tenodesis tended to be more anteriorly positioned ($P = .003$), but the difference was only 0.7 mm, which does not appear to be clinically significant (unpublished data, J.E.G., November 2010).

LHB PATHOLOGIES

The LHB can be a source of shoulder pain or diminished function for various reasons. LHB pathologies include tendinitis, rupture, subluxation or instability, pulley lesions, and SLAP lesions.

Tendon Rupture

The most common sites of tendon rupture are at the tendon's origin and at the exit of the bicipital groove near the musculotendinous junction.²⁸ When ruptures of the long head occur, the muscle mass moves distally, often resulting in a characteristic Popeye deformity. Ruptures of the long head are most common in patients aged over 50 years, and they occur more frequently than ruptures of the short head or the distal tendon, accounting for 96% of all biceps brachii injuries.¹ Often, they are associated with biceps tendinitis,²⁹ which may lead to degeneration of the biceps tendon and a resulting rupture with little or no trauma.²⁸

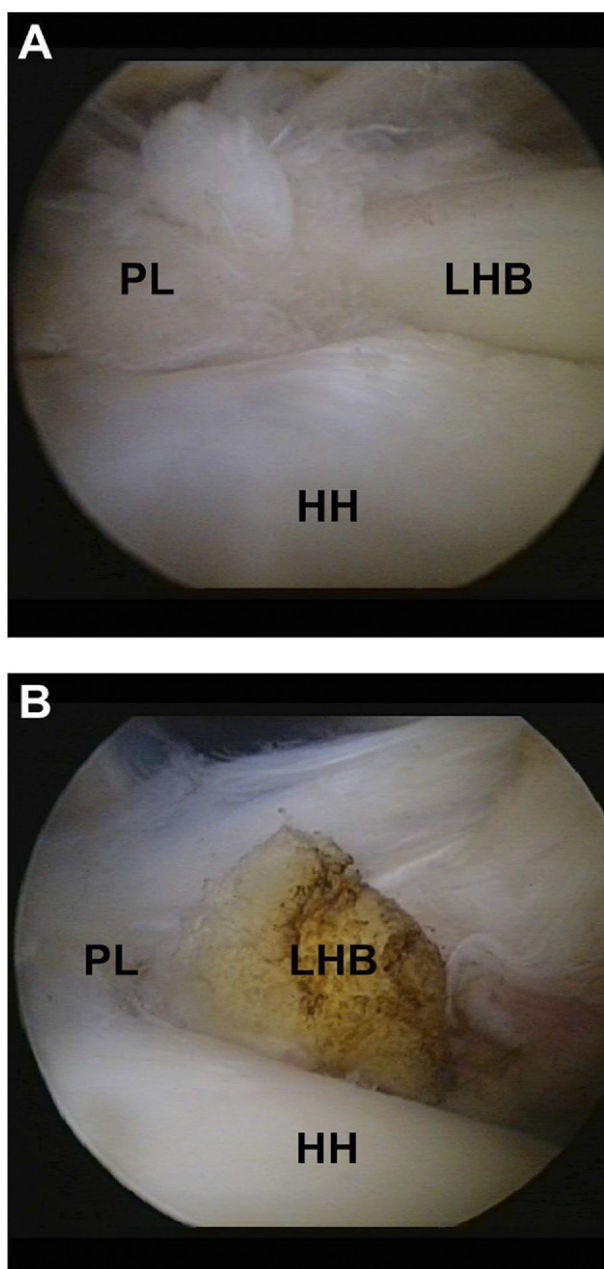


FIGURE 3. Arthroscopic views of a right shoulder from posterior. (A) Pulley lesion with dislocation of LHB into subscapularis tendon. (B) Damage to subscapularis tendon after tenotomy of LHB. (HH, humeral head.)

Biceps Instability

LHB instability and BRP tears,³⁰⁻³² so-called pulley or biceps reflection pulley lesions (Fig 3), are well described. Instability of the LHB varies from subluxation to dislocation and is usually associated with rotator cuff tears, especially subscapularis ten-

don tears.³³ Different classification systems for biceps instability have been described.^{7,30} Habermeyer et al.⁷ defined 4 different arthroscopically observed types, with isolated lesions of the SGHL (type I), SGHL lesion and a partial articular-sided supraspinatus tendon tear (type II), SGHL lesion and a deep surface tear of the subscapularis tendon (type III), and lesion of the SGHL combined with a partial articular-sided supraspinatus and subscapularis tendon tear (type IV).

We have performed a prospective study to look at the incidence of injury to the BRP in a group of 229 consecutive patients undergoing shoulder arthroscopy. The incidence of BRP or pulley lesions was 32.4%. As stated initially, there is a significant correlation between pulley lesions and SLAP tears ($P = .003$), rotator cuff pathology ($P = .001$), and LHB pathologies ($P < .05$).³⁴

There is speculation that loading the tendon in external rotation–abduction positions of the arm is the pathomechanism of these pulley lesions.^{7,32} Our findings in a biplane fluoroscopy cadaveric study showed high shear forces on the BRP in the following shoulder positions⁶:

- forward flexion and internal rotation
- neutral position
- neutral position and internal rotation

Coracoid Impingement

Coracoid impingement can be another cause for anterior shoulder pain. It is defined as the impingement of the subcoracoid bursa and subscapularis tendon between the coracoid and lesser tuberosity. It has been described as a potential cause of degenerative wear of the pulley sling and subscapularis tendon insertion,³⁵ but not mechanical wear of the LHB, as it slides up and down in the bicipital groove.

The coracohumeral interval (CHI) can be measured on axial cuts of cross-sectional images and is defined as the shortest distance between the humeral head and the coracoid tip (Fig 4). There is no consistency in the literature regarding reference values for the CHI. Gerber et al.³⁶ found a mean distance of 8.7 mm on computed tomography scans in healthy subjects with the shoulder in adduction, whereas Giaroli et al.³⁷ found a sex-adjusted CHI of 10.5 to 11.5 mm in patients with coracoid impingement on magnetic resonance imaging. Our own data suggest that narrowing of the CHI distance on magnetic resonance imaging is related to pathologies of the LHB and rotator cuff. We found a mean distance of 10.2 mm for subjects with

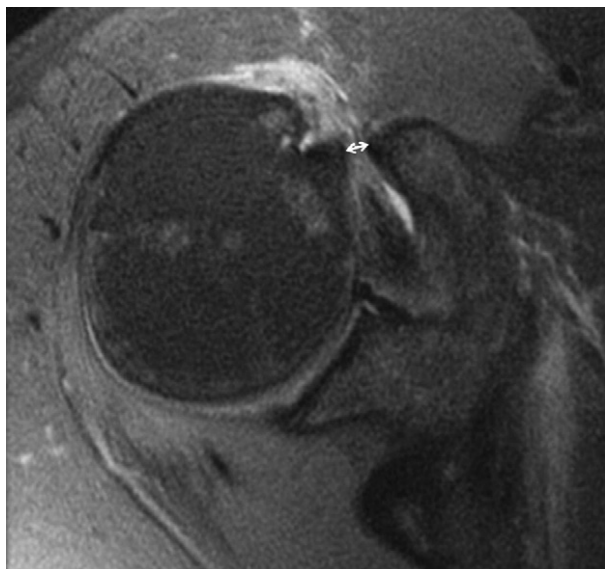


FIGURE 4. Cross-sectional magnetic resonance image of a patient with narrowed CHI (i.e., shortest distance between humeral head and tip of coracoid) (arrow).

anterior shoulder pathology and 12.3 mm without anterior shoulder pathology (unpublished data, S.B., November 2010).

SLAP Lesions

The pathology of the superior labrum was first described by Andrews et al.⁹ in 1985. It was subsequently described by Snyder et al.,³⁸ who labeled the pathology “SLAP lesion,” because of the location at the superior labrum extending from anterior to posterior (Figs 5 and 6). Snyder et al. also defined 4 different types of SLAP lesions (types I to IV), which were later supplemented by 3 further types (types V to VII).³⁸ The incidence according to Maffet et al.³⁹ is

11.8% (84 of 712 patients), but there is substantial inter-observer and intraobserver variability even among experienced shoulder arthroscopic specialists with regard to diagnosis and treatment of SLAP tears.⁴⁰ SLAP lesions can be caused by recurrent micro-traumatic impairment, mainly in overhead athletes, or by single traumatic events.⁴¹ The type of SLAP lesion typically dictates treatment.

These injuries are not limited to young throwing athletes as initially described. They are certainly more ubiquitous and may be seen in varying patient populations. Studies have shown that rotator cuff tears are frequently associated with concomitant labral lesions.⁴² In a study performed by Miller and Savoie,⁴³ 74% of individuals with full-thickness rotator cuff tears had associated intra-articular lesions, with labral tears being the most commonly associated disorder. Snyder et al.⁴⁴ showed that 40% of 140 arthroscopically examined superior labral lesions were associated with full- or partial-thickness rotator cuff tears.

Biceps Tendinitis

Slatis and Aalto⁴⁵ have classified biceps lesions into 3 categories: impingement tendinitis, subluxation of the biceps tendon, and attritional tendinitis. Biceps tendinitis is inflammation of the LHB (Fig 7) and most often attributed to surrounding shoulder pathology such as degenerative rotator cuff lesions and impingement syndrome, and it has typically been characterized as a secondary process.⁴⁶ Primary tendinitis is rare and has been estimated to represent about 5% of the cases.⁴⁷ There is a general consensus, however, that tendinitis is the common pathologic process in both primary and secondary degeneration of the tendon.⁴⁸

Treatment of biceps tendinitis has included open decompression of the transverse humeral ligament, which

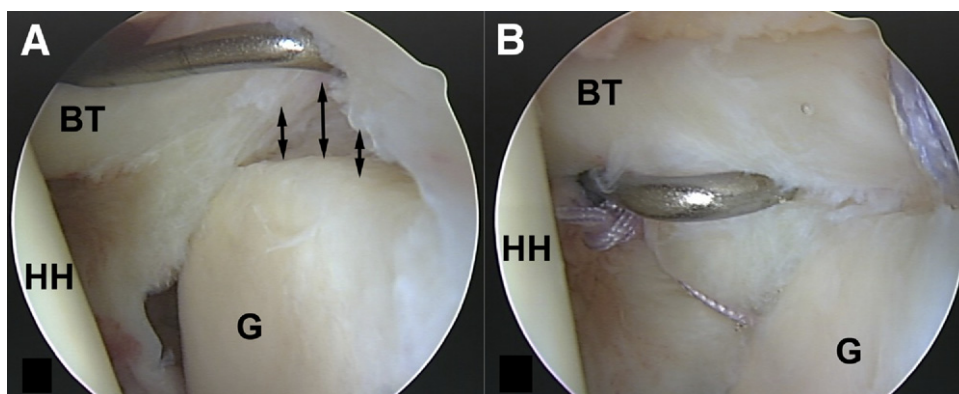


FIGURE 5. Arthroscopic view of a left shoulder from posterior showing SLAP lesion (arrows) (A) before and (B) after repair. (BT, biceps tendon; G, glenoid; HH, humeral head.)

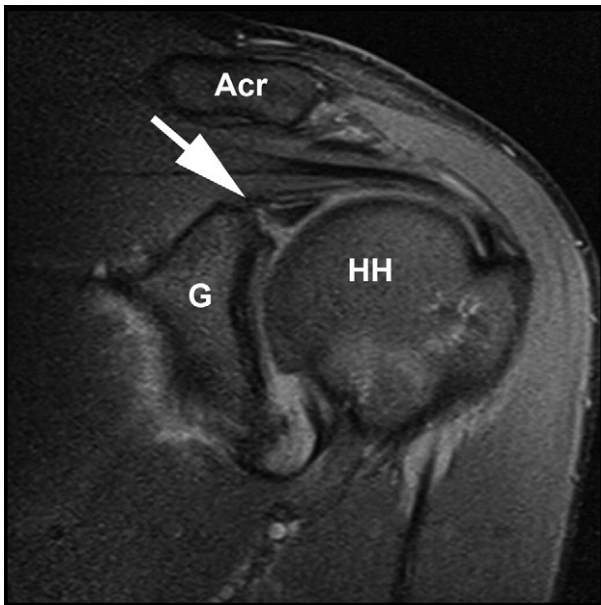

FIGURE 6. Coronal magnetic resonance image of a left shoulder showing SLAP lesion (arrow). (HH, humeral head; G, glenoid; Acr, acromion.)

was initially proposed by Neer,⁴⁹ who released the transverse humeral ligament and decompressed the biceps tendon sheath in an effort to address secondary biceps pathology. Transverse humeral ligament decompression along with synovectomy of the inflamed biceps tendon as an arthroscopic procedure has been advocated for the treatment of isolated biceps tendinitis.⁵⁰⁻⁵²

A specific subtype of bicipital tendinitis has been attributed to the hourglass-shaped LHB tendon, as visualized by magnetic resonance arthrography.⁵³ The mechanical symptoms are attributed to a thickened, inflamed intra-articular LHB that engages the superior

aspect of the bicipital groove during shoulder motion. The hourglass lesion has been likened to a trigger finger of the shoulder in that it prevents the normal excursion that occurs with abduction. This type of pathologic variant is best addressed by subpectoral biceps tenodesis (Figs 8 and 9).⁵⁴

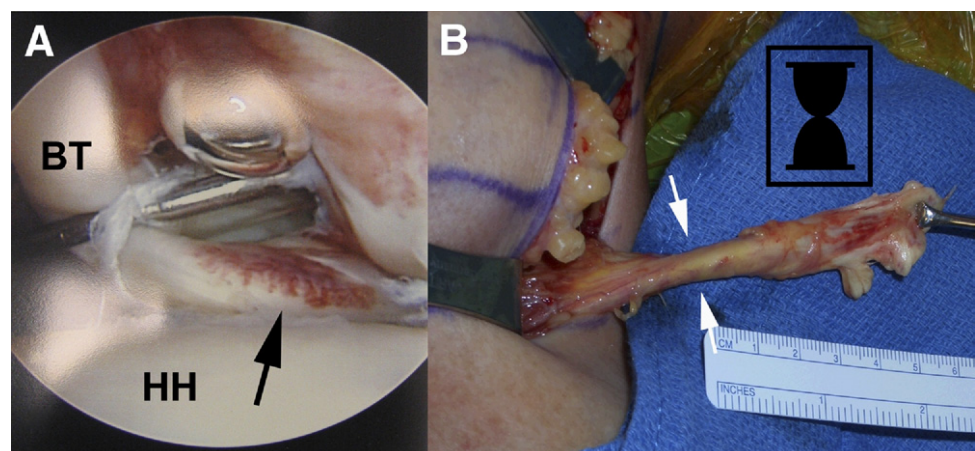
CURRENT TREATMENT STRATEGIES

LHB pathologies can be addressed by nonoperative treatment, reconstructive techniques, and tenodesis/tenotomy.

Conservative treatment of biceps rupture usually results in relatively little functional impairment of the shoulder.²⁸ Research at our institution found no statistical difference at the elbow joint in forearm supination or elbow flexion strength when comparing tenotomy, tenodesis, and control groups.⁵⁵ Because of the minimal functional sequelae of biceps ruptures in middle-aged and older patients, surgical repair is indicated only in those with persistent spasm or in those whose occupations require significant supination strength. Surgical repair is also indicated in younger, more physically active patients or in those in whom the minor strength or cosmetic effects of conservative treatment are unacceptable.^{2,29}

In the case of a tenodesis, the intra-articular portion of the tendon is resected and the proximal portion of the remaining tendon is fixed to the proximal humerus (Fig 8).² In some cases a simple arthroscopic release of the tendon may be performed.^{2,56} There is a lack of quality evidence to advocate tenodesis versus tenotomy.⁵⁷ It has been suggested that tenodesis results in less strength loss compared with conservative treatment for tendon

FIGURE 7. (A) Arthroscopic view of a right shoulder from posterior showing biceps tendinitis (black arrow). (B) Intraoperative view of LHB after tenotomy with an hourglass lesion, with white arrows pointing to narrow part of tendon (right shoulder). (BT, biceps tendon.)



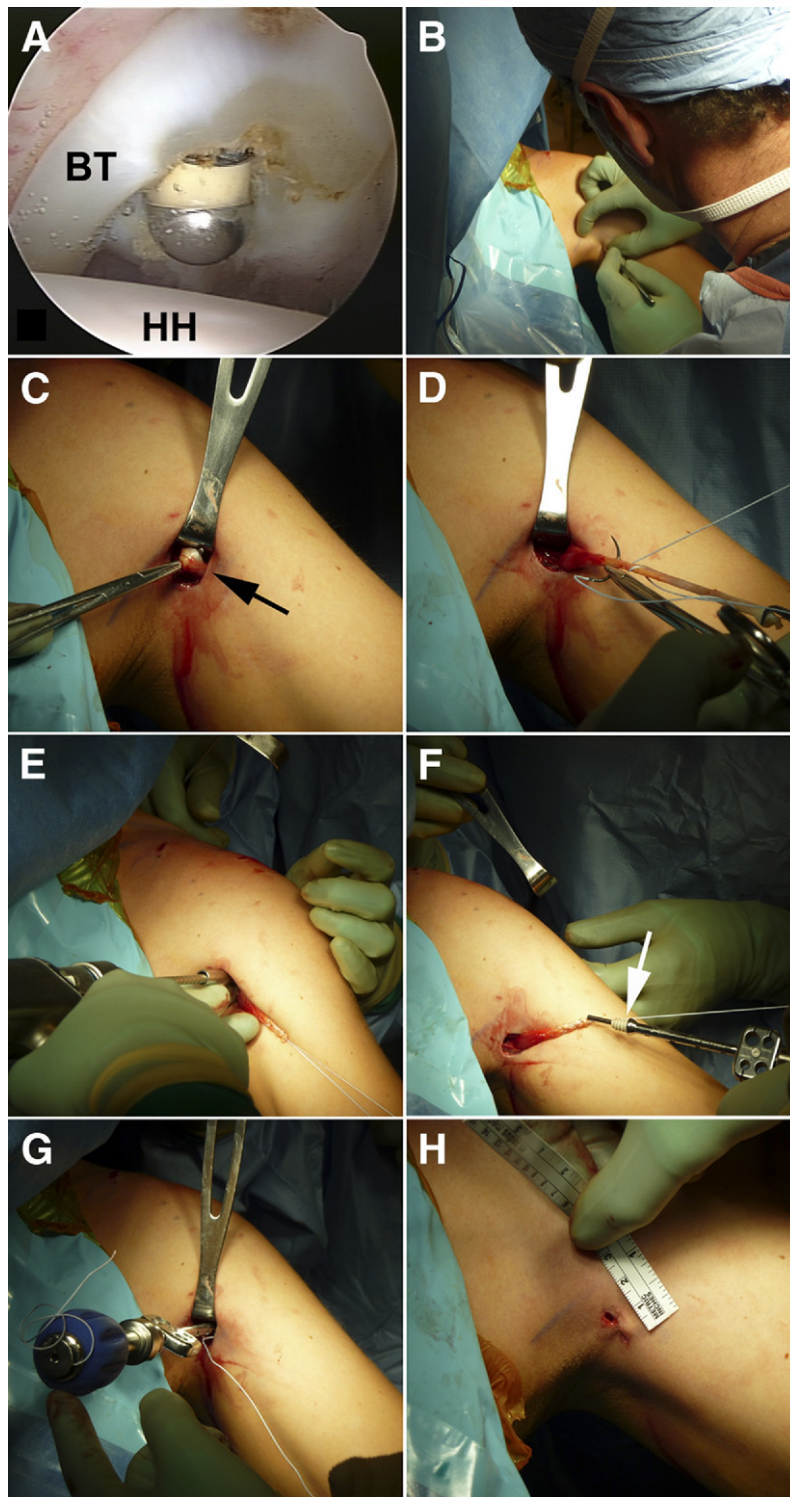


FIGURE 8. Intraoperative images of subpectoral biceps tenodesis of a left shoulder. (A) Arthroscopic view of left shoulder showing tenotomy of biceps tendon (BT) with radiofrequency device. (HH, humeral head.) (B) Subpectoral skin incision. (C) Finding of BT after tenotomy. (D) Preparation of BT for fixation, with stitches for secure bite of interference screw (arrow in F). (E) Drilling of monocortical hole for BT and interference screw. (F and G) Preparation and insertion/fixation of BT with interference screw (arrow). (H) After placement of 1 subcutaneous stitch, the incision measures only 1.5 cm in length.

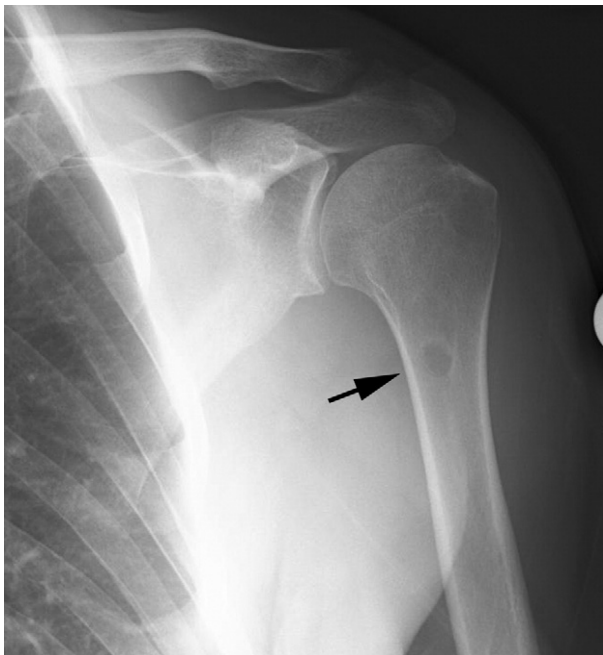

FIGURE 9. Postoperative anteroposterior radiograph of a left shoulder after subpectoral biceps tenodesis (arrow).

rupture⁵⁸ and less risk of postoperative cramping and improved cosmetic results.^{59,60} Multiple techniques for LHB tenodesis have been described. Tenodesis of the LHB may be performed arthroscopically or in an open manner, either above the bicipital groove or through a subpectoral approach. Fixation techniques include suture anchor fixation, suture-to-adjacent tissue fixation, keyhole-to-bone fixation, and interference screw fixation.⁶¹⁻⁶⁹

Biomechanics

Mazzocca et al.⁷⁰ compared cyclic displacement and ultimate failure strength of open subpectoral bone tunnel biceps tenodesis, arthroscopic suture anchor tenodesis, an open subpectoral interference screw fixation technique, and an arthroscopic interference screw technique. They did not find statistically significant differences in ultimate failure strength among any of the methods tested. Other investigators have found superior biomechanical properties for bioabsorbable interference screw fixation compared with suture anchor fixation.^{71,72} However, Millett et al.⁷³ found no statistical difference between interference screw and suture anchor fixation for mini-open subpectoral biceps tenodesis.

Clinical Results

Numerous studies have shown good results after proximal biceps tenodesis.^{65,74-76} However, persistent tenosynovitis or stenosis after arthroscopic or proximal groove tenodesis may cause residual pain in the bicipital groove⁷⁷ and higher failure rates.⁵⁹ Becker and Cofield⁷⁸ found unsatisfactory long-term outcomes after proximal biceps tenodesis in approximately 50% of cases, with a reoperation rate of 15%. They concluded that failures were likely to exhibit subacromial impingement with a rotator cuff tear. According to recent studies, it is more likely that high failure rates after proximal tenodesis are caused by persistent tenosynovitis and pain.⁵⁹ Authors of one study found significantly decreased revision rates after subpectoral tenodesis.⁵⁹ Another study on the incidence and types of complications after an open subpectoral tenodesis procedure found a low complication rate of only 2% in a population of 353 patients over the course of 3 years.⁷⁹

Nonetheless, tenodesis, tenotomy, and conservative treatment of LHB pathology all fail to address the potential loss of superior¹⁵ and anterior¹² stability of the glenohumeral joint. The absence of an LHB tendon may have particular implications for throwers and very young patients in whom instability may lead to long-term functional deficits.²

Symptomatic pulley lesions can also be treated by tenodesis or tenotomy. Some authors perform bicipital pulley repair,⁸⁰ although there are no prospective studies comparing the different treatment options. Depending on the type of SLAP lesion, arthroscopic repair or debridement of the torn tissue can be performed with predictably good results. In more severe cases, biceps tenodesis may be preferable. There is evidence to suggest that return to sport may be improved with biceps tenodesis compared with SLAP repair.^{53,62}

Little evidence exists in the literature about treatment of superior labral lesions in patient populations aged over 45 years with concomitant rotator cuff tears. A recent study published by Abbot et al.⁸¹ showed that patients with debridement and rotator cuff repair had better results than patients with SLAP repair and rotator cuff repair. Studies also indicate that patients with tenodesis or tenotomy have less pain after rotator cuff repair compared with cases where the LHB has been preserved. A recently published study on tenodesis versus repair of type II SLAP lesions suggests that patients with tenodesis have a higher satisfaction rate and are able to return to their previous level of

sports more frequently.⁸² These results suggest that LHB tenodesis may yield superior results over SLAP repair for certain patient groups.

CONCLUSIONS

Biomechanical studies in cadaveric models fail to “recreate the myriad factors that act in synergy to provide glenohumeral stability in vivo.”¹⁶ A consistent limitation of cadaveric biomechanical studies is their failure to apply physiologic loads to the LHB. There is no consensus in the literature, and values range from 11 to 55 N. In future studies LHB loading conditions should reflect in vivo muscle activation levels.

The function of the LHB tendon and its role in glenohumeral kinematics remain poorly understood because of the paucity of literature and the difficulty of performing biomechanical cadaveric and in vivo studies. LHB tenodesis has become a popular surgical treatment for managing isolated and combined pathology of the LHB. Our own research with biplane fluoroscopy in vivo testing indicates that the role of the LHB in glenohumeral kinematics may have been overestimated. Future biomechanical research should focus on in vivo studies to investigate any adverse effects of removing the intra-articular portion of the LHB on glenohumeral kinematics.

REFERENCES

1. Carter AN, Erickson SM. Proximal biceps tendon rupture: Primarily an injury of middle age. *Phys Sportsmed* 1999;27:95-101.
2. Eakin CL, Faber KJ, Hawkins RJ, Hovis WD. Biceps tendon disorders in athletes. *J Am Acad Orthop Surg* 1999;7:300-310.
3. Ahrens PM, Boileau P. The long head of biceps and associated tendinopathy. *J Bone Joint Surg Br* 2007;89:1001-1009.
4. Alpantaki K, McLaughlin D, Karagogeos D, Hadjipavlou A, Kontakis G. Sympathetic and sensory neural elements in the tendon of the long head of the biceps. *J Bone Joint Surg Am* 2005;87:1580-1583.
5. Werner A, Mueller T, Boehm D, Gohlke F. The stabilizing sling for the long head of the biceps tendon in the rotator cuff interval. A histoanatomic study. *Am J Sports Med* 2000;28:28-31.
6. Braun S, Millett PJ, Yongpravat C, et al. Biomechanical evaluation of shear force vectors leading to injury of the biceps reflection pulley: A biplane fluoroscopy study on cadaveric shoulders. *Am J Sports Med* 2010;38:1015-1024.
7. Habermeyer P, Magosch P, Pritsch M, Scheibel MT, Lichtenberg S. Anterosuperior impingement of the shoulder as a result of pulley lesions: A prospective arthroscopic study. *J Shoulder Elbow Surg* 2004;13:5-12.
8. Pfahler M, Branner S, Refior HJ. The role of the bicipital groove in tendopathy of the long biceps tendon. *J Shoulder Elbow Surg* 1999;8:419-424.
9. Andrews JR, Carson WG Jr, McLeod WD. Glenoid labrum tears related to the long head of the biceps. *Am J Sports Med* 1985;13:337-341.
10. Warner JJ, McMahon PJ. The role of the long head of the biceps brachii in superior stability of the glenohumeral joint. *J Bone Joint Surg Am* 1995;77:366-372.
11. Pagnani MJ, Deng XH, Warren RF, Torzilli PA, O'Brien SJ. Role of the long head of the biceps brachii in glenohumeral stability: A biomechanical study in cadavera. *J Shoulder Elbow Surg* 1996;5:255-262.
12. Itoi E, Kuechle DK, Newman SR, Morrey BF, An KN. Stabilising function of the biceps in stable and unstable shoulders. *J Bone Joint Surg Br* 1993;75:546-550.
13. Rodosky MW, Harner CD, Fu FH. The role of the long head of the biceps muscle and superior glenoid labrum in anterior stability of the shoulder. *Am J Sports Med* 1994;22:121-130.
14. Payne LZ, Deng XH, Craig EV, Torzilli PA, Warren RF. The combined dynamic and static contributions to subacromial impingement. A biomechanical analysis. *Am J Sports Med* 1997;25:801-808.
15. Kumar VP, Satku K, Balasubramaniam P. The role of the long head of biceps brachii in the stabilization of the head of the humerus. *Clin Orthop Relat Res* 1989;(244):172-175.
16. Youm T, ElAttrache NS, Tibone JE, McGarry MH, Lee TQ. The effect of the long head of the biceps on glenohumeral kinematics. *J Shoulder Elbow Surg* 2009;18:122-129.
17. Su WR, Budoff JE, Luo ZP. The effect of posterosuperior rotator cuff tears and biceps loading on glenohumeral translation. *Arthroscopy* 2010;26:578-586.
18. Bassett RW, Browne AO, Morrey BF, An KN. Glenohumeral muscle force and moment mechanics in a position of shoulder instability. *J Biomech* 1990;23:405-415.
19. Habermeyer P, Kaiser E, Knappe M, Kreuzer T, Wiedemann E. Functional anatomy and biomechanics of the long biceps tendon. *Unfallchirurg* 1987;90:319-329 (in German).
20. Furlani J. Electromyographic study of the m. biceps brachii in movements at the glenohumeral joint. *Acta Anat (Basel)* 1976;96:270-284.
21. Levy AS, Kelly BT, Lintner SA, Osbahr DC, Speer KP. Function of the long head of the biceps at the shoulder: Electromyographic analysis. *J Shoulder Elbow Surg* 2001;10:250-255.
22. Sakurai G, Ozaki J, Tomita Y, Nishimoto K, Tamai S. Electromyographic analysis of shoulder joint function of the biceps brachii muscle during isometric contraction. *Clin Orthop Relat Res* 1998:123-131.
23. Glousman R, Jobe F, Tibone J, Moynes D, Antonelli D, Perry J. Dynamic electromyographic analysis of the throwing shoulder with glenohumeral instability. *J Bone Joint Surg Am* 1988;70:220-226.
24. Gowan ID, Jobe FW, Tibone JE, Perry J, Moynes DR. A comparative electromyographic analysis of the shoulder during pitching. Professional versus amateur pitchers. *Am J Sports Med* 1987;15:586-590.
25. Jobe FW, Moynes DR, Tibone JE, Perry J. An EMG analysis of the shoulder in pitching. A second report. *Am J Sports Med* 1984;12:218-220.
26. Rojas IL, Provencher MT, Bhatia S, et al. Biceps activity during windmill softball pitching: Injury implications and comparison with overhand throwing. *Am J Sports Med* 2009;37:558-565.
27. Kido T, Itoi E, Konno N, Sano A, Urayama M, Sato K. The depressor function of biceps on the head of the humerus in shoulders with tears of the rotator cuff. *J Bone Joint Surg Br* 2000;82:416-419.
28. Rowe CR. *The shoulder*. New York: Churchill Livingstone, 1988.
29. Warren RF. Lesions of the long head of the biceps tendon. *Instr Course Lect* 1985;34:204-209.

30. Bennett WF. Subscapularis, medial, and lateral head coracohumeral ligament insertion anatomy. Arthroscopic appearance and incidence of "hidden" rotator interval lesions. *Arthroscopy* 2001;17:173-180.
31. Walch G, Nove-Josserand L, Boileau P, Levigne C. Subluxations and dislocations of the tendon of the long head of the biceps. *J Shoulder Elbow Surg* 1998;7:100-108.
32. Lafosse L, Reiland Y, Baier GP, Toussaint B, Jost B. Anterior and posterior instability of the long head of the biceps tendon in rotator cuff tears: A new classification based on arthroscopic observations. *Arthroscopy* 2007;23:73-80.
33. Bennett WF. Arthroscopic repair of isolated subscapularis tears: A prospective cohort with 2- to 4-year follow-up. *Arthroscopy* 2003;19:131-143.
34. Braun S, Horan MP, Elser F, Millett PJ. Lesions of the biceps pulley. *Am J Sports Med*. 2011 Feb 18. [Epub ahead of print.]
35. Gerber C, Sebesta A. Impingement of the deep surface of the subscapularis tendon and the reflection pulley on the anterosuperior glenoid rim: A preliminary report. *J Shoulder Elbow Surg* 2000;9:483-490.
36. Gerber C, Terrier F, Zehnder R, Ganz R. The subcoracoid space. An anatomic study. *Clin Orthop Relat Res* 1987;132-138.
37. Giaroli EL, Major NM, Lemley DE, Lee J. Coracohumeral interval imaging in subcoracoid impingement syndrome on MRI. *AJR Am J Roentgenol* 2006;186:242-246.
38. Snyder SJ, Karzel RP, Del Pizzo W, Ferkel RD, Friedman MJ. SLAP lesions of the shoulder. *Arthroscopy* 1990;6:274-279.
39. Maffett MW, Gartsman GM, Moseley B. Superior labrum-biceps tendon complex lesions of the shoulder. *Am J Sports Med* 1995;23:93-98.
40. Gobezie R, Zurakowski D, Lavery K, Millett PJ, Cole BJ, Warner JJ. Analysis of interobserver and intraobserver variability in the diagnosis and treatment of SLAP tears using the Snyder classification. *Am J Sports Med* 2008;36:1373-1379.
41. Lichtenberg S, Magosch P, Habermeyer P. Superior labrum-biceps anchor complex. *Orthopade* 2003;32:616-626 (in German).
42. Gartsman GM, Taverna E. The incidence of glenohumeral joint abnormalities associated with full-thickness, reparable rotator cuff tears. *Arthroscopy* 1997;13:450-455.
43. Miller C, Savoie FH. Glenohumeral abnormalities associated with full-thickness tears of the rotator cuff. *Orthop Rev* 1994; 23:159-162.
44. Snyder SJ, Banas MP, Karzel RP. An analysis of 140 injuries to the superior glenoid labrum. *J Shoulder Elbow Surg* 1995; 4:243-248.
45. Slatys P, Aalto K. Medial dislocation of the tendon of the long head of the biceps brachii. *Acta Orthop Scand* 1979;50:73-77.
46. Maier D, Jaeger M, Suedkamp NP, Koestler W. Stabilization of the long head of the biceps tendon in the context of early repair of traumatic subscapularis tendon tears. *J Bone Joint Surg Am* 2007;89:1763-1769.
47. Favorito PJ, Harding WG III, Heidt RS Jr. Complete arthroscopic examination of the long head of the biceps tendon. *Arthroscopy* 2001;17:430-432.
48. Burkhead WZ, Arcand MA, Zeman C, Habermeyer P, Walch G. The biceps tendon. In: Rockwood CA, Matsen FA, Wirth MA, Lippitt SB. *The shoulder*. Ed 3. Philadelphia: WB Saunders, 2004;1059-1119.
49. Neer CS II. Anterior acromioplasty for the chronic impingement syndrome in the shoulder: A preliminary report. *J Bone Joint Surg Am* 1972;54:41-50.
50. Gross R. Evaluation and management of extra-articular biceps pathology: What are we missing? Presented at the Fall Course of the Arthroscopy Association of North America 23rd Fall Meeting, Palm Desert, CA, December 2004.
51. Gross RM, McCarthy JA. Painful proximal biceps tendon. In: Barber FA, Fischer SP, eds. *Surgical techniques for the shoulder and elbow*. New York: Thieme Medical, 2003;89-92.
52. Ruotolo C, Nottage WM, Flatow EL, Gross RM, Fanton GS. Controversial topics in shoulder arthroscopy. *Arthroscopy* 2002;18:65-75.
53. Boileau P, Ahrens PM, Hatzidakis AM. Entrapment of the long head of the biceps tendon: The hourglass biceps—A cause of pain and locking of the shoulder. *J Shoulder Elbow Surg* 2004;13:249-257.
54. Barber A, Field LD, Ryu R. Biceps tendon and superior labrum injuries: Decision-marking. *J Bone Joint Surg Am* 2007;89:1844-1855.
55. Shank JR, Singleton SB, Hawkins J, Decker MJ, Torry MR. A comparison of supination and elbow flexion strength in patients with either proximal biceps release or tenodesis. Presented at the Meeting of the American Orthopaedic Society for Sports Medicine, Hershey, PA, July 2006.
56. Gill TJ, McIrvin E, Mair SD, Hawkins RJ. Results of biceps tenotomy for treatment of pathology of the long head of the biceps brachii. *J Shoulder Elbow Surg* 2001;10:247-249.
57. Frost A, Zafar MS, Maffulli N. Tenotomy versus tenodesis in the management of pathologic lesions of the tendon of the long head of the biceps brachii. *Am J Sports Med* 2008;37:828-833.
58. Mariani EM, Cofield RH, Askew LJ, Li GP, Chao EY. Rupture of the tendon of the long head of the biceps brachii. Surgical versus nonsurgical treatment. *Clin Orthop Relat Res* 1988:233-239.
59. Friedman DJ, Dunn JC, Higgins LD, Warner JJ. Proximal biceps tendon: Injuries and management. *Sports Med Arthrosc* 2008;16:162-169.
60. Koh KH, Ahn JH, Kim SM, Yoo JC. Treatment of biceps tendon lesions in the setting of rotator cuff tears: Prospective cohort study of tenotomy versus tenodesis. *Am J Sports Med* 2010;38:1584-1590.
61. Berlemann U, Bayley I. Tenodesis of the long head of biceps brachii in the painful shoulder: Improving results in the long term. *J Shoulder Elbow Surg* 1995;4:429-435.
62. Boileau P, Krishnan SG, Coste JS, Walch G. Arthroscopic biceps tenodesis: A new technique using bioabsorbable interference screw fixation. *Arthroscopy* 2002;18:1002-1012.
63. Gartsman GM, Hammerman SM. Arthroscopic biceps tenodesis: Operative technique. *Arthroscopy* 2000;16:550-552.
64. Romeo AA, Mazzocca AD, Tauro JC. Arthroscopic biceps tenodesis. *Arthroscopy* 2004;20:206-213.
65. Froimson AI, Oh I. Keyhole tenodesis of biceps origin at the shoulder. *Clin Orthop Relat Res* 1975:245-249.
66. Mazzocca AD, Noerdlinger M, Romeo AA. Mini open and subpectoral biceps tenodesis. *Oper Tech Sports Med* 2003;11: 24-31.
67. Sekiya LC, Elkousy HA, Rodosky MW. Arthroscopic biceps tenodesis using the percutaneous intra-articular transtendon technique. *Arthroscopy* 2003;19:1137-1141.
68. Verma NN, Drakos M, O'Brien SJ. Arthroscopic transfer of the long head biceps to the conjoint tendon. *Arthroscopy* 2005;21: 764.e1-764.e5. Available online at www.arthroscopyjournal.org.
69. Castagna A, Mouhsine E, Conti M, et al. Chondral print on humeral head: An indirect sign of long head biceps tendon instability. *Knee Surg Sports Traumatol Arthrosc* 2007;15: 645-648.
70. Mazzocca AD, Bicos J, Santangelo S, Romeo AA, Arciero RA. The biomechanical evaluation of four fixation techniques for proximal biceps tenodesis. *Arthroscopy* 2005;21:1296-1306.
71. Ozalay M, Akpınar S, Karaeminogullari O, et al. Mechanical strength of four different biceps tenodesis techniques. *Arthroscopy* 2005;21:992-998.

72. Richards DP, Burkhart SS. A biomechanical analysis of two biceps tenodesis fixation techniques. *Arthroscopy* 2005;21:861-866.
73. Millett PJ, Sanders B, Gobezie R, Braun S, Warner JJ. Interference screw vs. suture anchor fixation for open subpectoral biceps tenodesis: Does it matter? *BMC Musculoskelet Disord* 2008;9:121.
74. Castagna A, Conti M, Mouhsine E, Bungaro P, Garofalo R. Arthroscopic biceps tendon tenodesis: The anchorage technical note. *Knee Surg Sports Traumatol Arthrosc* 2006;14:581-585.
75. Crenshaw AH, Kilgore WE. Surgical treatment of bicipital tenosynovitis. *J Bone Joint Surg Am* 1966;48:1496-1502.
76. Post M, Benca P. Primary tendinitis of the long head of the biceps. *Clin Orthop Relat Res* 1989;117-125.
77. Mazzocca AD, Cote MP, Arciero CL, Romeo AA, Arciero RA. Clinical outcomes following subpectoral biceps tenodesis with an interference screw. *Am J Sports Med* 2008;36:1922-1929.
78. Becker DA, Cofield RH. Tenodesis of the long head of the biceps brachii for chronic bicipital tendinitis. Long-term results. *J Bone Joint Surg Am* 1989;71:376-381.
79. Nho SJ, Reiff SN, Verma NN, Slabaugh MA, Mazzocca AD, Romeo AA. Complications associated with subpectoral biceps tenodesis: Low rates of incidence following surgery. *J Shoulder Elbow Surg* 2010;19:764-768.
80. Bennett WF. Arthroscopic bicipital sheath repair: Two-year follow-up with pulley lesions. *Arthroscopy* 2004;20:964-973.
81. Abbot AE, Li X, Busconi BD. Arthroscopic treatment of concomitant superior labral anterior posterior (SLAP) lesions and rotator cuff tears in patients over the age of 45 years. *Am J Sports Med* 2009;37:1358-1362.
82. Boileau P, Parratte S, Chuinard C, Roussanne Y, Shia D, Bicknell R. Arthroscopic treatment of isolated type II SLAP lesions: Biceps tenodesis as an alternative to reinsertion. *Am J Sports Med* 2009;37:929-936.