

Instability and Degenerative Arthritis of the Sternoclavicular Joint

A Current Concepts Review

Frank Martetschläger,^{*†} MD, Ryan J. Warth,^{*} MD, and Peter J. Millett,^{*‡§} MD, MSc
Investigation performed at the Steadman Philippon Research Institute, Vail, Colorado

Background: Injuries to the sternoclavicular (SC) joint typically occur with high-energy mechanisms such as those obtained in automobile accidents or contact sports. Many disorders of the SC joint can be treated nonoperatively. However, surgical treatment may be indicated for locked posterior dislocations; symptomatic, chronic instability; or persistent, painful osteoarthritis that fails nonoperative therapy.

Purpose: To provide an updated review on the current diagnosis and management of instability and degenerative arthritis of the SC joint.

Study Design: Current concepts review.

Methods: A preliminary PubMed database search using the terms *sternoclavicular instability, dislocation, arthritis, resection, and stabilization* was performed in August 2012. All anatomic and biomechanical studies, review articles, case reports, case series, and technique papers that were relevant to the topic were included.

Results: The search identified 929 articles, 321 of which, after screening of the titles and abstracts, were considered potentially relevant to this study. Of the 321 articles, 30 were anatomic or imaging studies, 2 were biomechanical studies, 69 were review papers, 189 were case series or reports, and 31 were technique papers. The majority of these studies were classified as evidence level 4, with a few scattered level 3 studies. Because the level of evidence obtained from this search was not adequate for systematic review (or meta-analysis), a current concepts review of the diagnosis and management of SC joint instability and degenerative arthritis is presented.

Conclusion: Injuries to the SC joint are uncommon. Recognition and classification of these injuries are critical to proper management, thus minimizing potential long-term sequelae such as posttraumatic arthritis and recurrent instability. Although nonoperative therapy is the modality of choice in anterior dislocations, posterior dislocations require special attention because of the presence of vulnerable posterior hilar structures. Surgical management of chronic instability and degenerative arthritis of the SC joint includes resection arthroplasty of the medial clavicle with or without reconstruction of the sternoclavicular ligaments with graft material. Although resection is typically performed open, an arthroscopic technique is described that theoretically decreases operating and recovery times while also decreasing the risk of iatrogenic injury. Currently, when reconstruction is needed for stability, a figure-of-8 graft reconstruction is the recommended method based on biomechanical data and small clinical series.

Keywords: shoulder; sternoclavicular; instability; arthritis; current concepts; review

Injuries to the sternoclavicular (SC) joint are uncommon given the large energy vector required to disrupt its ligamentous stabilizers.^{21,23} In fact, it is one of the least commonly disrupted joints in the body. Because of the high-energy mechanism required to violate this articulation, the presence of concomitant injuries is not uncommon and may lead to missed diagnoses.^{10,23,30} Although SC joint injuries account for only 3% of all shoulder girdle injuries and 1% of all dislocations,^{21,29} consequences of such an injury can be devastating because of the close proximity of cardiopulmonary structures, especially in posterior

dislocations. Therefore, it is critically important for the practitioner to conduct a full survey of the patient to establish priorities for treatment in the acute setting.

It has been well-documented that long-term sequelae after an acute dislocation treated nonoperatively may result in painful degenerative changes within the SC joint over time.^{13,50} Thus, patients may present years after the initial injury with painful arthritis of the SC joint, seeking a surgical solution.

Numerous techniques have been described for the treatment of the unstable or degenerative SC joint. In general, SC joint instability is treated by stabilization procedures with suture anchors,^{1,27} plates,¹⁷ or tendon grafts.^{3,4,8,9,18,22,24,36} Arthritis of the SC joint is typically treated with open excision of the medial clavicle,^{29,31,33} although newer arthroscopic techniques are available.^{40,44} However,

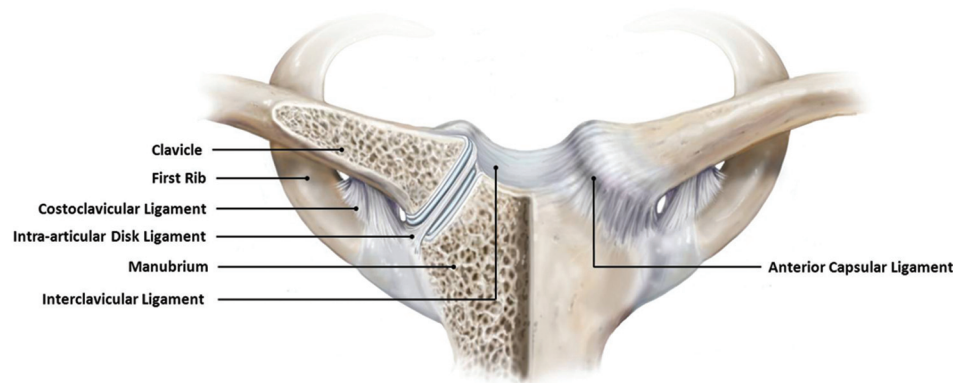


Figure 1. Osseoligamentous anatomy of the sternoclavicular joint.

because these injuries are rare and prior clinical studies have only reported on small numbers of injuries, there still does not exist an accepted standard for surgical treatment.

The purpose of this article is to provide an updated review on the diagnosis and management of instability and degenerative arthritis of the SC joint.

MATERIALS AND METHODS

In August 2012, we conducted a preliminary search of the PubMed database for the terms *sternoclavicular instability, dislocation, arthritis, resection, and stabilization*. A single reviewer (R.J.W.) screened the titles and abstracts for relevance. All anatomic and biomechanical studies, review articles, case reports, case series, and technique papers that were relevant to the topic were included.

The preliminary PubMed search identified a total of 929 articles, 321 of which, after screening of the titles and abstracts, were considered potentially relevant to this topic. Of the 321 articles, 30 were anatomic or imaging studies, 2 were biomechanical studies, 69 were review papers, 189 were case series or reports, and 31 were technique papers. The majority of these studies were classified as evidence level 4, with a few scattered level 3 studies. Because the level of evidence obtained from this search was not adequate for systematic review (or meta-analysis), a current concepts review of the management of SC joint instability and arthritis is presented.

ANATOMIC AND BIOMECHANICAL CHARACTERISTICS

The clavicle has a unique developmental process. Although it is the first long bone to ossify in the womb during the fifth gestational week, its physis is the last to close—at nearly 25 years of age. However, union may not occur until 31 years of age in some individuals.^{23,26,48} As such, many SC joint dislocations in younger patients may be the result of injury to a nonunited epiphysis rather than ligamentous disruption.^{14,26,48,49}

The SC joint is a diarthrodial joint and represents the only true articulation between the clavicle and the axial skeleton (Figure 1). The articular surfaces of the SC joint are covered in hyaline cartilage with an interposed fibrocartilaginous disk and are highly incongruent with respect to each other. The large articular surface of the clavicle is in the shape of a “saddle” (convex in the anteroposterior [AP] plane, concave in the vertical plane), whereas the smaller articular surface of the manubrium is strictly convex. Because only half of the medial clavicle articulates with the sternum, this configuration renders the joint highly unstable and it therefore must rely on soft tissue and ligamentous attachments to maintain stability.^{23,32}

The ligaments surrounding the joint that are involved in stability include the capsular ligament, the intra-articular disk ligament, the interclavicular ligament, and the costoclavicular ligament.

The capsular ligament is represented by discrete thickenings of the joint capsule and is composed of anterior and posterior segments. It is hypothesized that the posterior capsular ligament is much stronger than its anterior

§Address correspondence to Peter J. Millett, MD, MSc, Center for Outcomes-based Orthopaedic Research, Steadman Philippon Research Institute, 181 West Meadow Drive, Suite 1000, Vail, CO 81657 (e-mail: drmillett@thesteadmanclinic.com).

*Steadman Philippon Research Institute, Vail, Colorado.

†Department for Orthopaedic Sports Medicine, University Hospital Rechts der Isar, Munich Technical University, Munich, Germany.

‡Steadman Clinic, Vail, Colorado.

One or more of the authors has declared the following potential conflict of interest or source of funding: This research was supported by the Steadman Philippon Research Institute. The Institute receives research support from the following entities: Smith & Nephew Endoscopy Inc; Arthrex Inc; Siemens Medical Solutions USA Inc; Ossur Americas Inc; and Opedix Inc. This work was not supported directly by outside funding or grants. P.J.M. has received from Arthrex something of value (exceeding the equivalent of US\$500) not related to this manuscript; he is a consultant and receives payments from Arthrex and has stock options in Game Ready. F.M. has received from Arthrex something of value (exceeding the equivalent of US\$500) not related to this manuscript or research; his position was supported by Arthrex. R.J.W., his immediate family, and any research foundations with which he is affiliated have not received any financial payments or other benefits from any commercial entity related to the subject of this article.

counterpart, resisting superior translation of the medial clavicle as a result of axial forces on the distal clavicle.^{5,23,32}

The intra-articular disk ligament is a very dense, fibrous structure that arises from the chondral junction of the first rib and passes through the SC joint, creating 2 separate joint spaces. Its attachments lie on both the superior and posterior aspects of the medial clavicle, blending with the capsular ligament and resisting medial displacement with compression.^{23,32}

The interclavicular ligament is a thick, fibrous band stretching between, and intercalating with, the superomedial fibers of each SC joint capsule. Its central portion attaches to the superior margin of the sternum, and its main function is to resist superior migration of the medial clavicle resulting from gravitational pull on the shoulder girdle and distal clavicle.^{23,32}

The costoclavicular ligament (also known as the rhomboid ligament) is the strongest of the SC ligaments and consists of anterior and posterior fasciculi with an interposed bursa. Its short, strong segments have a "twisted" appearance and span from the inferior margin of the medial clavicle to the synchondral junction between the manubrium and first rib.^{23,32} Since the anterior and posterior fasciculi cross one another, stability is achieved during rotation and elevation of the distal clavicle. The anterior fibers resist superior rotation and lateral displacement of the clavicle while the posterior fibers resist inferior rotation and medial displacement.^{23,32}

Range of motion around the SC joint is extensive: It is nearly freely movable in all planes. The joint is capable of 35° of elevation, 35° of AP motion, and 50° of rotation around its long axis.^{23,32}

EPIDEMIOLOGICAL CHARACTERISTICS

Injuries to the SC joint are rare, accounting for less than 3% of all shoulder girdle injuries.^{21,29} They generally occur in active, young male patients and result from high-energy trauma such as automobile accidents or contact sports.^{13,49} Posterior dislocations are much less common than anterior dislocations^{23,48}; however, recognition of a posterior dislocation is often critical for patient survival due to the proximity of vital structures posterior to the medial clavicle.

Primary degenerative arthritis of the SC joint is common after capsular or ligamentous injuries.^{16,28} Moderate to severe changes of the SC joint have been found in 50% of individuals aged over 60 years in a postmortem analysis; however, it is unknown whether these changes are post-traumatic in nature or the result of aging.²⁵ Postmenopausal women, patients with chronic instability, and manual laborers are at a higher risk for development of degenerative arthritis of the SC joint.^{16,23,28}

MECHANISM OF INJURY

Because of the strong ligamentous stabilizers of the SC joint, a large energy vector is required to disrupt this articulation.

Although spontaneous subluxations have been reported,³⁴ the most common causes of SC joint dislocation are motor vehicle accidents and participation in contact sports.^{13,49} Both direct and indirect forces can disrupt the SC joint.^{23,49} A direct force applied directly onto the surface of the medial clavicle can force the clavicle posteriorly into the mediastinum. Numerous mechanisms of injury can result in this posteriorly directed force vector; however, this injury is relatively uncommon. More commonly, injury to the SC joint can occur indirectly as a blow to the anterolateral or posterolateral side of the shoulder girdle, resulting in anterior and posterior SC joint dislocations, respectively.^{23,49}

CLASSIFICATION

Instability of the SC joint can be classified by direction (anterior or posterior), cause (traumatic or atraumatic), severity (sprain, subluxation or dislocation), and onset (acute or chronic).^{23,49}

In 1967, Allman² classified SC joint injuries based on the degree of ligamentous disruption. Type 1 describes a simple sprain of the SC ligaments and capsule without subluxation or dislocation. Type 2 injuries involve a disruption of the SC ligaments and capsule and result in subluxation of the medial clavicle without dislocation. Type 3 injuries entail a rupture of all supporting ligaments with complete anterior or posterior dislocation.²

HISTORY AND PHYSICAL EXAMINATION

As mentioned, injuries to the SC joint typically involve high-energy mechanisms. Therefore, SC joint injuries are often missed because of the presence of other, more dramatic injuries.^{10,30} In seriously injured, narcotized, and ventilated patients, a thorough secondary evaluation of the alert patient after initial stabilization is mandatory in order to recognize these injuries. Furthermore, acute posterior dislocations should be regarded as an emergency since up to 30% of patients who sustain such dislocations develop mediastinal compromise.⁶ Venous congestion in the neck or ipsilateral arm, dysphagia, cough, hoarseness, or a feeling of choking suggests superior mediastinal obstruction and therefore a potentially life-threatening emergency.^{6,10,11,20,21,30,47,49}

Patients with acute trauma typically present with pain over the SC joint and clavicle in the presence of a deformity. Inspection and palpation of Allman type 2 and 3 injuries may reveal a prominence of the medial clavicle in anterior dislocations and a bump lateral to the sternum in posterior dislocations. A thorough examination of the entire clavicle is mandatory to rule out concomitant acromioclavicular dislocations ("floating clavicle") and clavicular fractures.^{15,35,41} In young adults, a Salter-Harris type 1 or 2 physeal lesion should also be considered since these injuries may mimic SC dislocation ("pseudodislocation").¹⁴ Patients with Allman type 2 and 3 injuries typically complain of severe anterior chest and shoulder pain, which is exacerbated by arm movement or assuming a supine position.²³

Patients with symptomatic osteoarthritis of the SC joint may present with swelling of the joint with or without a history of trauma. The physical examination typically reveals pain during arm movement that is often accompanied by localized crepitus. The push-down test (applying a posteriorly directed force on the medial clavicle), the cross-shoulder sign, and resisted arm abduction are clinical maneuvers that reliably reproduce symptoms.²³ An osteophytic prominence may be palpable over the medial clavicle that may be either bilateral or asymmetric; bilateral involvement typically suggests an atraumatic origin.

IMAGING

Standard AP radiographs should be obtained in patients with traumatic injuries to the SC joint; however, good visualization is often difficult because of overlapping structures (vertebrae and ribs). The “serendipity view,” described by Wirth and Rockwood,⁴⁹ is an oblique view of the SC joint that allows visualization of both clavicles for comparative purposes. To obtain this view, the x-ray beam is centered on the SC joint and tilted 40° in the cephalad-oblique direction.⁴⁹ These films are helpful for the diagnosis of dislocations and are capable of showing osteoarthritic changes of the SC joints.

Computed tomography (CT) scanning is preferred and often indicated in the trauma patient to search for associated mediastinal injuries, to identify occult medial clavicular fractures, and to determine the degree of dislocation relative to the contralateral clavicle.^{23,45} For additional clarification during the diagnostic process, multiplanar CT scans may be obtained showing the structures of interest without superposition of surrounding tissues. By obtaining such scans, one can more precisely distinguish between medial clavicle fractures, epiphyseal lesions, and SC joint dislocations. When surgical repair is being considered, it is generally recommended to obtain a CT angiogram to evaluate the proximity of the vascular structures. In the special case of a posterior dislocation, a magnetic resonance image or CT angiogram should certainly be obtained to identify concomitant retrosternal injuries such as associated vascular lesions.^{10,23}

NONOPERATIVE TREATMENT

Type 1 and 2 SC Dislocation

The mildly sprained, painful, yet stable SC joint (Allman type 1) is best treated with ice within 48 hours of injury followed by immobilization in a sling for less than a week along with anti-inflammatory pain medications. After this period of immobilization, the patient can resume activities of daily living.²³

Moderate sprains of the SC joint (Allman type 2) typically involve subluxation (anteriorly and posteriorly) without dislocation. This injury is also best treated with ice within the first 48 hours, but immobilization and stabilization with a figure-of-8 dressing and/or a sling should be advocated for approximately 4 to 6 weeks to enhance

healing of the disrupted ligaments and to protect the joint from further injury.²³

Type 3 Dislocation

An attempt at closed reduction is typically performed for the anteriorly or posteriorly dislocated SC joint (Allman type 3).^{23,28,51} In the case of an anterior dislocation, this is accomplished by placing the patient in a supine position with conscious sedation, placing a 3- to 4-inch-thick pad between the scapulae, and applying gentle, posterolaterally directed pressure on the medial edge of the clavicle.

For closed reduction of posterior dislocations, general anesthesia is usually required because of the excessive pain and muscle spasm involved. The patient is positioned in the supine position with a pad between the scapulae to retract the shoulders. The shoulder is abducted 90° with moderate traction and is slowly brought into extension. If this fails, it may be necessary to manually grab the medial clavicle with the fingers (or towel clip) to maneuver it from behind the manubrium.²³

A cardiothoracic surgeon should be consulted before reduction of posterior dislocations in the event that a vascular injury requiring thoracotomy becomes necessary during surgical reduction.^{10,23} As an imaging aid, an intraoperative O-arm CT scanner can be used if available to directly visualize hilar structures during closed reduction of a posteriorly directed SC joint dislocation.³⁹

After reduction, the shoulder should be immobilized for approximately 6 weeks to promote healing of the disrupted SC ligaments. In contrast to anterior dislocations, which tend to redislocate, posterior dislocations are usually stable after initial reduction. It is generally accepted that contact sports and high-risk activities should be prohibited for at least 3 to 4 months to avoid recurrent injury and chronic instability.

Osteoarthritis

Nonoperative treatment of SC joint osteoarthritis includes rest, local cryotherapy, activity modification, anti-inflammatory medications, and, eventually, intra-articular corticosteroid injections. Physical therapy is typically included after an acute injury.

OPERATIVE MANAGEMENT—INDICATIONS AND OPTIONS

Although the initial reduction of an anterior dislocation is usually successful, disruption of ligamentous structures often allows for redislocation after pressure is released.²³ After conducting a survey of orthopaedic surgeons, Van Tongel et al⁴⁶ concluded that 52% of surgeons first attempted closed reduction. However, 80% of the same practitioners reported that the reduction was not maintained in more than half of the cases. Recurrent subluxation and/or dislocation may lead to chronic, painful instability, and, finally, surgical treatment.

Further indications for surgical management include failed closed reduction or chronic recurrence of posterior dislocations, since this may result in severe complications such as neurovascular compromise and erosion of the medial clavicle into posteriorly situated hilar structures.

Posteriorly directed physal injuries in young patients are very difficult to reduce by closed means without general anesthesia (likely because of muscle spasm). In these cases, manipulation under anesthesia or primary open reduction and stabilization are typically indicated.^{14,23} In patients with symptomatic SC joint osteoarthritis, failed nonoperative treatment is usually an indication for surgical management.³¹

SC Joint Stabilization

Numerous techniques have been proposed for reconstruction of the unstable SC joint. Previously, stabilization was performed with wires or pins; however, because of reported lethal complications,^{12,37} these techniques are no longer recommended. Reconstruction with sutures either through drill holes or cerclaged around the medial clavicle has been performed with marginal biomechanical results.⁴² More recently, reconstruction with graft material has become more popular given its safety and theoretically improved biomechanical properties compared with older techniques. Rockwood et al³³ performed medial resection arthroplasty with an intramedullary construct incorporating the capsular ligament to enhance stability. The subclavius tendon has also been used to reconstruct the costoclavicular ligaments.^{8,28} Figure-of-8 reconstructions, in which semitendinosus,^{9,22,36} palmaris longus, gracilis,^{18,24,36} or, occasionally, sternocleidomastoid^{3,4} tendon grafts are shuttled through the sternum and medial clavicle in a figure-of-8 manner, have been popular. Satisfactory clinical outcomes have been reported for each of the graft reconstruction techniques^{3,4,8,9,18,21,22,24,36}; however, collections of low-level case series and case reports are inadequate to determine differences in clinical outcomes between these different techniques.

Although satisfactory preliminary outcomes have been reported for each graft reconstruction technique, figure-of-8 reconstruction with tendon graft appears to be biomechanically superior and may result in improved long-term outcomes. Specifically, Spencer and Kuhn³⁸ investigated the mechanical strength of 3 different techniques including subclavius tendon reconstruction, intramedullary ligament reconstruction, and semitendinosus figure-of-8 reconstruction of the SC joint. In this study, the stiffness of each reconstruction technique was first compared with the stiffness of the native ligaments in the anterior and posterior directions. The intramedullary, subclavius, and figure-of-8 reconstructions resulted in a decrease in stiffness (compared with the native ligaments) of 70.1%, 56.9%, and 36.9%, respectively, in the anterior direction. In the posterior direction, the intramedullary, subclavius, and figure-of-8 reconstructions resulted in a decrease in stiffness of 74.4%, 82.3%, and 3.8%, respectively. While the study was underpowered to detect a difference in stiffness of less than 20%, these results demonstrate the significantly

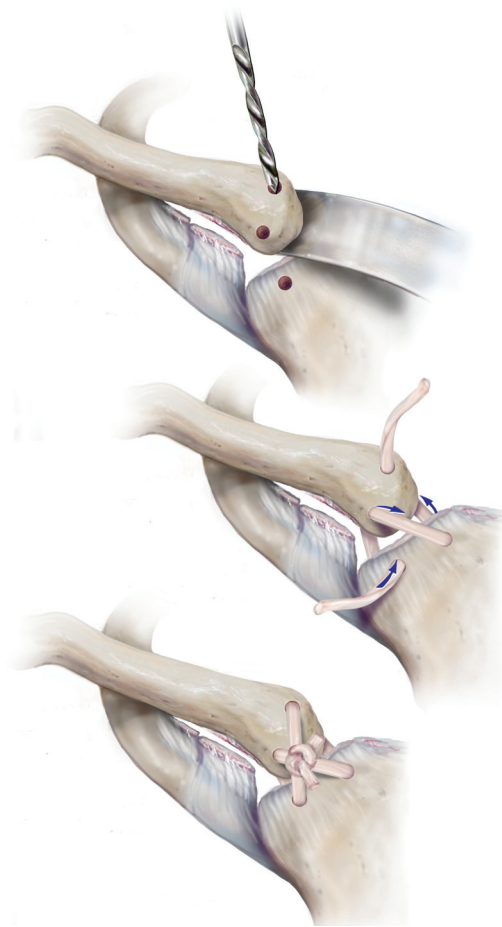


Figure 2. Illustration of the figure-of-8 graft reconstruction technique.

improved mechanical strength of the figure-of-8 construct in both the anterior and posterior directions. The figure-of-8 construct also resulted in a peak load nearly 3 times that of both the intramedullary and subclavius tendon reconstructions, where peak load was defined as the force required to displace the medial clavicle by 100% of its sagittal width in either the anterior or the posterior direction. This study therefore provides evidence for the biomechanical superiority of the figure-of-8 reconstruction technique compared with other common methods of surgical stabilization. Figure-of-8 tendon graft reconstruction has been shown to be safe while also providing effective preliminary results.^{9,18,22,24,36} Because of its biomechanical advantages and satisfactory preliminary outcomes, figure-of-8 reconstruction of the unstable SC joint is currently in favor. The technique for this procedure is described in the following section and illustrated in Figure 2.

Technique for Figure-of-8 Reconstruction of the SC Joint With Hamstring Tendons

The procedure is performed with the patient in the supine position. The affected arm is draped free such that the SC

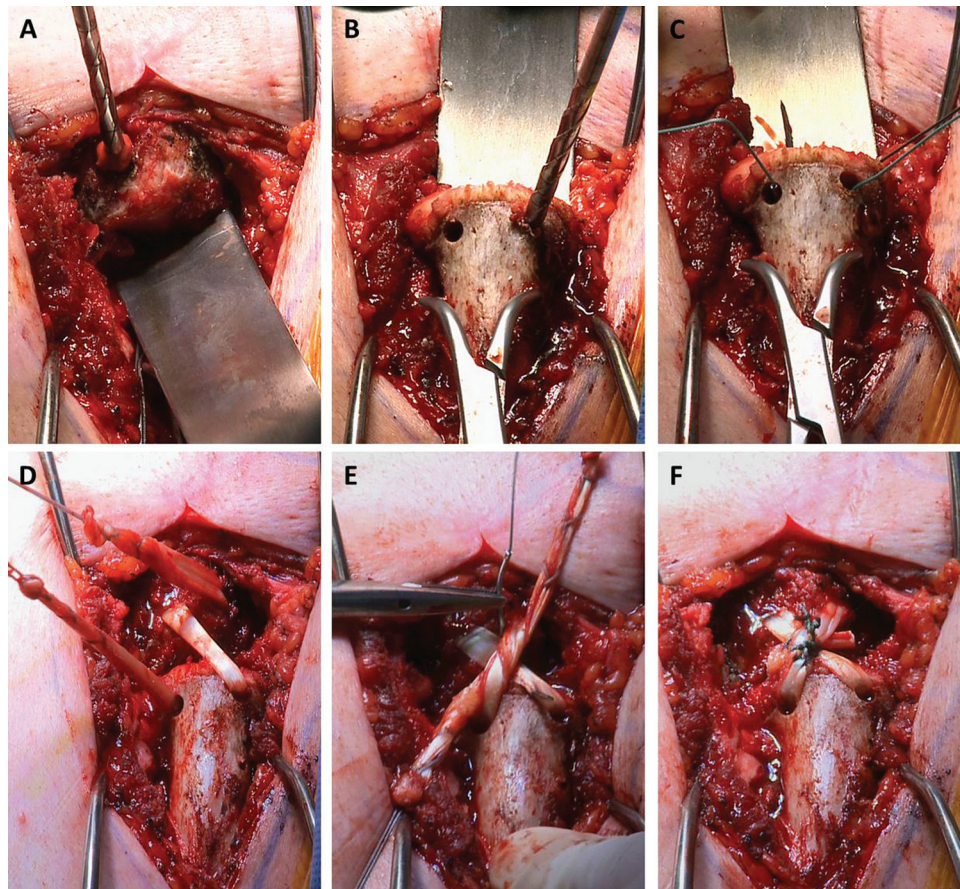


Figure 3. (A) Bone tunnels in the sternum are created. (B) Two 4-mm bone tunnels are created in the medial clavicle. (C) Sutures are passed through the tunnels for graft shuttling. (D) The graft is shuttled in a figure-of-8 manner. (E) The graft ends are tied together and subsequently secured with sutures. (F) The free ends of the graft are removed with a scalpel.

joint can be examined dynamically during the procedure. Before the incision, bony landmarks are marked on the skin. A skin incision of approximately 10 cm is made from the medial clavicle over the SC joint and the sternum. The SC joint capsule is exposed and opened via electrocautery, and the periosteum is mobilized with an elevator. A thorough and complete circumferential capsular release is performed such that the medial clavicle can be mobilized. The tendinous attachment of the sternocleidomastoid muscle is also elevated at this point with the periosteum as a continuous soft tissue sleeve. The disrupted intra-articular disk is then carefully removed with a scalpel.

The sternum and clavicle must be exposed sufficiently enough such that a malleable retractor can be placed posteriorly, thereby protecting underlying vascular structures while bone tunnels are drilled. The gracilis or semitendinosus tendon autograft is then harvested in a standard manner and prepared with sutures. The graft must be harvested and measured such that appropriately sized bone tunnels may be drilled (tunnels are typically 4 mm in diameter). Two bone tunnels are drilled medial to the sternal articular facet on the manubrium and are drilled over guide wires to ensure they are placed properly (Figure

3A). Two 4-mm bone tunnels are created on the proximal clavicle at the level of the condylar flare (Figure 3B). Sutures are then passed through the bone tunnels to shuttle the graft (Figure 3C). Care must be taken to place the tunnels appropriately to prevent inadvertent fracture either into the other tunnel or through the cortex. In younger patients with an open medial clavicular physis, the clavicular tunnels should be placed more laterally in the clavicle to avoid the growth plate. The graft is then passed in a figure-of-8 fashion such that the parallel limbs are posterior and the cruciate limbs are anterior (Figure 3D). The joint is then reduced and the 2 ends of the graft are knotted together and secured with 4 permanent No. 2 sutures (Figure 3E). The sutures and the free ends of the graft are then cut (Figure 3F). Stability of the SC joint can then be tested under both direct visualization and dynamic evaluation. The joint capsule is meticulously repaired with figure-of-8 sutures, and the skin is closed in a standard manner.

Medial Clavicle Resection

In patients with symptomatic osteoarthritis of the SC joint, resection arthroplasty of the medial clavicle with

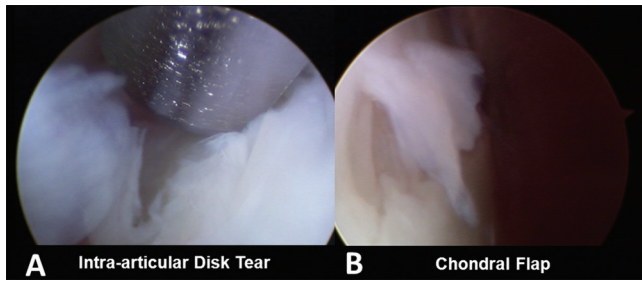


Figure 4. Arthroscopic visualization of (A) a torn intra-articular disk and (B) a chondral flap.

preservation of the costoclavicular ligament is often warranted after nonoperative therapy has failed.^{31,33,40}

The open technique typically involves ligation of the interclavicular ligament and subperiosteal dissection to expose the medial clavicle followed by removal of no more than 1.5 cm of medial clavicle to prevent recurrent instability.^{7,33}

An arthroscopic technique for medial clavicle excision and debridement of a degenerative SC joint has been described⁴⁰ and recently performed by the senior author (P.J.M.). Theoretical advantages of this technique include avoidance of damage to the costoclavicular or other capsular ligaments, improved visualization, avoidance of nearby structures, and shortened recovery times. However, certain risks are important to recognize, including capsular perforation and/or damage to nearby neurovascular structures. As such, the procedure is best reserved for experienced, skilled shoulder arthroscopists and should not be performed on an outpatient basis or within surgery centers. This newer technique is described in the following section.

Arthroscopic Technique for Medial Clavicle Excision

The procedure is performed with the patient in the supine position. The affected arm is prepared and draped in the usual sterile fashion. A spinal needle is used to localize the SC joint, which is then insufflated with saline. A 5-mm skin incision is carried through the skin and subcutaneous tissues, and a trocar is placed bluntly into the SC joint. Next, diagnostic arthroscopy is performed, and an accessory superior portal is created under direct arthroscopic vision. The SC joint is examined for stability under direct and arthroscopic visualization. At this point, a chondroplasty is performed and approximately 8 mm of the medial clavicle is excised using a 4.0-mm high-speed bur and shaver. In the presence of a torn intra-articular disk and loose bodies, the loose bodies are removed and the intra-articular disk is morcellized with an arthroscopic biter and radiofrequency wand and subsequently removed with a high-speed, full radius resector similar to a meniscectomy procedure in the knee (Figure 4A). Next, the sternal facet of the SC joint is visualized and debrided where there is evidence of chondral wear (Figure 4B). Care is taken to preserve the posterior, superior, and anterior capsule of the SC joint along with the attachment sites of the

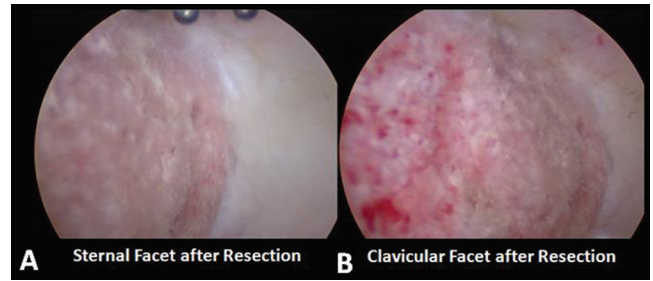


Figure 5. Arthroscopic visualization of both (A) the sternal and (B) clavicular articular facets after resection.

sternocleidomastoid muscle. At this point, the SC joint is copiously lavaged. Finally, the resection is visualized from both portals to ensure its adequacy (Figure 5). A dynamic SC examination is performed to ensure there is no further contact between the resected clavicular stump and the sternum.

DISCUSSION AND OUTCOMES

Injuries of the SC joint leading to chronic instability and degenerative changes are rare, creating a paucity of surgical experience and literature on the topic.^{19,29,43} As such, the literature is riddled with small case series, case reports, and expert opinions. Although these studies are helpful, more clinical data, especially those contained in evidence level 1 or 2 studies, are sorely needed to help practitioners determine the most effective treatment modality for their patients. The authors understand that the evidence presented in this paper is primarily of level 3, 4, or 5; however, it is important to expand awareness of SC joint problems as these conditions are becoming more recognized in clinical practice.

The results of our preliminary literature search highlight the presence of many case reports and small case series dealing with SC joint arthritis and instability. Of the 321 relevant articles, 30 were English-language case series of 5 or more patients. Seventy-seven percent (23/30) of these case series dealt with SC dislocation, instability, or stabilization while only 23% (7/30) dealt with SC arthritis or resection. Further, all of these case series were either level 3 (few) or level 4 (many). After review of each relevant paper, it is puzzling that we still know relatively little about SC arthritis and instability given the volume of reported cases. This demonstrates the need for randomized controlled trials with regard to this topic. It is understood that because of the scarcity of SC joint disorders in clinical practice, it is nearly impossible to reasonably conduct such a study. Multicenter studies, however, can potentially bridge this persistent data gap.

SC Joint Stabilization Outcomes

Although the work of Spencer and Kuhn³⁸ confirms the biomechanical advantages of figure-of-8 tendon graft reconstruction, limited data exist regarding outcomes after the procedure in patients with acute or chronic instability

of the SC joint. Singer et al³⁶ documented the clinical outcomes in a group of active patients. In this study, 6 athletes with either anterior or posterior dislocations were followed for a mean of 22 months after anatomic reconstruction by use of the figure-of-8 technique with either semitendinosus or gracilis tendon autograft. The Disabilities of the Arm, Shoulder and Hand (DASH) score improved from 54.3 to 28.8, and all patients returned to full activity postoperatively, including contact sports.

Bae et al⁴ evaluated the outcomes after SC joint resection or figure-of-8 hamstring autograft reconstruction for SC joint instability in a series of 24 patients. Eighty-seven percent of the patients in their study reported physical limitations after a mean 55-month follow-up period. However, several different reconstruction techniques were used, and only 8 of 24 (33%) reconstructions used a figure-of-8 technique. Unfortunately, the authors did not stratify their results depending on the reconstruction method used except for the Simple Shoulder Test (SST) score, the mean of which was found to be 11.4 (a perfect score = 12) for figure-of-8 reconstruction.

Unpublished data from this institution show an improvement in subjective outcomes scores over preoperative levels in 5 patients (6 shoulders) who underwent SC joint reconstruction with gracilis tendon autograft using a figure-of-8 technique. In these patients, the American Shoulder and Elbow Surgeons (ASES), QuickDASH, and Single Assessment Numeric Evaluation (SANE) scores improved by 28, 14.1, and 11 points, respectively, over preoperative levels at 1-year follow-up (unpublished data; Steadman Philippon Research Institute, 2013).

To this point, the literature is dominated with small case series and case studies. Although clinical results for figure-of-8 reconstruction are generally positive in most of these studies, further research needs to be performed to more clearly define the clinical outcomes after figure-of-8 reconstruction compared with the other reconstruction methods previously mentioned.

Medial Clavicle Resection Outcomes

Resection arthroplasty of the degenerative SC joint has been shown by several authors to provide adequate pain relief and a return to normal function. Postoperative outcomes, as reported by Rockwood et al,³³ were excellent in most cases. In their study, a group of 8 patients with arthritis of the SC joint were treated with isolated resection arthroplasty without disruption of the costoclavicular ligaments in an effort to document their postoperative results. At an average follow-up of 5.7 years, 6 of 8 patients had complete pain relief while the remaining 2 reported minor discomfort during manual labor. All 8 patients were completely satisfied with the results.

In a study by Pingsmann et al,³¹ 8 women were treated with isolated resection arthroplasty for primary degenerative changes of the SC joint. At a mean follow-up of 31 months, 7 of the 8 patients reported significant pain relief and improved range of motion along with an increase in strength. Furthermore, all 8 patients were satisfied with the result both functionally and cosmetically. Thus,

resection of the medial clavicle can be an effective treatment in cases of chronic instability or posttraumatic degenerative arthritis of the SC joint.

First reported by Tavakkolizadeh et al,⁴⁰ arthroscopic medial clavicle resection has recently become attractive owing to its numerous perceived advantages such as improved visualization, minor damage to supporting structures, minimized risk to mediastinal structures, and shortened recovery times when performed by experienced hands. However, although short-term (<12 months) follow-up appears promising, there are no studies examining minimum 2-year outcomes after the procedure.

In some patients, SC joint pain exists in the absence of instability or osteoarthritis. One case report⁴⁴ found that isolated arthroscopic excision of the intra-articular disk was successful in treating such patients. However, level 1 or 2 studies need to be conducted to prove the efficacy of this procedure as a valid treatment modality for SC joint pain in the absence of instability or arthritis.

CONCLUSION

Injuries to the SC joint are uncommon. Recognition and classification of these injuries are critical to proper management, thus minimizing potential long-term sequelae such as posttraumatic arthritis and recurrent instability. Although nonoperative therapy is the modality of choice in anterior dislocations, posterior dislocations require special attention because of the presence of vulnerable posterior hilar structures. Surgical management of chronic instability and degenerative arthritis of the SC joint include resection arthroplasty of the medial clavicle with or without reconstruction of the sternoclavicular ligaments with graft material. Although resection is typically performed open, an arthroscopic technique is described that theoretically decreases operating and recovery times while also decreasing the risk of iatrogenic injury. Currently, when reconstruction is indicated for stability, a figure-of-8 tendon graft reconstruction is the recommended method based on biomechanical data and small clinical series.

REFERENCES

1. Abiddin Z, Sinopidis C, Grocock CJ, Yin Q, Frostick SP. Suture anchors for treatment of sternoclavicular joint instability. *J Shoulder Elbow Surg*. 2006;15(3):315-318.
2. Allman FL Jr. Fractures and ligamentous injuries of the clavicle and its articulation. *J Bone Joint Surg Am*. 1967;49(4):774-784.
3. Armstrong AL, Dias JJ. Reconstruction for instability of the sternoclavicular joint using the tendon of the sternocleidomastoid muscle. *J Bone Joint Surg Br*. 2008;90(5):610-613.
4. Bae DS, Kocher MS, Waters PM, Micheli LM, Griffey M, Dichtel L. Chronic recurrent anterior sternoclavicular joint instability: results of surgical management. *Pediatr Orthop*. 2006;26(1):71-74.
5. Bearn JG. Direct observations on the function of the capsule of the sternoclavicular joint in the clavicular support. *J Anat*. 1967;101:159-170.
6. Bicos J, Nicholson GP. Treatment and results of sternoclavicular joint injuries. *Clin Sports Med*. 2003;22(2):359-370.

7. Bisson LJ, Dauphin N, Marzo JM. A safe zone for resection of the medial end of the clavicle. *J Shoulder Elbow Surg.* 2003;12(6):592-594.
8. Burrows HJ. Tenodesis of subclavius in the treatment of recurrent dislocation of the sterno-clavicular joint. *J Bone Joint Surg Br.* 1951;33(2):240-243.
9. Castropil W, Ramadan LB, Bitar AC, Schor B, de Oliveira D'Elia C. Sternoclavicular dislocation—reconstruction with semitendinosus tendon autograft: a case report. *Knee Surg Sports Traumatol Arthrosc.* 2008;16(9):865-868.
10. Chaudhry FA, Killampalli VV, Chowdhry M, Holland P, Knebel RW. Posterior dislocation of the sternoclavicular joint in a young rugby player. *Acta Orthop Traumatol Turc.* 2011;45(5):376-378.
11. Chotai PN, Ebraheim NA. Posterior sternoclavicular dislocation presenting with upper-extremity deep vein thrombosis. *Orthopedics.* 2012;35(10):e1542-e1547.
12. Clark RL, Milgram JW, Yawn DH. Fatal aortic perforation and cardiac tamponade due to a Kirschner wire migrating from the right sternoclavicular joint. *South Med J.* 1974;67(3):316-318.
13. de Jong KP, Sukul DM. Anterior sternoclavicular dislocation: a long term follow-up study. *J Orthop Trauma.* 1990;4:420-423.
14. El Mekkaoui MJ, Sekkach N, Bazeli A, Faustin JM. Proximal clavicle physeal fracture-separation mimicking an anterior sterno-clavicular dislocation. *Orthop Traumatol Surg Res.* 2011;97(3):349-352.
15. Eni-Olotu DO, Hobbs NJ. Floating clavicle—simultaneous dislocation of both ends of the clavicle. *Injury.* 1997;28(4):319-320.
16. Eskola A, Vainionpää S, Vastamäki M, Slati P, Rokkanen P. Operation for old sternoclavicular dislocation: results in 12 cases. *J Bone Joint Surg Br.* 1989;71(1):63-65.
17. Franck WM, Jannasch O, Siassi M, Hennig FF. Balser plate stabilization: an alternate therapy for traumatic sternoclavicular instability. *J Shoulder Elbow Surg.* 2003;12(3):276-281.
18. Friedrich L, Afifi FK, Skarvan J, Friederich NF, Hirschmann MT. Combined gracilis tendon autograft reconstruction and discus repair of a chronic anterior-superior sternoclavicular joint dislocation. *Knee Surg Sports Traumatol Arthrosc.* 2012;20(1):1978-1982.
19. Glass ER, Thompson JD, Cole PA, Gause TM II, Altman GT. Treatment of sternoclavicular dislocations: a systematic review of 251 dislocations in 24 case series. *J Trauma.* 2011;70(5):1294-1298.
20. Groh GI, Wirth MA, Rockwood CA Jr. Treatment of traumatic posterior sternoclavicular dislocations. *J Shoulder Elbow Surg.* 2011;20(1):107-113.
21. Groh GI, Wirth MA. Management of traumatic sternoclavicular joint injuries. *J Am Acad Orthop Surg.* 2011;19(1):1-7.
22. Guan JJ, Wolf BR. Reconstruction for anterior sternoclavicular joint dislocation and instability. *J Shoulder Elbow Surg.* 2013;22(6):775-781.
23. Iannotti JP, Williams GR. *Disorders of the Shoulder: Diagnosis and Management.* Philadelphia, PA: Lippincott Williams & Wilkins; 1999:765-813.
24. Jesacher M, Singer G, Höllwarth ME, Eberl R. [Traumatic posterior dislocation of the sternoclavicular joint: a case report of joint stabilization with gracilis tendon graft]. *Unfallchirurg.* 2012;115(2):165-168.
25. Kier R, Wain SL, Apple J, Martinez S. Osteoarthritis of the sternoclavicular joint: radiographic features and pathologic correlation. *Invest Radiol.* 1986;21:227-233.
26. Koch MJ, Wells L. Proximal clavicle physeal fracture with posterior displacement: diagnosis, treatment, and prevention. *Orthopedics.* 2012;35(1):e108-111.
27. Lehmann W, Laskowski J, Grossterlinden L, Rueger JM. [Refixation of sternoclavicular luxation with a suture anchor system]. *Unfallchirurg.* 2010;113(5):418-421.
28. Lunseth PA, Chapman KW, Frankel VH. Surgical treatment of chronic dislocations of the sterno-clavicular joint. *J Bone Joint Surg Br.* 1975;57(2):193-196.
29. Panzica M, Zeichen J, Hankemeier S, et al. Long-term outcome after joint reconstruction or medial resection arthroplasty for anterior SCJ instability. *Arch Orthop Trauma Surg.* 2010;130:657-665.
30. Perron AD. Chest pain in athletes. *Clin Sports Med.* 2003;22:37-50.
31. Pingsmann A, Patsalis T, Michiels I. Resection arthroplasty of the sternoclavicular joint for the treatment of primary degenerative sternoclavicular arthritis. *J Bone Joint Surg Br.* 2002;84(4):513-517.
32. Renfree KJ, Wright KW. Anatomy and biomechanics of the acromioclavicular and sternoclavicular joints. *Clin Sports Med.* 2003;22:219-237.
33. Rockwood CA Jr, Groh GI, Wirth MA, Grassi FA. Resection arthroplasty of the sternoclavicular joint. *J Bone Joint Surg Am.* 1997;79(3):387-393.
34. Rockwood CA Jr, Odor JM. Spontaneous atraumatic anterior subluxation of the sternoclavicular joint. *J Bone Joint Surg Am.* 1989;71(9):1280-1288.
35. Sanders JO, Lyons FA, Rockwood CA Jr. Management of dislocations of both ends of the clavicle. *J Bone Joint Surg Am.* 1990;72(3):399-402.
36. Singer G, Ferlic P, Kraus T, Eberl R. Reconstruction of the sternoclavicular joint in active patients with the figure-of-eight technique using hamstrings. *J Shoulder Elbow Surg.* 2013;22(1):64-69.
37. Smolle-Juettner FM, Hofer PH, Pinter H, Friehs G, Szyszkowitz R. Intracardiac malpositioning of a sternoclavicular fixation wire. *J Orthop Trauma.* 1992;6(1):102-105.
38. Spencer EE, Kuhn JE. Biomechanical analysis of reconstructions for sternoclavicular joint instability. *J Bone Joint Surg Am.* 2004;86(1):98-105.
39. Sullivan JP, Warme BA, Wolf BR. Use of an O-arm intraoperative computed tomography scanner for closed reduction of posterior sternoclavicular dislocations. *J Shoulder Elbow Surg.* 2012;21(3):e17-20.
40. Tavakkolizadeh A, Hales PF, Janes GC. Arthroscopic excision of sternoclavicular joint. *Knee Surg Sports Traumatol Arthrosc.* 2009;17:405-408.
41. Thomas CB Jr, Friedman RJ. Ipsilateral sternoclavicular dislocation and clavicle fracture. *J Orthop Trauma.* 1989;3(4):355-357.
42. Thomas DP, Williams PR, Hoddinott HC. A "safe" surgical technique for stabilization of the sternoclavicular joint: a cadaveric and clinical study. *Ann R Coll Surg Engl.* 2000;82(6):432-435.
43. Thut D, Hergan D, Dukas A, Day M, Sherman OH. Sternoclavicular joint reconstruction: a systematic review. *Bull NYU Hosp Jt Dis.* 2011;69(2):128-135.
44. Tytherleigh-Strong GM, Getgood AJ, Griffiths DE. Arthroscopic intra-articular disk excision of the sternoclavicular joint. *Am J Sports Med.* 2012;40(5):1172-1175.
45. van Holsbeeck M, van Melkebeke J, Dequeker J, Pennes DR. Radiographic findings of spontaneous subluxations of the sternoclavicular joint. *Clin Rheumatol.* 1992;11(3):376-381.
46. van Tongel A, McRae S, Gilhen A, Leiter J, MacDonald P. Management of anterior sternoclavicular dislocation: a survey of orthopedic surgeons. *Acta Orthop Belg.* 2012;78(2):164-169.
47. Waters PM, Bae DS, Kadiyala RK. Short-term outcomes after surgical treatment of traumatic posterior sternoclavicular fracture dislocations in children and adolescents. *J Pediatr Orthop.* 2003;23(4):464-469.
48. Webb PA, Schuey JM. Epiphyseal union of the anterior iliac crest and medial clavicle in a modern multiracial sample of American males and females. *Am J Phys Anthropol.* 1985;68:457-466.
49. Wirth MA, Rockwood CA. Disorders of the sternoclavicular joint. In: *The Shoulder.* 4th ed. Rockwood CA Jr, Matsen FA III, Wirth MA, Lippitt SB, eds. Philadelphia, PA: Saunders; 2009:527-560.
50. Yang J, al-Etani H, Letts M. Diagnosis and treatment of posterior sternoclavicular joint dislocations in children. *Am J Orthop (Belle Mead NJ).* 1996;25(8):565-569.
51. Yeh GL, Williams GR Jr. Conservative management of sternoclavicular injuries. *Orthop Clin North Am.* 2000;31(2):189-203.