

Arthroscopic Management of Anterior, Posterior, and Multidirectional Shoulder Instability: Pearls and Pitfalls

Peter J. Millett, M.D., M.Sc., Philippe Clavert, M.D., and Jon J. P. Warner, M.D.

Arthroscopic treatment of the unstable shoulder has evolved rapidly and significantly in recent years. Better understanding of the pathoanatomy, advancements in technology, and improved surgical techniques have led to dramatic improvements in outcome. An arthroscopic approach includes significant advantages. Arthroscopy provides better identification of concomitant pathology, lower morbidity, less soft tissue dissection, maximal preservation of motion, shorter surgical time, and improved cosmesis. There is less pain, and many patients have an easier functional recovery, with greater returns in motion compared with traditional open techniques. Finally, some of the inherent risks of open procedures, such as postoperative subscapularis rupture, are virtually eliminated. Surgeons can now routinely expect results that are at least comparable, if not better than, those achieved with open techniques.

The purpose of this article is to summarize current approaches to the arthroscopic treatment of patients with shoulder instability, including the more complex posterior and multidirectional instability (MDI) patterns.

ANATOMY OF SHOULDER STABILITY

Because the goal of an arthroscopic stabilization is restoration of anatomy, a brief review of the relevant anatomy is included. The glenohumeral joint is inherently unstable, with the large humeral head articulat-

ing with the small and shallow glenoid. Stability depends on the soft tissues, which maintain stability while providing for a large range of motion. The osseous anatomy, capsuloligamentous structures, rotator cuff, scapular stabilizers, and biceps tendon play roles in providing stability.¹⁻³ Dynamic stability is provided by the rotator cuff and biceps tendons through a concavity compression effect of the glenoid within the glenoid socket.^{3,4} Static stability is provided by the bony anatomy and by the glenohumeral joint capsule and its ligaments.⁵

The rotator interval, which lies between the supraspinatus and subscapularis tendons, provides stability against inferior and posterior translations, particularly when the arm is adducted and externally rotated.² This is important in patients with MDI and posterior instability. Evidence suggests that deficiencies in the rotator interval contribute to instability in patients with excessive inferior or posterior translation.⁶

Articular version is particularly important in certain instability patterns such as posterior instability, in which excessive glenoid retroversion or glenoid hypoplasia can be a significant contributing factor. Significant bone loss (> 25%) on the glenoid, either developmental or acquired, represents a contraindication to an arthroscopic repair. This can be either from an acute fracture or chronic erosion or rarely from hypoplasia. Burkhart and DeBeer⁷ studied 194 patients who had undergone arthroscopic Bankart repair of the shoulder. In patients without bone defects (173 patients), they found a recurrence rate of 4%; in patients with significant bone defects, they found a recurrence rate of 67%. In the subset of patients who were contact athletes and had significant bone defects, the recurrence rate was 87%, whereas contact athletes without bone defects had a recurrence rate of only 6.5%. When

Address correspondence to Jon J. P. Warner, M.D., Harvard Shoulder Service, Department of Orthopaedic Surgery, Massachusetts General Hospital, 275 Cambridge St, Suite 403A, Boston, MA 02114, U.S.A. E-mail: jwarner@partners.org

© 2003 by the Arthroscopy Association of North America
0749-8063/03/1910-0112\$30.00/0
doi:10.1016/j.arthro.2003.09.031

significant bone loss is noted, an open approach with autogenous bone grafting is recommended.

Posterior shoulder instability remains a more enigmatic condition. It includes posterior dislocation and subluxation, which are a cause of pain and create symptoms of instability.⁸ Posterior inferior capsular laxity may be associated with a posterior Bankart.⁹ The posterior Bankart lesion has been described as the detachment of the posterior labrum and capsule. This lesion is less frequent than the anterior Bankart lesion. It usually occurs after high-energy extrinsic forces directed posteriorly.⁹

The concept of multidirectional instability was described by Neer and Foster¹⁰ in 1980 as "symptomatic humeral head translation in more than a direction." The pathoanatomy is caused by a patulous shoulder capsule and deficiency in the rotator interval, which leads to a significant amount of inferior joint translation. The history and the clinical findings should help to determine the predominant direction of instability.

PATIENT SELECTION

Although good surgical technique is obviously a key to success, patient selection is probably the single most important predictor of outcome. A well-performed arthroscopic procedure in the wrong patient or for the wrong diagnosis is likely to fail. In addition to considering the goals of the individual patient, the surgeon must also make the correct diagnosis and perform the appropriate surgical intervention.

Although arthroscopic techniques can now be applied to most types of instability, certain subsets of patients are still better treated through traditional open techniques.¹¹ Arthroscopic repair is still contraindicated in patients with significant glenoid or humeral bone loss,¹² in patients with humeral avulsions of the glenohumeral ligaments,¹³ and in those with capsular deficiency or insufficiency, such as in revision settings.¹⁴

History

A careful history and physical examination will provide information about the onset, direction, degree, duration, frequency of symptoms, and previous surgical treatment. Determining the presence of a traumatic cause will provide clues about the pathoanatomy that can be expected. Arm position, at the time of the initial injury and during symptoms, can help differentiate the direction of the instability.

The natural history of anterior glenohumeral insta-

bility is directly related to patient age and activity levels. For young patients and those in contact sports, the risk of recurrence approaches 90% to 95%.¹⁵ Such patients are particularly suited to arthroscopic repair because of the tissue quality. Also, a voluntary component of the instability must be determined.

Patients with recurrent posterior instability or MDI for whom nonsurgical treatment has failed are also excellent candidates for arthroscopic management. The primary indication for surgery, in case of posterior or MDI, is persistent shoulder pain that has not responded to a minimum 6 months nonoperative program that included avoidance of painful activities, nonsteroidal anti-inflammatory medications, and a home physical therapy program designed to improve shoulder strength. Less than 20% of patients with posterior or MDI need surgery.¹⁶⁻¹⁹

Physical Examination

The most common symptoms are pain, weakness, and mechanical symptoms such as catching. The presence of hyperlaxity in the contralateral shoulder and elbows and the patient's ability to bring the thumb to the forearm may signify a syndrome of generalized ligamentous laxity. This may sometime represent a familial predisposition to MDI.

Provocative testing, such as the apprehension sign or the jerk test (painful posterior translation of the glenohumeral joint in internal rotation), can be virtually diagnostic for anterior or posterior shoulder instability, respectively.²⁰ Also, the apprehension and relocation tests may confirm the diagnosis. Inferior laxity should be assessed with a sulcus sign, in neutral and in external rotation. Although the degree of a normal sulcus sign is quite variable, a painful sulcus sign or a sulcus sign that reproduces symptoms suggests inferior instability or MDI. Furthermore, a large sulcus sign that persists when the adducted arm is externally rotated suggests insufficiency of the rotator interval capsular region, which is structurally represented by the superior and middle glenohumeral ligaments as well as the coracohumeral ligament.

Careful motor and sensory evaluation of the axillary nerve should be performed to exclude an injury. In older patients, weakness may indicate a rotator cuff tear. The presence of muscle atrophy should be noted.

Imaging

Radiographic evaluation should include plain radiographs. Magnetic resonance imaging (MRI) or computed tomography (CT) with contrast can show labral

tears, capsular injuries, or bony deficiencies. Patients with concomitant glenoid fractures, large Hill-Sach's lesions, or bony erosions are not candidates for an arthroscopic repair.

Although the arthroscope can be used for diagnostic purposes, we prefer to identify coexisting pathology (rotator cuff tears), the degree of capsular laxity, and the extent of labral pathology preoperatively so that the appropriate surgical procedure can be selected and planned. Recent studies show MRI arthrography to be highly sensitive and specific for detecting capsulolabral lesions.^{21,22} CT is preferred if osseous pathology is suspected. CT is particularly helpful in the evaluation of glenoid retroversion in patients with posterior instability. CT arthrography can also be used to show chondral erosion, labral detachment, or excessive capsular redundancy.^{23,24}

SURGICAL TECHNIQUE

Principles

The general surgical principles are to restore the labrum to its anatomic attachment and to reestablish the appropriate tension in the inferior glenohumeral ligament complex and capsule. Cadaveric studies have shown that both the labrum and capsule must be injured for a dislocation to occur.²⁵ If the labrum is torn (Bankart or posterior Bankart), it should be repaired anatomically to the rim of the glenoid. Capsular laxity can be addressed by a superior and medial shift of the capsule. Plication can be used to increase the tension in the capsule and decrease the laxity. In situations in which labral tears are not present and the principal pathology is redundant capsule, a plication should be performed on the appropriate side of the joint to decrease the capsular volume and prevent translation. In patients with MDI, the plication is performed inferiorly, posteriorly, and anteriorly. The rotator interval should always be closed in patients with MDI or posterior instability.

Associated injuries to the rotator cuff or superior labrum should be repaired surgically. In the rare instances in which midcapsular ruptures of the glenohumeral capsule or avulsions of the humeral insertion of the glenohumeral ligaments are encountered, conversion to open repair should be considered.

Anesthesia and Positioning

Interscalene regional nerve blocks improve early postoperative pain relief and decrease narcotic requirements. Either the beach chair or lateral decubitus

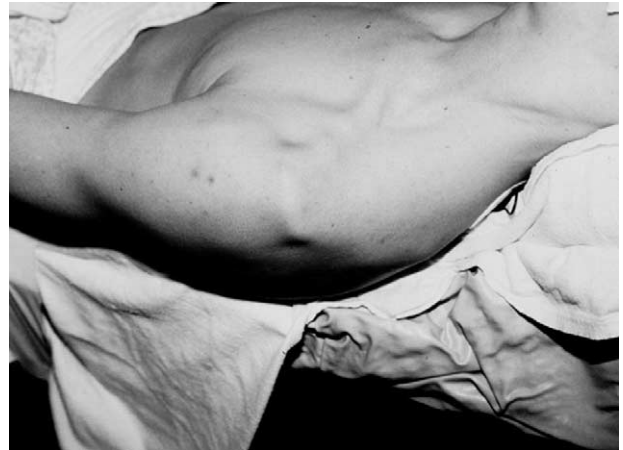

FIGURE 1. Examination under anesthesia: sulcus sign.

position may be used. The beach chair position is efficient and allows easy conversion to an open approach should that be needed. Although regional anesthesia is better tolerated in the beach chair position, access to the inferior capsule may be limited compared with the lateral decubitus position. The authors prefer beach chair for traumatic anterior instability surgery.

Lateral decubitus is preferred for patients with MDI or posterior instability because this position eases access to the axillary pouch and posterior capsule because of the lateral traction that is applied. The patient is positioned on a long beanbag, and the arm is held in an arm-traction device with 20° of abduction and 20° of extension. A direct lateral traction to the proximal humerus is also applied with 2 to 5 kg of traction.

Examination Under Anesthesia

Examination of the glenohumeral joint with the arm in various degrees of abduction and external rotation allows the examiner to assess the degree and direction of glenohumeral laxity. Side-to-side comparisons can be particularly helpful in patients with subtle instability patterns or for those with global laxity. Laxity is graded as Grade 1+ (translation to the glenoid rim), Grade 2+ (translation over the glenoid rim with spontaneous reduction), and Grade 3+ (dislocation that does not spontaneously reduce). Grades 2+ and 3+ are always considered abnormal. Patients may have patholaxity in more than one direction.

The sulcus sign is measured by applying an inferior force to the adducted arm (Fig 1). The arm should be placed in internal and external rotation. The sulcus is

quantified by the distance between the lateral border of the acromion and humeral head. This test evaluates the rotator interval and inferior capsule. A sulcus sign greater than 1 cm indicates a significant inferior component to the instability pattern, and a sulcus sign that does not decrease when the arm is externally rotated signifies a deficiency in the rotator interval region. The examination under anesthesia should confirm the preoperative diagnosis that was established through a careful history, physical examination, and imaging studies.

Portals

Anterior Instability: Two anterior portals (superior and inferior) are established using an “outside-in” technique with a spinal needle. These portals function as utility portals for instrument passage, glenoid preparation, suture management, and knot tying. It is important to separate these anterior cannulas widely so that access in the joint is not a problem. The second cannula is placed as low as possible in the rotator interval typically entering just superior to the subscapularis tendon and is usually placed a centimeter inferior and lateral to the palpable coracoid process so that it enters the joint aiming slightly lateral to medial. The first anchor is placed at the 5-o’clock position with the proper medial orientation. Alternatively, a trans-subscapularis approach can be used to improve inferior access.

Posterior Instability and MDI: A posterior arthroscopic portal is used for the arthroscope. The posterior portal needs to be more lateral than usual to allow better access to the posterior glenoid rim and posterior inferior capsule. An anterior portal is placed lateral and superior to the coracoid process and used for instrumentation and for outflow. The shift begins at the 6-o’clock position.

Capsulolabral Repair with Suture Anchors

For a capsulal repair with suture anchors, the 30° arthroscope should be placed in the posterior viewing portal. It can also be placed in the anterosuperior portal (“bird’s eye” portal) to view the anterior labrum. Working instruments can then be placed in the anteroinferior portal. In some instances, it is helpful to use a 70° arthroscope to visualize the glenoid rim while mobilizing the capsulolabral sleeve. The inferior glenohumeral ligament complex is mobilized from the glenoid neck as far inferiorly as the 6-o’clock position using electrocautery or a small elevator. The capsulolabral sleeve must be mobilized until it can be shifted superiorly and laterally onto the glenoid rim.

The release should proceed until the muscle fibers of the underlying subscapularis are seen. Next, the glenoid neck is decorticated with a motorized shaver to facilitate healing of the repaired labrum and capsule.

Anchors are placed on the articular rim through the anterior-inferior cannula at an angle that avoids articular penetration. They should not be placed inadvertently along the medial scapular neck. Anchor placement should proceed from inferior to superior. The anchor should be assessed for security and the suture for slideability.

The labrum is repaired and the capsule is shifted. The authors prefer to use a shuttling device for passing sutures because it is gentler and more adaptable than direct suture passage. If a suture shuttle device or punch device (Caspari punch, Linvatec, Largo, FL) is used, then a shuttle relay (Linvatec) or monofilament suture is placed through the device and retrieved out of the superior cannula. The suture limb that exits the anterosuperior cannula is the suture that will ultimately pass through the soft tissue and becomes the “post” suture down which the sliding arthroscopic knot will move. It is preferable to have the knot on the soft tissue capsulolabral side of the repair. Standard arthroscopic sliding knots are then tied. The knot is cut leaving a 3- to 4-mm tail. These steps are repeated for each subsequent anchor.

Capsular Plication

Capsular plication is used to tension the capsule in patients with redundant or lax capsules. Patients with MDI or atraumatic anterior or posterior instability are candidates for this technique (Fig 2).

For posterior instability and MDI, the joint is visualized to the anterior cannula, while the posterior portal is used for instrumentation. Using the motorized shaver on reverse without suction, the posterior capsule is abraded to promote healing. The shift begins at the 6-o’clock position. Using an angled shuttling instrument, the capsule is grasped and the sharp tip of the instrument is passed through it and through the labrum. The shift begins about 1.5 cm lateral to the glenoid rim. A monofilament suture or a shuttle relay (Linvatec) is then passed through the tissue, and a No. 2 braided nonabsorbable suture (Ethibond, Ethicon, Sommerville, NJ), is passed through the labrum and the capsule. A sliding, locking knot is used to fold the capsule over itself. The same steps are repeated at the 7-, 8-, and 9-o’clock positions to complete the inferior and posterior shifts. After the posterior capsulorrhaphy,

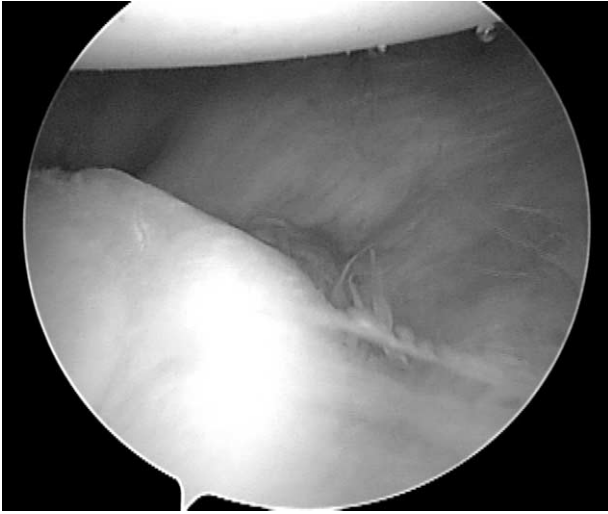


FIGURE 2. Redundant posterior capsule.

the capsular shift is repeated at the 5- and 4-o'clock positions to tighten the anteroinferior capsule (Figs 3 and 4).

In case of presence of a posterior Bankart, the lesion is released as described for the anterior instability. With the use of the motorized shaver, the glenoid rim is abraded. Drill holes are made on the edge of the glenoid rim through the posterior portal. The anchors are inserted through the posterior portal. The same steps as described above are repeated to tension the posterior capsule to superiorly to the 9-o'clock position. The complete repair is assessed from both the anterior and the posterior portals.

Rotator Interval Closure

If after repair of the labrum and inferior and middle glenohumeral ligaments, the shoulder shows persistent inferior or inferoposterior translation, rotator interval closure is performed. The authors close the rotator interval in all patients with MDI or posterior instability.

The arthroscope is inserted posteriorly to visualize the rotator interval. The arm should be placed in external rotation and a curved shuttling device (Spectrum, Linvatec, Largo, FL), suture hook, spinal needle, or penetrating instrument (Penetrator, Arthrex, Naples, FL) is placed directly through the anterosuperior cannula or percutaneously through the portal without the cannula. The instrument is then advanced through the robust capsular tissue immediately superior to the subscapularis tendon. The suture or shuttle is then advanced into the joint. The cannula is backed

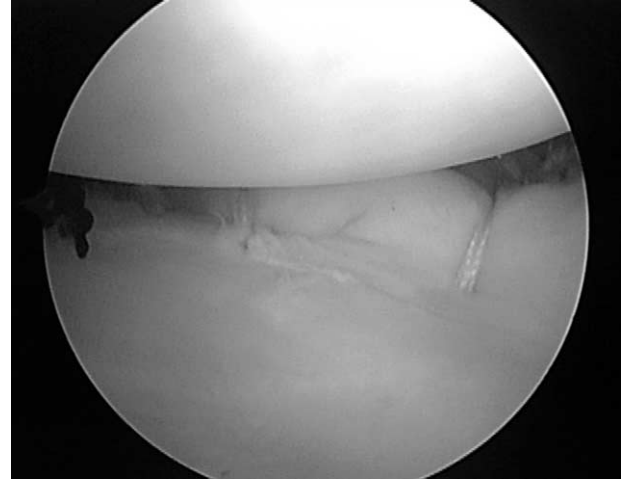


FIGURE 3. Anterior capsular shift.

out of the joint, and the penetrating instrument is then passed through the strong tissue just anterior to the supraspinatus tendon. The suture or shuttle is then grasped. Both suture limbs are then retrieved out the anterosuperior cannula. A crochet hook can help in this retrieval. The sutures are then tied blindly and extra-articularly. Additional sutures may be added as needed (Fig 5).

Thermal Capsulorrhaphy

Thermal capsulorrhaphy has been used as an adjunct to tighten the capsule for persistent capsular laxity. Unfortunately, peer reviewed literature advocating its routine use is limited. Initial excitement for

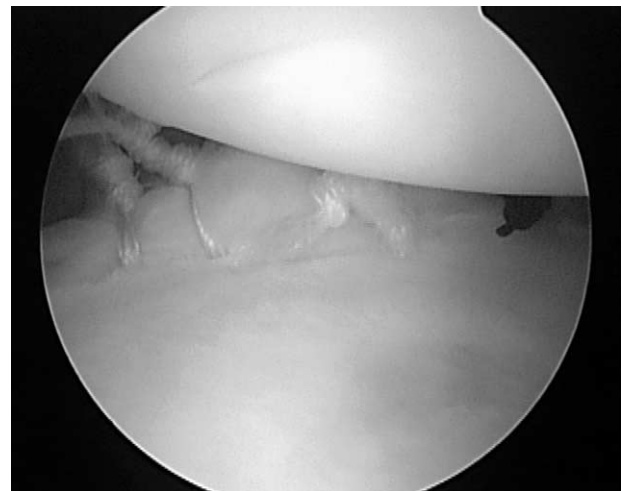


FIGURE 4. Posterior capsular shift.

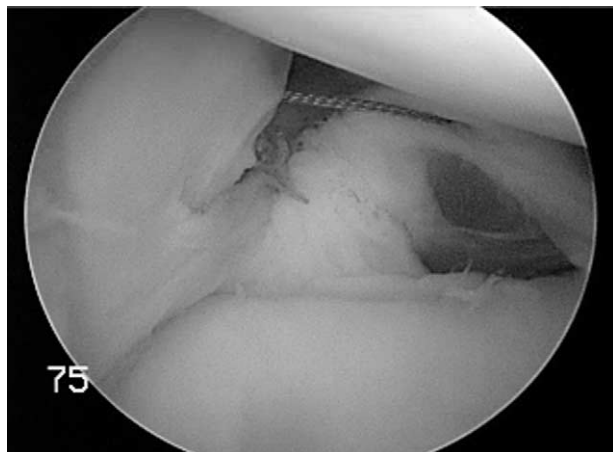


FIGURE 5. Rotator interval closure.

this technique has been tempered as several series have documented unacceptably high failure rates (DF D'Alessandro, JP Bradley, Unpublished data, 2000; TJ Noonan, KK Briggs, RJ Hawkins, Unpublished data, 2000; DF D'Alessandro, JP Bradley, PM Connor, Personal communication, 2001). If one chooses to use thermal energy for a lax capsule, it should be applied after all anchors have been placed and all knots have been tied. Shrinking before suture placement increases the level of difficulty in assessing, approximating, and repairing the soft tissue to the glenoid rim.

Either a monopolar radiofrequency device or a bipolar radiofrequency device can be used. To date, no prospective randomized comparisons of either device have been performed. Thus, the technique of thermal treatment of the capsule remains empiric. A grid-like or "cornrow" pattern is preferred, as this theoretically maintains normal areas of the capsule between thermally treated areas allowing viable cells to repopulate thermally-modified areas. Results have been variable and less favorable than those achieved with traditional open results. With these data in mind and with better suture techniques, the authors of this article favor suture plication techniques for excessive capsular laxity.

POSTOPERATIVE REHABILITATION

Postoperative rehabilitation after arthroscopic shoulder stabilization is similar to that after open surgery. Immobilization is required for 4 to 6 weeks, depending on the quality of the repair and the instability pattern treated. Isometrics and gentle pendulum exercises may begin immediately. In most cases, ac-

tive forward elevation may begin after the first 2 to 3 weeks. At 4 weeks, external rotation may be permitted to 30° to 40°. At 4 to 6 weeks, rotation limits are gradually extended, and at 8 to 10 weeks progressive strengthening begins. Return to sport occurs at 18 to 36 weeks.

Patients with posterior instability or MDI are placed in a gunslinger brace to maintain the arm in neutral rotation and 20° abduction. The arm stays in a gunslinger brace for 6 weeks. During the next 6 weeks, active range of motion is allowed only for daily living activities. After 12 weeks, strengthening is started, and progresses under the supervision of a physical therapist. Contact and collision sports are allowed after 6 months.

DISCUSSION

Arthroscopic treatment of glenohumeral instability has evolved rapidly over the past few years. Better understanding of the pathoanatomy, advances in surgical technique, and improved technology now make it possible to have success treating patients with all types of shoulder instability. In most recent series, the results of arthroscopic treatment equal or exceed the results of open series (Table 1).

Patient selection remains critical to the ultimate success. Patient selection involves careful diagnostic evaluation and selection of the appropriate surgical treatment. The other key variable is the surgical technique. All pathology should be addressed appropriately at the time of surgery. The pathoanatomy is variable and involves soft tissue and bony structures. Failure to recognize significant bone loss will lead to poor results with high recurrence rates. Experience and practice will help surgeons improve outcomes.

The principal goals of the surgery are to restore the labrum and to tension the capsule. The surgical procedure selected should match the pattern of instability and the pathoanatomy that is encountered. Direct re-

TABLE 1. Comparisons Between Arthroscopic (A) and Open (O) Stabilization

Reference	No. of Patients A/O	Mean Follow-up (mo) A/O	Recurrence (%) A/O
Field (1999) ³⁶	50/50	33/30	8/0
Cole (1999) ³⁷	37/22	52/55	16/9
Steinbeck (1998) ³⁸	30/32	36/40	17/5
Guanche (1996) ³⁹	25/12	27/25	33/8
Geiger (1993) ⁴⁰	16/18	23/34	43/0

pair of the capsule and labrum, plication of the capsule, and closure of the rotator interval can all be accomplished with the arthroscopic techniques described in this article. For patients with either anterior or posterior capsulolabral disruptions, the authors prefer the arthroscopic suture anchor techniques because they best restore the anatomy and most closely duplicate the traditional open Bankart repair. For patients with MDI or capsular redundancy without a Bankart lesion, capsulorrhaphy with suture plication is preferred.

Arthroscopic methods of treatment of posterior instability include capsular plication, capsulolabral repair, and thermal shrinkage.^{9,26,27} The best results seem to be with a labral repair and some degree of capsulorrhaphy.²⁶ For patients with MDI or posterior instability, the authors recommend the use of posterior and anterior portals and the lateral decubitus position so that the surgeon will have good access to the axillary pouch and to the posterior capsule. The posterior portal also permits the proper angle for insertion of anchors in the glenoid rim. Results of posterior arthroscopic stabilization reported varied from 75%⁸ to 84%²⁸ good and excellent results. For voluntary posterior instability, surgical treatment remains controversial. Recurrence after soft tissue procedures has been reported to vary from 0% (0 of 15) for Neer and Foster¹⁰ to 72% (18 of 25 patients) for Hurley et al.¹⁸ Most advocate nonsurgical treatment as the mainstay of treatment.

Multidirectional instability may involve a variety of anatomic lesions and as such there is great interest in the arthroscopic treatment of MDI. Few articles dealing with MDI have been published. Neer and Foster¹⁰ first reported their experience with an open technique in 1980. In that series, 36 patients were treated with an inferior capsular shift with no recurrences. Cooper and Brems²⁹ reported an 86% success rate after the open procedure for MDI. Recently, McIntyre et al.⁸ reported their results with arthroscopic treatment in 19 patients, with 18 good or excellent results. Gartsman et al.³⁰ also reported on 47 patients with 94% good or excellent results. Repair of the rotator interval is an essential element of the surgical treatment.

Thermal shrinkage of capsular tissues has been advocated as a means to address the capsular redundancy. There are however limits to the amount of capsular shortening that can occur. The heat can significantly denature collagen, leading to possible capsular rupture, and always leads to cell death.³¹ Thermal capsulorrhaphy has variable published results, with failure rates as low as 4% for Lyons et al.³² to 60% for

D'Alessandro et al.³³ The authors have found the direct visual response at the time of arthroscopy, and the clinical results of thermal capsulorrhaphy to be unpredictable. Furthermore, capsular insufficiency may be present in up to 33% after a laser energy capsulorrhaphy.³⁴ For these reasons, this technique is no longer used by the authors.

Postoperative rehabilitation does not vary significantly from that after traditional open techniques and soft tissue healing still takes many weeks to mature. Obviously, excessive early stress on the repair can lead to early failure. If the principles described in this article are followed, excellent results can be expected in the majority of patients.

REFERENCES

1. Debski RE, Sakone M, Woo SL, et al. Contribution of the passive properties of the rotator cuff to glenohumeral stability during anterior-posterior loading. *J Shoulder Elbow Surg* 1999;8:324-329.
2. Harryman DT, Sidles JA, Harris SL, Matsen FA. The role of the rotator interval capsule in passive motion and stability of the shoulder. *J Bone Joint Surg Am* 1992;74:53-66.
3. Warner JJ, McMahon PJ. The role of the long head of the biceps brachii in superior stability of the glenohumeral joint. *J Bone Joint Surg Am* 1995;77:366-372.
4. Warner JJ, Bowen MK, Deng X, et al. Effect of joint compression on inferior stability of the glenohumeral joint. *J Shoulder Elbow Surg* 1999;8:31-36.
5. Turkel SJ, Panio MW, Marshall JL, Girgis FG. Stabilizing mechanisms preventing anterior dislocation of the glenohumeral joint. *J Bone Joint Surg Am* 1981;63:1208-1217.
6. Cole BJ, Rodeo SA, O'Brien S, et al. The anatomy and histology of the rotator interval capsule of the shoulder. *Clin Orthop* 2001;390:129-137.
7. Burkhart SS, Debeer JF, Tehrany AM, Parten PM. Quantifying glenoid bone loss arthroscopically in shoulder instability. *Arthroscopy* 2002;18:488-491.
8. McIntyre LF, Caspari RB, Savoie FH. The arthroscopic treatment of posterior shoulder instability: Two-years results of a multiple suture technique. *Arthroscopy* 1997;13:426-432.
9. Mair SD, Zarzour RH, Speer KP. Posterior labral injury in contact athletes. *Am J Sports Med* 1998;26:753-758.
10. Neer CS, Foster C. Inferior capsular shift for involuntary inferior and multidirectional instability of the shoulder. *J Bone Joint Surg Am* 1980;62:897-908.
11. Cole BJ, L'Insalata J, Irrgang J, Warner JJ. Comparison of arthroscopic and open anterior shoulder stabilization: A two to six-year follow-up study. *J Bone Joint Surg Am* 2000;82:1108-1114.
12. Burkhart SS, DeBeer JF. Traumatic glenohumeral bone defects and their relationship to failure of arthroscopic Bankart repairs: significance of the inverted-pear glenoid and the humeral engaging Hill-Sachs lesion. *Arthroscopy* 2000;16:677-694.
13. Warner JJ, Beim GM. Combined Bankart and HAGL lesion associated with anterior shoulder instability. *Arthroscopy* 1997;13:749-752.
14. Townley C. The capsular mechanism in recurrent dislocation of the shoulder. *J Bone Joint Surg Am* 1950;32:370-380.
15. Rowe C, Sakellarides H. Factors related to recurrences of

- anterior dislocations of the shoulder. *Clin Orthop* 1961;20:40-48.
16. Fronek J, Warren RF, Bowen M. Posterior subluxation of the glenohumeral joint. *J Bone Joint Surg Am* 1989;71:205-216.
 17. Pollock RG, Bigliani LU. Recurrent posterior shoulder instability: diagnosis and treatment. *Clin Orthop* 1993;291:85-96.
 18. Hurley JA, Anderson TE, Dear W, et al. Posterior shoulder instability: surgical versus conservative results with evaluation of glenoid version. *Am J Sports Med* 1992;20:396-200.
 19. Misamore GW, Facibene WA. Posterior capsulorrhaphy for the treatment of traumatic recurrent posterior subluxation of the shoulder in athletes. *J Shoulder Elbow Surg* 2000;9:403-408.
 20. Speer K, Hannafin J, Altchek D, Warren R. An evaluation of the shoulder relocation test. *Am J Sports Med* 1994;22:177-183.
 21. Green M, Christensen K. Magnetic resonance imaging of the glenoid labrum: MR imaging of 88 arthroscopically confirmed cases. *Am J Sports Med* 1994;22:493-498.
 22. Iannotti J, Zlatkin M, Esterhai J. Magnetic resonance imaging of the shoulder. Sensitivity, specificity, and predictive value. *J Bone Joint Surg Am* 1991;73:17-29.
 23. Kinnard P, Tricoire J, Levesque R. Assessment of the unstable shoulder by computed arthrography: A preliminary report. *Am J Sports Med* 1983;11:157-159.
 24. Singson R, Feldman F, Bigliani L. CT arthrographic patterns in recurrent glenohumeral instability. *Am J Roentgenol* 1987;149:749-753.
 25. Speer K, Deng X, Borrero S, et al. A biomechanical evaluation of the Bankart lesion. *J Bone Joint Surg Am* 1994;76:1819-1826.
 26. Williams RJ, Strickland S, Cohen M, et al. Arthroscopic repair for traumatic posterior shoulder instability. *Am J Sports Med* 2003;31:203-209.
 27. Wolf EM, Eakin CL. Arthroscopic capsular plication for posterior shoulder instability. *Arthroscopy* 1998;14:153-163.
 28. Antoniou J, Harryman DT. Posterior instability. *Orthop Clin North Am* 2001;32:463-473.
 29. Neer CS II, Foster C. Inferior capsular shift for involuntary inferior and multidirectional instability of the shoulder. *J Bone Joint Surg Am* 1980;62:897-908.
 30. Cooper RA, Brems JJ. The inferior capsular-shift procedure for multidirectional instability of the shoulder. *J Bone Joint Surg Am* 1992;74:1516-1521.
 31. Gartsman GM, Roddey TS, Hammerman SM. Arthroscopic treatment of multidirectional glenohumeral instability: Two to five-years follow-up. *Arthroscopy* 2001;17:236-243.
 32. Deutsch A, Protomastro P, Barber J, Victoroff B. The biomechanical effects of thermal capsulorrhaphy on the kinematic properties of the glenohumeral joint. American Shoulder and Elbow Surgeon's Specialty Day; 1999; Anaheim California; 1999.
 33. Lyons TR, Griffith PL, Savoie FH, Field LD. Laser-assisted capsulorrhaphy for multidirectional instability of the shoulder. *Arthroscopy* 2001;17:25-30.
 34. D'Allessandro D, Bradley JP, Fleischli JE, Connor PM. Prospective evaluation of thermal capsulorrhaphy for shoulder instability: indications and results: Two to five years follow-up. Biennial Shoulder and Elbow Meeting; 2002; Orlando, FL; 2002.
 35. Wong KL, Williams GR. Complications of thermal capsulorrhaphy of the shoulder. *J Bone Joint Surg Am* 2001;83:151-155 (Suppl 2).
 36. Field L, Savoie F, Griffith P. A comparison of open and arthroscopic Bankart repair. *J Shoulder Elbow Surg* 1999;8:195.
 37. Cole B, Warner JPI. Anatomy, biomechanics, and pathophysiology of glenohumeral instability. In: Williams J, Iannotti G, eds. *Disorders of the shoulder: Diagnosis and management*. Philadelphia: Lippincott Williams & Wilkins, 1999;207-232.
 38. Steinbeck J, Jerosch J. Arthroscopic transglenoid stabilization versus open anchor suturing in traumatic anterior instability of the shoulder. *Am J Sports Med* 1998;26:373-378.
 39. Guanche C, Quick D, Sodergren K, Buss D. Arthroscopic versus open reconstruction of the shoulder with isolated Bankart lesions. *Am J Sports Med* 1996;24:144-148.
 40. Geiger D, Hurley J, Tovey J. Results of arthroscopic versus open Bankart suture repair. *Ortho Trans* 1993;17:973.