

ARTICLE COVER SHEET

LWW—TECHNIQUES

FLA, SF, LTE and Case Study & Review

Article : BTE20100

Creator : dJ44

Date : 4/2/2008

Time : 11:1

Article Title :

Number of Pages (including this page) : 8

Template Version : 3.4

03/01/08

Scripts:

1. [sc_Extract_Xml](#)
2. [sc_Multifig_Marker](#)
3. [Autopagination compliant](#)
4. [run_on](#)

TECHNIQUE

Open Anterior Capsular Reconstruction of the Shoulder for Chronic Instability Using a Tibialis Anterior Allograft

Sepp Braun, MD
Steadman Hawkins Research Foundation
Vail, CO

Peter J. Millett, MD, MSc
Steadman Hawkins Clinic
Vail, CO

■ ABSTRACT

Stability of the shoulder comes from a complex interaction of various factors. Dynamic and static components are provided by soft tissue and bony structures creating joint stability. Recurrent anterior glenohumeral instability can be a difficult problem because there is a wide variety of possible pathologies.

To address the problem, a precise analysis of the etiology of instability is necessary. Soft tissue insufficiency, osseous deficiency, and a combination of both have to be considered as etiologic factors.

This article focuses on the treatment of recurrent anterior glenohumeral instability secondary to soft tissue insufficiency—especially in patients who have undergone multiple ineffective surgeries before and have soft tissue disorders. Therefore, we present a technique for anterior capsulolabral reconstruction with a tibialis anterior tendon allograft. The main structures that are reconstructed by the allograft are the anterior labrum, the middle glenohumeral ligament, and the anterior band of the inferior glenohumeral ligament. Because of the complexity of the reconstruction, the technique is performed as open surgery, which allows precise placement and tensioning of the allograft tendon.

The postoperative protocol requires placing the arm in a sling for 6 weeks and cautious physiotherapy. The results of this salvage procedure are highly satisfactory.

Keywords: recurrent shoulder instability, open capsulolabral reconstruction, allograft

■ HISTORICAL PERSPECTIVES

Shoulder instability, particularly recurrent instability, is a complex problem that needs a systematic approach.^{1,2}

More than one third of all shoulder injuries are dislocations. The shoulder joint dislocates as often as all other joints in total.³ Traumatic shoulder dislocations and subsequent instability are more common than congenital instability.

There is a widely accepted consensus that anterior shoulder instability secondary to traumatic dislocations and traumatic redislocations can be successfully addressed by arthroscopic surgery, but success is clearly dependent on patient selection and surgical skills and techniques. Bankart repairs and capsular shifts are the most common procedures performed. Arthroscopic techniques have improved dramatically over the last years and are equal in results to open procedures according to some authors.⁴ There remain, however, special cases in which open procedures are still superior.^{5–7}

Open procedures for stabilization of the shoulder joint are mainly used to treat bony deficiencies or in case of multiple failed arthroscopic procedures.⁵

Although the failure rate of arthroscopic and open surgery, particularly in the group of patients with traumatic dislocation, is low, those patients that recurrently dislocate are a challenge to surgeons. Moreover, the recurrence of instability is related to the number of prior surgeries.⁵ Deficiency of the subscapularis, the capsule, and the important enforcing structures, the middle glenohumeral ligament (MGHL) and the anterior band of the inferior GHL (IGHL), can be seen after multiple (open) surgical attempts to stabilize the joint or as a complication of electrothermal capsulorrhaphy.^{8,9}

Despite these concerns, in many cases, recurrent shoulder instability should be treated surgically principally to reduce the patient's disability. A secondary benefit may be a decrease in the risk of premature glenohumeral osteoarthritis,¹⁰ although this is yet to be proven scientifically.

Open revision procedures for cases of recurrent instability are separated in 2 groups: anatomical and nonanatomical approaches. Anatomical techniques for open

AQ2

AQ1

Reprints: Peter J. Millett, MD, MSc, Steadman Hawkins Clinic, Vail, CO (e-mail: drmillett@steadman-hawkins.com).

shoulder stabilization include various techniques for capsular shifts and the classic Bankart repair.

Nonanatomical approaches can also be successful in eliminating instability, although in some instances are more invasive and in most instances will make further revision surgery even more difficult because of the loss of normal anatomical landmarks and structures. There is the Bristow-Latarjet technique, which is a transfer of the coracoid process,^{11,12} various techniques to address bone loss, such as glenoid reconstruction with an iliac crest bone graft,⁷ and procedures addressing bone deficiencies of the humeral head, such as Hill-Sachs lesions, by bone grafting.⁵

In some instances, the bony surfaces are normal, and the problem is purely a soft tissue problem. When the capsule and labrum are deficient either from intrinsic soft tissue/collagen disorders such as Ehlers-Danlos or from extrinsic capsule and labral disorders in the setting of multiple surgical procedures or electrothermal capsular necrosis, a capsulolabral reconstruction can be performed.

AQ3 There are techniques described using hamstrings,^{13,14} IT band,^{15,16} and Achilles tendon grafts¹⁷ for reconstruction of the anterior capsule. The purpose of this article is to describe our technique for an anatomical capsulolabral reconstruction with a tibialis anterior allograft as a salvage procedure for end-stage glenohumeral instability that is caused by capsular insufficiency.

■ INDICATIONS AND CONTRAINDICATIONS

The technique is regarded as salvage procedure for patients with recurrent shoulder instability and dislocations after multiple surgical attempts at surgical stabilization. This procedure may prevent the need for glenohumeral fusion as the last option.

Indications are recurrent shoulder instability in the setting of capsulolabral deficiency without associated bone loss. We sometimes refer to this as end-stage instability. These may be from a traumatic or atraumatic etiology. The technique addresses the soft tissues and is therefore useful in soft tissue disorders, such as Ehlers-Danlos syndrome, electrothermal capsular necrosis, the multiple-operated shoulder, and labral defects.

The decision for this particular surgical procedure therefore is usually based on a combination of the aforementioned pathologies causing severe instability that already has been unsuccessfully addressed by less invasive techniques such as an arthroscopic Bankart procedure with capsular shift.

Contraindications to this procedure include relevant bone loss secondary to traumatic Bankart lesions, large and engaging Hill-Sachs defects, or osseous deficiency of any other origin such as glenoid anomalies including increased anteversion or retroversion.

■ CLINICAL EVALUATION

The patient being considered for this procedure shows gross anterior-inferior instability visible by a positive sulcus sign in neutral position and external rotation of the arm. Dislocation or subluxation occurs with minimal force, and patients frequently have a history of dislocations in sleep or with daily life activities, which are not traumatic. There are often positive signs for general joint laxity, for example, being able to bring the thumb to the forearm and hyperextension of the elbow or knee joints, in patients with deficiencies of the soft tissue. Assessment of instability presents with grade 3 anteroposterior translation, grade 3 load-and-shift, and modified load-and-shift tests in the mid range of joint motion and a severe apprehension. Furthermore, physical examination includes assessment of rotator cuff and biceps tendon pathologies.

AQ4

■ RADIOGRAPHIC EVALUATION

Preoperative evaluation should include radiological imaging in 3 planes (anterior-posterior, axillary, Y view) and magnetic resonance (MR) arthrogram or computerized tomography to assess soft tissue anomalies and to obviate bone deficiency or bony pathologies, such as pathological glenoid anteversion or retroversion.

AQ5

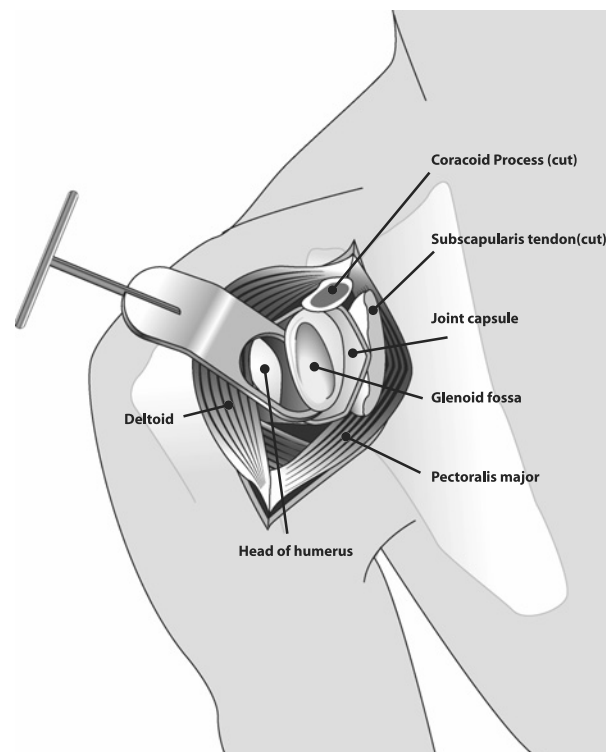


FIGURE 1. Standard deltopectoral approach for exposure of the glenohumeral joint. The coracoid process is cut for better visualization in the drawing only.

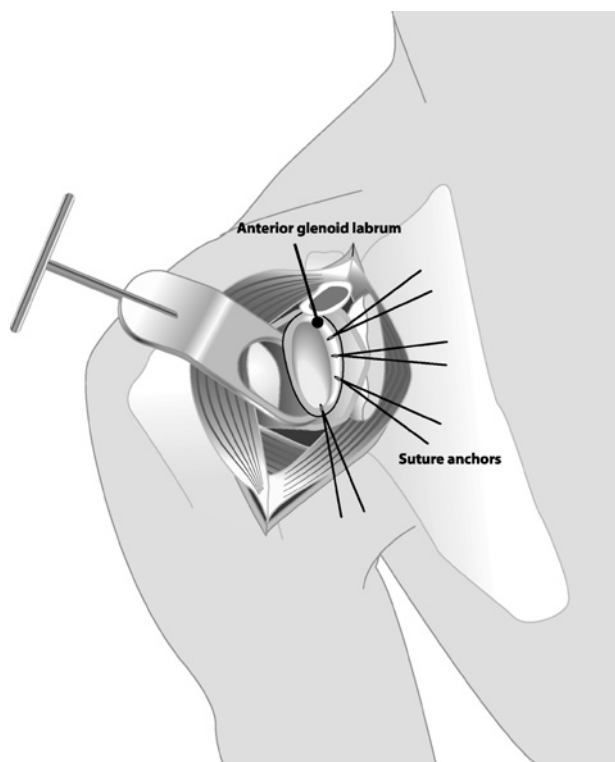


FIGURE 2. Positioning of the suture anchors at the anterior glenoid rim at 2-o'clock, 3-o'clock, 4-o'clock, and 5:30 positions.

Patients with deficiencies of the capsulolabral structures frequently present in MR imaging with wide joint capsules, hypotrophic anterior labrum, and either stretched or very thin superior, middle, and/or inferior GHJs.

Magnetic resonance imaging also helps in estimating the status after previous surgical interventions. Attention should be turned to the status of the anterior labrum and the width of the capsule.

Nonetheless, MR imaging evaluation is frequently difficult because of the artifact from prior surgery (anchors, scar tissue).

■ SURGICAL TECHNIQUE

Surgery is performed with regional plus general anesthesia, with the patient in a beach-chair position and with assistance of a pneumatic arm holder.

In cases of clinical or radiographic evidence of additional intraarticular pathologies or a suggestion of an engaging Hill-Sachs defect, a diagnostic glenohumeral arthroscopy before the open surgery can be helpful.

F1 A standard deltopectoral approach is performed to expose the glenohumeral joint (Fig. 1). In many cases, there is extensive scarring and altered soft tissue planes. The authors prefer to open the bicipital groove and tenodesis

the long head of the biceps. The subscapularis tendon can then be taken down from the insertion at the lesser tuberosity, with the capsule in 1 layer. This simplifies the exposure. In many cases, the capsule is attached to the subscapularis. The tendon is secured with sutures for later repair.

The rotator interval is opened, and thus full exposure of the glenohumeral joint is achieved. This enables accurate inspection of the glenohumeral joint.

Labral Reconstruction

Once good exposure of the glenoid is obtained, the glenoid neck is prepared with a burr. Any residual labrum is removed. Three or preferably 4 suture anchors are used as points of fixation of the labral reconstruction at the anterior glenoid rim. These are placed at 2-o'clock, 3-o'clock, 4-o'clock, and 5:30 positions (Fig. 2). A 6- or 7-mm tibialis anterior allograft, **F2** which has been whipstitched at either end with Fiberwire (Arthrex, Naples, Fla), is placed along the anterior glenoid rim to reconstruct the labrum. It is then secured with the anchors starting at the middle and working superiorly and inferiorly to the remaining anchors (Fig. 3). **F3**

In this way, the tibialis anterior allograft is used to recreate the anterior labrum. The remaining native capsule and labrum are then sewn into the allograft with no. 2 permanent sutures to reinforce the neolabrum and also to bring in vascularity to help with healing and graft incorporation.

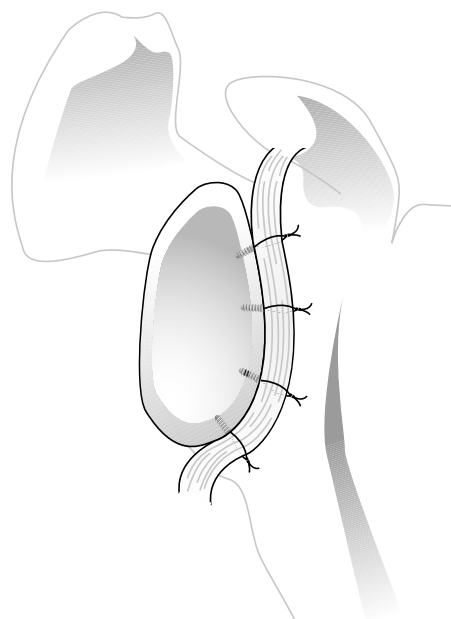


FIGURE 3. Placing and securing the graft tendon with the sutures at the anterior glenoid rim.

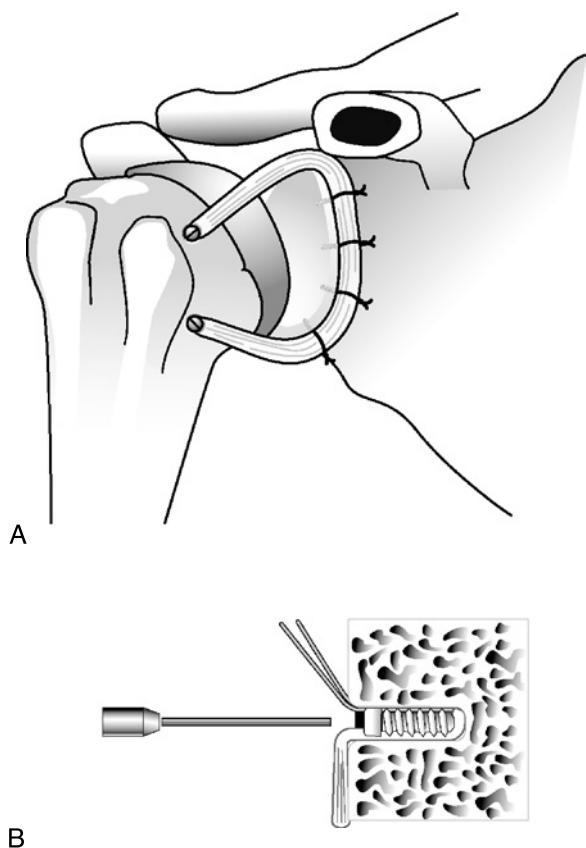


FIGURE 4. Fixation of the graft limbs to the humerus in bone tunnels with biodegradable interference screws. A, Positioning of the graft superiorly medial to the lesser tuberosity and inferiorly at the level of the inferior border of the subscapularis tendon. B, View of the tendon pushed in the bone tunnel and fixed by a biodegradable interference screw.

Capsular Reconstruction

The 2 free limbs are then used to reconstruct the MGHL and the anterior band of the IGHL. The graft will be secured by bioabsorbable interference screws at both ends laterally in bone tunnels drilled in the humerus. The medial tunnels should be at the articular margin on the humerus, where the native capsule attaches. The drill's diameter for the tunnel is chosen according to the graft so that the interference screw provides good compression of the tendon in the bone tunnel. One tunnel is created for each limb of the allograft.

The 2 free superior and inferior limbs of the graft will be brought anteriorly, appropriately sized in length, and finally fixed at the humerus with 2 bioabsorbable interference screws (BioTenodesis screw, Arthrex) in bone tunnels in the technique similar to that used for biceps tenodesis^{18–21} (Figs. 4 and 5). As opposed to 2 blind-ended tunnels, alternatively, 2 complete tunnels (one superior and one inferior) can be created so

that they span the bicipital groove. The graft ends can then be passed through each tunnel, respectively, tensioned and tied to themselves lateral to the bicipital groove. Tensioning of the graft should occur with the shoulder in 30 degrees of external rotation and 30 degrees of elevation.

This technique allows the surgeon to reconstruct both the MGHL and the anterior band of the IGHL. For additional security, the residual native capsular tissue can be sewn to the neocapsular ligaments with no. 2 Ethibond.

Then the shoulder can then be placed through a range of motion, and stability can be tested intraoperatively.

The subscapularis and the adherent underlying capsule are then meticulously attached to the lesser tuberosity through bone tunnels or directly to the allograft (Fig. 6). The rotator interval is then closed in a pants-over-vest fashion to provide additional resistance against inferior translation. The remainder of the wound is closed in a standard fashion.

POSTOPERATIVE CARE

Postoperatively, the patient's arm is placed in a sling for 6 weeks. Pendulum exercises with limited passive range of motion start at approximately 4 weeks. Patients may have a persistent loss of external rotation and forward flexion, but the goal is at least 45 degrees of external rotation and 140 degrees of forward flexion. Active range of motion is started at weeks 8 to 10. Patients should

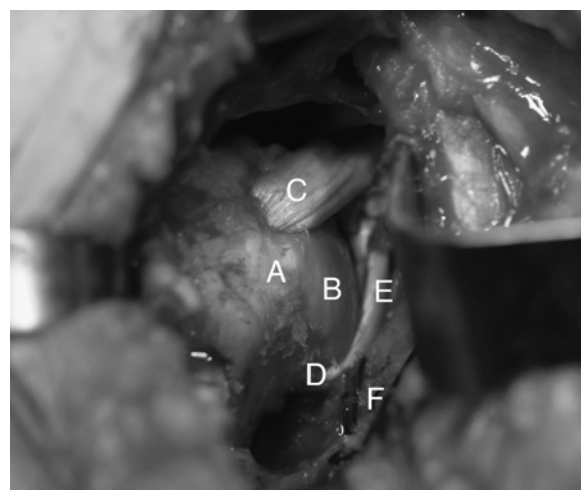


FIGURE 5. Intraoperative view with the tendon graft fixed. A, Head of humerus. B, Tendon graft fixed to the anterior glenoid rim reconstructing the anterior labrum. C, Tendon graft fixed to the humerus superiorly with an interference screw. D, Tendon graft fixed to the humerus inferiorly with an interference screw. E, Supscapularis tendon, secured with traction sutures, ready for repair.

F4–F5

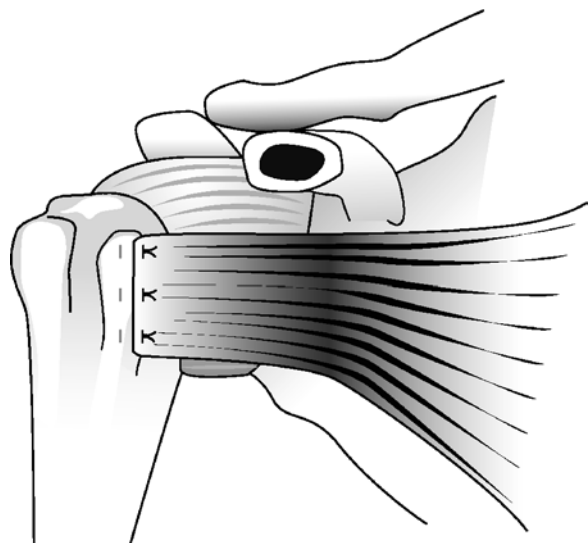


FIGURE 6. Attaching the subscapularis tendon to the lesser tuberosity with sutures through bone tunnels.

achieve maximal functional return by 4 to 6 months postoperatively.

■ COMPLICATIONS

Recurrent instability is possible. Stiffness could be a complication after having had the shoulder immobilized for 6 weeks, but in case of patients with chronic instability and recurrent dislocation, some stiffness is desirable. We have not seen a patient with significant limitation in range of motion after 4 to 6 months.

Interference screw pullout, and therefore failure of one of the main stabilizing factors of this procedure, is something we can think of, but never have seen in the cohort operated. To avoid this complication, immobilizing the joint for 6 weeks in a sling is required, as Kilicoglu et al²² showed for the strength of biceps tenodesis with bioabsorbable interference screw; after this period, the peak strength of the fixation is achieved.

■ RESULTS AND PROGNOSIS

Chronic shoulder instability and recurrent dislocations because of soft tissue deficiency are difficult problems to address. The presented technique of capsulolabral reconstruction with an allograft tendon is a salvage procedure to restore stability and therefore can avoid glenohumeral fusion as a last and much more invasive option.

Although there are many other techniques described to restore stability with open or arthroscopic soft tissue reconstruction, there are some advantages of the presented procedure:

The reconstruction of the anterior labrum is anatomical and increases the depth of the cavity. Moreover, the

most important ligaments for anterior-inferior stability, the MGHL and IGHL, are reconstructed, and tensioning and fixation of the structures can be obtained in a biomechanical, reliable, and secure fashion.

A precise diagnosis based on a complete physical examination and sufficient radiological imaging helps in selecting patients with soft tissue insufficiency and disorders and without relevant bony defects or malformations. As patient selection fits the indication, the clinical results in this difficult patient population have been favorable.

So far, 13 patients with severe recurrent dislocations after multiple surgeries have been treated with the technique described by the senior author. Nine of these procedures were successful. These patients were highly satisfied with the outcome, did not have clinical evidence for instability, and did not report recurrent instability, subluxations, or dislocations after the procedure. Nevertheless, there were 4 patients who had to be revised. One because of infection early after the procedure, and one because of an avulsion of the tendon graft from the humeral head in the early rehabilitation phase. Two others had recurrent instability even after the index surgery and after the rehabilitation phase. Therefore, one had to be converted to a Latarjet procedure and one to a glenohumeral fusion.

Thus, the presented technique of open anterior capsular reconstruction of the shoulder for chronic instability using a tibialis anterior allograft is a feasible salvage procedure that can help in avoiding much more invasive and lifestyle-limiting procedures such as fusion of the glenohumeral joint.

■ REFERENCES

1. Flatow EL, Miniaci A, et al. Instability of the shoulder: complex problems and failed repairs: Part II. Failed repairs. *Instr Course Lect.* 1998;47:113–125.
2. Flatow EL, Warner JJ. Instability of the shoulder: complex problems and failed repairs: Part I. Relevant biomechanics, multidirectional instability, and severe glenoid loss. *Instr Course Lect.* 1998;47:97–112.
3. Rowe CR. Prognosis in dislocations of the shoulder. *J Bone Joint Surg Am.* 1956;38-A(5):957–977.
4. Cole BJ, L'Insalata J, et al. Comparison of arthroscopic and open anterior shoulder stabilization. A two to six-year follow-up study. *J Bone Joint Surg Am.* 2000;82-A(8):1108–1114.
5. Millett PJ, Clavert P, et al. Open operative treatment for anterior shoulder instability: when and why? *J Bone Joint Surg Am.* 2005;87(2):419–432.
6. Lenters TR, Franta AK, et al. Arthroscopic compared with open repairs for recurrent anterior shoulder instability. A

AQ9

- systematic review and meta-analysis of the literature. *J Bone Joint Surg Am.* 2007;89(2):244–254.
7. Warner JJ, Gill TJ, O'hollerhan JD, et al. Anatomical glenoid reconstruction for recurrent anterior glenohumeral instability with glenoid deficiency using an autogenous tricortical iliac crest bone graft. *Am J Sports Med.* 2006;34(2):205–212.
 8. Wong KL, Williams GR. Complications of thermal capsulorrhaphy of the shoulder. *J Bone Joint Surg Am.* 2001;83-A(Suppl 2 Pt 2):151–155.
 9. Hawkins RJ, Krishnan SG, et al. Electrothermal arthroscopic shoulder capsulorrhaphy: a minimum 2-year follow-up. *Am J Sports Med.* 2007;35(1):1484–1488.
 10. Cameron ML, Kocher MS, et al. The prevalence of glenohumeral osteoarthritis in unstable shoulders. *Am J Sports Med.* 2003;31:53–55.
 11. Hovelius L, Sandstrom B, et al. One hundred eighteen Bristow-Latarjet repairs for recurrent anterior dislocation of the shoulder prospectively followed for fifteen years: study II—the evolution of dislocation arthropathy. *J Shoulder Elbow Surg.* 2006;15(3):279–289.
 12. Nourissat G, Nedellec G, et al. Mini-open arthroscopically assisted Bristow-Latarjet procedure for the treatment of patients with anterior shoulder instability: a cadaver study. *Arthroscopy.* 2006;22(10):1113–1118.
 13. Lazarus MD, Harryman DT 2nd. Open repair for anterior instability. In: Warner JJP, Iannotti JP, Gerber C, eds. *Complex and Revision Problems in Shoulder Surgery.* Philadelphia, PA: Lippincott-Raven; 1997:47–64.
 14. Warner JJP, Venegas AA, Lehtinen JT, et al. Management of capsular deficiency of the shoulder. A report of three cases. *J Bone Joint Surg Am.* 2002;84:1668–1671.
 15. Gallie WE, Le Mesurier AB. Recurring dislocation of the shoulder. *J Bone Joint Surg Br.* 1948;30:9–18.
 16. Iannotti JP, Antoniou J, Williams GR, et al. Iliotibial band reconstruction for treatment of glenohumeral instability associated with irreparable capsular deficiency. *J Shoulder Elbow Surg.* 2002;11:618–623.
 17. Moeckel BH, Altchek DW, Warren RF, et al. Instability of the shoulder after arthroplasty. *J Bone Joint Surg Am.* 1993;75:492–497.
 18. Boileau P, Krishnan SG, et al. Arthroscopic biceps tenodesis: a new technique using bioabsorbable interference screw fixation. *Arthroscopy.* 2002;18(9):1002–1012.
 19. Lo IK, Burkhart SS. Arthroscopic biceps tenodesis using a bioabsorbable interference screw. *Arthroscopy.* 2004;20(1):85–95.
 20. Romeo AA, Mazzocca AD, et al. Arthroscopic biceps tenodesis. *Arthroscopy.* 2004;20(2):206–213.
 21. Mazzocca AD, Rios CG, et al. Subpectoral biceps tenodesis with interference screw fixation. *Arthroscopy.* 2005;21(7):896.
 22. Kilicoglu O, Koyuncu O, et al. Time-dependent changes in failure loads of 3 biceps tenodesis techniques: in vivo study in a sheep model. *Am J Sports Med.* 2005;33(30):1536–1544.

AUTHOR QUERIES

AUTHOR PLEASE ANSWER ALL QUERIES

AQ1 = Please provide complete address for correspondence.

AQ2 = Please check if the expanded forms of MGHL and IGHL are correct.

AQ3 = Please provide the expanded form of IT.

AQ4 = Please check if the expanded form of a.p. is correct.

AQ5 = Please check if the expanded form of MR is correct.

AQ6 = Please check if proposed short title is ok.

AQ7 = "Repaired" was changed to "attached" both in text and in Figure 6 caption. Please check if appropriate.

AQ8 = Please add description of "F" in Figure 5, or delete label "F."

AQ9 = Please note that journal-specific instructions recommend inclusion of all names when there are 3 or fewer authors and the use of "et al" after the third name if there are 4 or more authors.

END OF AUTHOR QUERIES

Author Reprints

For **Rapid Ordering** go to: www.lww.com/periodicals/author-reprints

Techniques in Shoulder & Elbow Surgery

Order

Author(s) Name _____

Title of Article _____

*Article # _____ *Publication Mo/Yr _____

*Fields may be left blank if order is placed before article number and publication month are assigned.

Quantity of Reprints _____ \$ _____

Covers (Optional) _____ \$ _____

Shipping Cost \$ _____

Reprint Color Cost \$ _____

Tax \$ _____

Total \$ _____

Reprint Pricing

100 copies = \$375.00

200 copies = \$441.00

300 copies = \$510.00

400 copies = \$585.00

500 copies = \$654.00

Covers

\$108.00 for first 100 copies

\$18.00 each add'l 100 copies

Reprint Color

(\$70.00/100 reprints)

Shipping

\$5.00 per 100 for orders shipping within the U.S.

\$20.00 per 100 for orders shipping outside the U.S.

Tax

U.S. and Canadian residents add the appropriate tax or submit a tax exempt form.

 **Lippincott
Williams & Wilkins**
a Wolters Kluwer business

Use this form to order reprints. Publication fees, including color separation charges and page charges will be billed separately, if applicable.

Payment must be received before reprints can be shipped. Payment is accepted in the form of a check or credit card; purchase orders are accepted for orders billed to a U.S. address.

Prices are subject to change without notice.

Quantities over 500 copies: contact our Pharma Solutions Department at **410.528.4077**

Outside the U.S. call **4420.7981.0700**

MAIL your order to:
Lippincott Williams & Wilkins
Author Reprints Dept.
351 W. Camden St.
Baltimore, MD 21201

FAX:
410.528.4434

For questions regarding reprints or publication fees,

E-MAIL:
reprints@lww.com

OR **PHONE:**
1.800.341.2258

You may have included color figures in your article. The costs to publish those will be invoiced separately. If your article contains color figures, use Rapid Ordering www.lww.com/periodicals/author-reprints.

Payment

MC VISA Discover American Express

Account # _____ / _____ / _____ Exp. Date _____

Name _____

Address _____ Dept/Rm _____

City _____ State _____ Zip _____ Country _____

Telephone _____

Signature _____

Ship to

Name _____

Address _____ Dept/Rm _____

City _____ State _____ Zip _____ Country _____

Telephone _____

For **Rapid Ordering** go to: www.lww.com/periodicals/author-reprints