

Technical Note With Video Illustration

Arthroscopic Management of Glenohumeral Arthrosis: Humeral Osteoplasty, Capsular Release, and Arthroscopic Axillary Nerve Release as a Joint-Preserving Approach

Peter J. Millett, M.D., M.Sc., and Trevor R. Gaskill, M.D.

Abstract: Glenohumeral arthrosis frequently results in substantial discomfort and activity limitations. Shoulder arthroplasty has been shown to provide reliable pain relief under these circumstances in older, less active populations. Younger patients, however, who desire to continue participation in high-demand activities, may not be optimal candidates for glenohumeral arthroplasty. Arthroscopic debridement has been reported to provide incomplete symptomatic relief in this cohort of patients. It is evident from cadaveric studies that the axillary nerve runs in close proximity to the inferior glenohumeral capsule. An inferior humeral osteophyte of sufficient size may compress the axillary nerve and potentially contribute to posterior shoulder pain in a manner similar to quadrilateral space syndrome. Therefore we present a technique for and early results of the arthroscopic management of glenohumeral arthrosis in young, high-demand patients. This technique combines traditional glenohumeral debridement and capsular release with inferior humeral osteoplasty and arthroscopic transcapsular axillary nerve decompression. In the appropriate patient, these additions may provide symptomatic relief that is greater than that with simple debridement alone.

Glenohumeral osteoarthritis is classically characterized by pain, weakness, restricted motion, and cartilage loss, and it can be associated with inferior humeral or glenoid osteophytes. Whereas osteoarthritis of the shoulder is less common than arthrosis of other joints, it can be equally limiting.^{1,2} Nonoperative treatment modalities are often effective at minimizing

associated symptoms and maintaining quality of life.³ If these measures fail, glenohumeral arthroplasty has been shown to provide substantial relief.⁴

It is established that glenohumeral arthrosis typically manifests after the sixth decade of life.⁵ Younger patients, however, are also occasionally afflicted, and many of these patients maintain demanding lifestyles. Concerns regarding polyethylene glenoid wear, component loosening, functional loss, and the potential need for multiple revisions over the patient's lifetime potentially make young, high-demand patients poor candidates for shoulder arthroplasty. Prior reports indicate that arthroscopic debridement can yield pain and functional improvements in this patient population.⁶⁻⁹

Previous studies have suggested that outcomes of arthroscopic debridement are less effective when a large inferior osteophyte is present.^{6,7} We speculate that inferior humeral osteophytes may limit abduction by tensioning the axillary pouch and are capable of compressing the axillary nerve. As evidenced by quadrilateral space syndrome, patients with axillary

From The Steadman Clinic, Vail, Colorado, U.S.A.

Vail Valley Medical Center Institutional Review Board approval (PRO 2002-03) was received for completion of this study. Research performed at the Steadman Philippon Research Institute, Vail, Colorado. The authors report no conflicts of interest.

Received November 24, 2010; accepted March 25, 2011.

Address correspondence to Peter J. Millett, M.D., M.Sc., The Steadman Clinic, 181 W Meadow Dr, Suite 400, Vail, CO 81657, U.S.A. E-mail: drmillett@steadmanclinic.net

© 2011 by the Arthroscopy Association of North America

0749-8063/10700/\$36.00

doi:10.1016/j.arthro.2011.03.089

Note: To access the video accompanying this report, visit the [Month] issue of *Arthroscopy* at www.arthroscopyjournal.org.

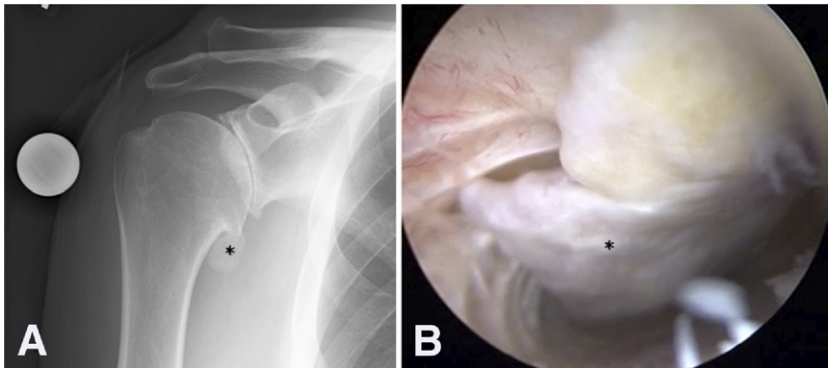


FIGURE 1. (A) Representative anteroposterior image of an active 48-year-old man with a large inferior humeral osteophyte apparent (asterisk). (B) Arthroscopic image of inferior capsular recess of right shoulder viewing from standard posterior portal in beach-chair position. The distal extent of the inferior humeral osteophyte is visualized (asterisk) intra-articularly.

nerve compression often describe posterior shoulder pain, weakness, and decreased athletic performance.¹⁰ Similarly, patients with glenohumeral arthrosis frequently report posterior shoulder pain and often exhibit large inferior humeral osteophytes in close proximity to the axillary nerve.¹¹ Data from our laboratory have shown that these osteophytes are capable of encroaching on the axillary nerve, changing the course of the nerve, and potentially affecting axillary nerve function (P.J.M., unpublished data, May 2010). Therefore we believe that removal of the large inferior humeral osteophytes could decompress the axillary nerve and alleviate pain in patients with glenohumeral arthrosis.

The purpose of this article is to describe a comprehensive arthroscopic management (CAM) technique that couples extensive glenohumeral debridement and capsular release with meticulous osteophyte removal from the humerus in addition to an arthroscopic transcapsular axillary nerve decompression (Video 1, available at www.arthroscopyjournal.org). This joint-preserving approach may provide added benefit to some young, active patients with mild or moderate glenohumeral arthrosis.

TECHNIQUE

The procedure is performed with the patient in the beach-chair position. It is important to be able to freely move the patient's arm because the full extent of the osteophyte can only be appreciated with arm rotation. An examination under anesthesia is performed, and ordinary preparation and draping are completed. A C-arm is draped into the field because fluoroscopy is always used to ensure complete bone resection. A standard posterior viewing portal is made approximately 1 cm medial and 2 cm inferior to the posterolateral corner of the acromion after insufflation of the glenohumeral joint with local anesthetic

and saline solution. A standard 30° arthroscope is then introduced into the glenohumeral joint, and a complete diagnostic arthroscopy is performed. A standard anterior portal is placed through the rotator interval, and a 5-mm working cannula is placed.

Debridement

Any degenerative labral tissue or unstable chondral flaps are carefully debrided with an oscillating shaver. Loose bodies are removed as encountered. Chondral borders should be stabilized to prevent continued cartilage slough and mechanical irritation of the joint. Next, a radiofrequency (RF) device and shaver are sequentially used to perform glenohumeral synovectomy in areas where there is relevant hypertrophy. An RF device is used to release rotator interval scar tissue, providing increased external rotation and restoring normal subcoracoid motion planes.

Osteophyte Removal/Humeral Osteoplasty

If a large inferior osteophyte and posterior or lateral shoulder pain (axillary nerve distribution) are present on preoperative examination, an axillary nerve decompression and osteophylectomy are performed (Fig 1). The inferior capsular recess is first visualized from the standard posterior viewing portal. Both 30° and 70° arthroscopes may be used to aid visualization (Table 1). Intraoperative fluoroscopy is used to determine and confirm the magnitude of resection. Humeral osteophytes are typically within the capsule (intra-articular) (Fig 2). It is preferable to maintain the inferior glenohumeral capsule while the spur is resected to both protect the axillary nerve and minimize fluid extravasation.

An accessory posteroinferior portal must be created. An 18-gauge spinal needle is used to localize a pos-

TABLE 1. *Surgical Tips*

-
- Working from medial to lateral and proximal to distal while decompressing the axillary nerve avoids inadvertent damage to small branches of the axillary nerve.
 - A blunt trocar can be used to safely separate the axillary nerve from scar tissue and capsule.
 - A clear 5.5-mm cannula can be used as a shield to protect the neurovascular structures while one is clearing debris from the inferior capsular recess.
 - Fluoroscopy and the use of both 30° and 70° arthroscopes help tremendously with visualization and resection of the inferior humeral osteophyte.
-

teroinferior arthroscopic portal (Fig 3). This portal is located approximately 5 cm inferior to and in line with the posterolateral aspect of the acromion. This is a low 7-o'clock portal. The axillary nerve runs from anterior-medial to posterior-lateral as it traverses the inferior capsular recess. In consideration of this, it is safest for the spinal needle to enter the inferior recess of the glenohumeral joint near the junction of the medial and central thirds of the inferior capsule, just anterior to the posterior band of the inferior glenohumeral ligament. Once the needle is placed for orientation, all cannulas are inserted bluntly to avoid injury to the nerve. Only the skin is incised, and a blunt switching

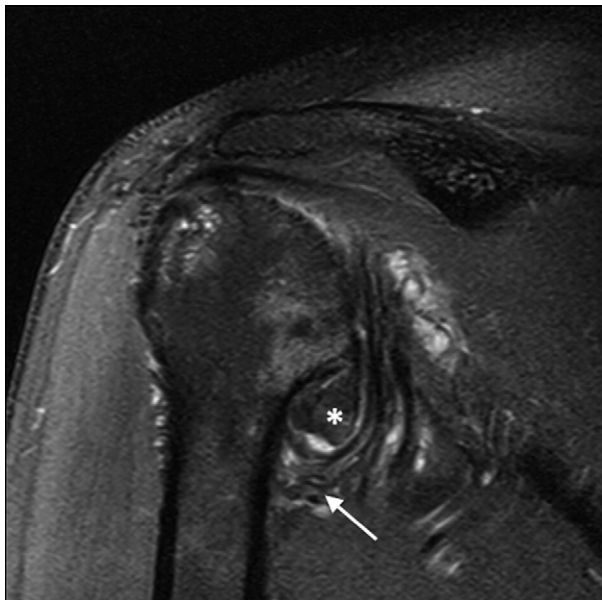


FIGURE 2. Sagittal oblique T2-weighted image of right shoulder showing magnitude of inferior humeral osteophyte (asterisk). Note its proximity to the axillary neurovascular bundle (arrow) and that this “goats beard” spur remains intracapsular. The neurovascular bundle in this case has also been displaced inferiorly.

stick is inserted into the axillary pouch. Dilators are then used before placement of a 5.0- or 6.0-mm cannula.

From this posteroinferior working portal, the inferior humeral osteophyte is identified and the osteophyte is resected with a 4.0- or 5.0-mm shielded arthroscopic bur (Fig 4). A curved curette can also be useful to help remove the spur, and a rasp can be used to contour the humerus once the spur is resected. The inferior joint capsule should be preserved while the bone resection is performed, thereby providing the axillary nerve additional protection from iatrogenic injury. The capsule protects the neurovascular bundle and also prevents bone debris from accumulating around the axillary nerve. Fluoroscopy is used to confirm adequate osteophyte removal (Fig 5). Internal rotation and extension of the arm allow complete resection of the inferior spur.

Inferior Capsular Release

Our clinical experience has shown that a thickened inferior capsule always accompanies large inferior humeral osteophytes and this limits shoulder motion, particularly abduction. After the spur is safely removed, an RF device or handheld punch is used to transect the inferior glenohumeral joint capsule. The capsulotomy begins posteriorly, near the cannula insertion site. A blunt trocar can be used for dissection, with the surgeon working proximally to distally to safely separate capsular tissue from the underlying

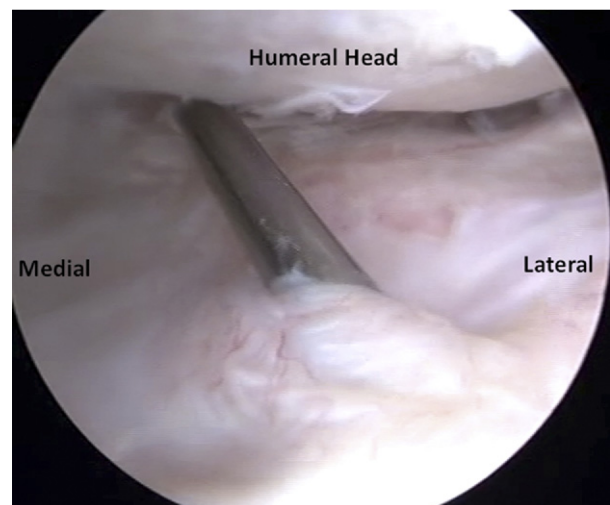


FIGURE 3. Arthroscopic image viewing inferior capsular recess of right shoulder from standard posterior portal in beach-chair position. The spinal needle is visible, approximating the posteroinferolateral arthroscopic portal.

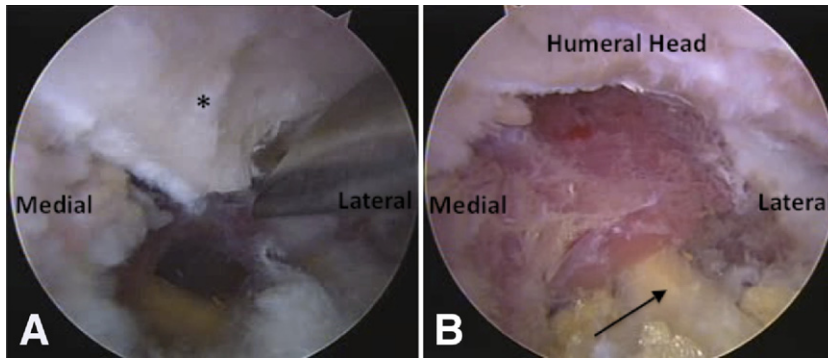


FIGURE 4. Inferior capsular recess of right shoulder viewing from standard posterior portal in beach-chair position. (A) A burr is being used to resect the inferior humeral osteophyte (asterisk). (B) Completed inferior humeral osteoplasty and axillary nerve decompression. The location of the axillary nerve is noted (arrow).

soft tissues. Blunt dissection from proximal to distal along the course of the axillary nerve helps to prevent inadvertent damage to the axillary nerve as it branches underneath the axillary pouch. The axillary nerve is typically encountered near the junction of the middle and anterior thirds of the inferior capsular pouch. The decompression is complete when the axillary nerve is visualized from the subscapularis to the teres major with no soft tissue tethering the nerve and no bone impinging upon it throughout this course (Fig 6). Hemostasis should be ensured before completion of this portion of the procedure.

Anterior and Posterior Capsular Releases

Once the axillary nerve decompression is complete, anterior and posterior capsular releases should be performed. The anterior capsule is released medially along the anterior glenoid at the capsulolabral junction, allowing visualization of the subscapularis muscle fibers. Care must be taken to avoid inadvertent injury to the subscapularis tendon. The rotator interval

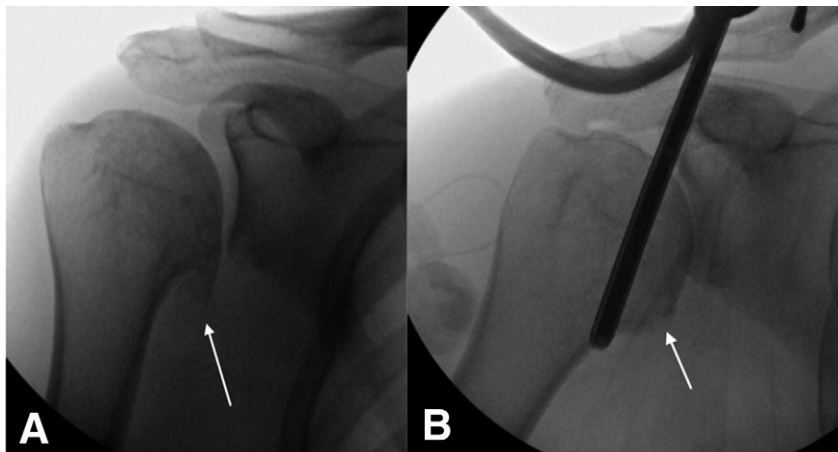
is also released until the underlying coracoid and coracoacromial ligaments are shown.

Next, the arthroscope is placed through the anterior portal so that the posterior glenohumeral joint is visualized. A similar debridement and capsular release procedure is performed posteriorly, with the surgeon working from inferior to superior. The capsular release is connected to the inferior release that is completed more safely during the axillary nerve decompression. By use of an RF device, the inferior release (5 to 7 o'clock) is extended posterosuperiorly. Similar to the anterior release, this capsulotomy is performed medially at the capsulolabral junction so as not to inadvertently damage the laterally based posterior rotator cuff tendons.

Additional Procedures

A subacromial decompression and subpectoral bicep tenodesis are performed in most instances based on individual patient pathology. The subacromial space is visualized and a liberal bursectomy is performed, thereby re-establishing the normal scapulo-

FIGURE 5. Preoperative (A) and postoperative (B) anteroposterior images of a 48-year-old man who underwent a CAM procedure. Note the absence of the large inferior humeral osteophyte (arrows) on the postoperative radiograph.



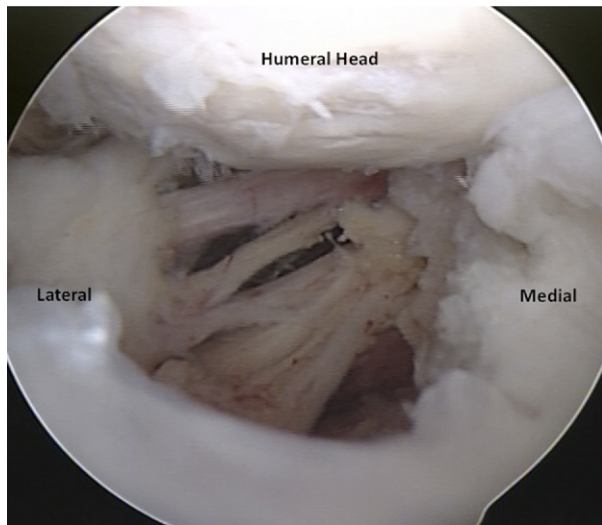


FIGURE 6. Arthroscopic image of left shoulder after completed axillary nerve decompression viewing from standard posterior portal in beach-chair position. Note that considerable branching of the axillary nerve is possible.

humeral motion interface. Unless there is a significant anterolateral acromial spur, an acromioplasty is not routinely performed. Frequently, the long head of the biceps is also degenerative and can contribute to postoperative pain and motion loss. If the biceps tendon

does not slide properly in the bicipital groove, the surgeon should remove it from the joint and bicipital groove by performing an arthroscopic tenotomy.¹² Because this is typically an active cohort of patients who desire to return to a high level of activity, a standard subpectoral long head-of-the-biceps tenodesis is performed with interference screw fixation.¹³

The glenohumeral joint is carefully manipulated to maximize glenohumeral motion, and when appropriate, motion is compared with the contralateral extremity. Portals are closed in standard fashion, and the patient's shoulder is placed in an immobilizer. Rehabilitation includes immediate active and passive range of motion. It is critical to maintain motion gains achieved after capsular release and manipulation. Operative regional interscalene anesthesia is frequently helpful to facilitate early therapy, and nonsteroidal agents are used liberally to decrease inflammation during rehabilitation. Strengthening typically begins around 4 to 6 weeks based on the postoperative clinical presentation. Maximal recovery is typically seen between 4 and 6 months postoperatively.

PRELIMINARY RESULTS

To date, we have performed 27 CAM procedures in 27 shoulders in 26 patients. At a mean of 20 months postoperatively, we have had a high patient satisfac-

FIGURE 7. Preoperative images of right shoulder showing (A) maximal forward flexion, (B) abduction external rotation, and (C) abduction internal rotation. After completion of the humeral osteoplasty, axillary nerve release, and capsular releases, increased motion is evident. Postoperative improvement was noted in (D) forward flexion, (E) abduction-external rotation, and (F) abduction-internal rotation.

tion rate, decreased pain, increased range of motion, and improved American Shoulder and Elbow Surgeons scores (Fig 7). To date, only 1 patient has elected to undergo total shoulder arthroplasty. There have been no complications in this preliminary series.

DISCUSSION

The treatment of glenohumeral arthrosis in young patients is difficult, and the optimal treatment has yet to be established.¹⁴ Glenohumeral arthroplasty provides reliable symptomatic relief in older patients with end-stage arthritis.^{4,15-17} Much of the published literature, however, involves older patients with lower functional demands. Young patients who are active laborers or have recreational interests that place high demands on the glenohumeral joint are perhaps less optimal candidates for current arthroplasty options. These patients may be excellent candidates for this type of joint-preserving procedure (Table 2).

It is apparent from cadaveric studies that the axillary nerve runs in close proximity to the glenohumeral joint capsule. Some authors report that the neurovascular bundle may be within 10 to 25 mm of the inferior aspect of the glenoid.^{18,19} Others have reported that the neurovascular bundle may be within 2 to 3 mm of the inferior joint capsule and moves based on the position of the extremity.²⁰ Therefore, we theorize that the axillary nerve is susceptible to a static compressive or dynamic traction injury when inferior humeral osteophytes are of sufficient size. In our clinical experience with this procedure, we have found that the axillary nerve is indeed directly beneath the inferior osteophyte and that, once it is removed and the nerve is released, the course of the nerve moves more superiorly. Considering this, we believe that axillary nerve compression from large inferior osteophytes may manifest symptoms that are similar to axillary nerve compression in quadrilateral space syndrome.

Arthroscopic management of glenohumeral arthrosis in young patients is not a novel concept. Several

TABLE 2. Key Points

-
- Large inferior humeral osteophytes may result in posterior and lateral shoulder pain.
 - Arthroscopic joint-preserving procedures may be preferred by young, active patients.
 - Humeral osteoplasty and axillary nerve decompression may provide additional symptomatic relief greater than that with simple debridement alone.
-

TABLE 3. Surgical Risks

-
- Iatrogenic axillary nerve damage
 - Fluid extravasation into axillary space
 - Incomplete humeral osteoplasty
 - Recurrent inferior capsular scar tissue
-

authors have reported satisfactory early results in small cohorts of patients after an extensive arthroscopic glenohumeral debridement and capsular release.⁶⁻⁸ Weinstein et al.⁶ reported satisfactory results after arthroscopic debridement alone in patients with mild or minimal arthritic changes. As would be expected, their results were less favorable in patients with advanced glenohumeral degeneration. Richards and Burkhart⁸ combined glenohumeral debridement with capsular release in young patients and reported improved glenohumeral motion and a mean symptom-free period of 9 months in a small series of patients. Van Thiel et al.⁷ recently reported substantial pain relief at a mean of 27 months in 55 of 71 patients who underwent arthroscopic debridement. Therefore, arthroscopic management of glenohumeral arthrosis may not prevent the arthritic progression, but it may provide a window of improved pain and function, delaying a larger operation in those with physically demanding vocations.

To our knowledge, previous debridement procedures have not included humeral osteoplasty or axillary nerve decompression as routine portions of an arthroscopic joint-preserving procedure. Some authors have suggested that large humeral osteophytes may predict less favorable outcomes of arthroscopic debridement.^{6,7} The patients in our series all exhibited severe osteoarthritis and, by all measures, met the radiographic and clinical indications for total shoulder arthroplasty.

We speculate that osteophytic compression of the axillary nerve can contribute to shoulder pain in some patients in a manner similar to quadrilateral space syndrome. Therefore osteophyte removal and transcapsular axillary nerve decompression may provide symptomatic relief that is greater than simple debridement and capsular release alone. Failure to address this potentially compressive lesion may partially explain the less favorable outcomes reported by some authors when large osteophytes are present. A CAM procedure should only be considered, however, in young patients with high-demand lifestyles who are not candidates for glenohumeral arthroplasty or who desire a joint-preserving approach. It is also a techni-

cally demanding procedure that should only be undertaken by experienced shoulder arthroscopists.

SURGICAL RISKS

As reported previously, we have performed 27 consecutive CAM procedures without complication. However, a number of potential surgical risks do exist and should be discussed with prospective patients (Table 3). Most obviously, the procedure is performed in close proximity to the axillary neurovascular bundle, which could be injured during the arthroscopic procedure. To this end, the axillary nerve frequently undergoes arborization as it traverses inferior to the glenohumeral joint. Because any number of branches can be encountered in this location, smaller branches may be easily damaged if not appropriately identified. It is also conceivable that excessive fluid extravasation into the axillary space or arm could result in elevated upper extremity compartment pressures or neurovascular compression in a manner similar to retroperitoneal extravasation reported after hip arthroscopy.²¹⁻²³ Expedient axillary nerve decompression and moderate arthroscopic pump pressures can minimize this risk.

The inferior glenohumeral ligament is thought to be essential to glenohumeral stability.^{24,25} Releasing the inferior capsule may result in a higher risk of glenohumeral instability, however, our experience is that encompassing soft tissues are often contracted and minimize any risk of instability. In addition, the axillary nerve decompression is optimally performed between the anterior and posterior bands of the inferior glenohumeral ligament. Through preservation of these structures, the risk of glenohumeral instability is further reduced. Finally, because this is a relatively novel procedure, it is possible that scar formation after axillary nerve decompression may result in recurrent symptoms in some patients with longer-term follow-up. We believe that early and aggressive rehabilitation protocols and meticulous surgical hemostasis are important to avoid this potential complication.

The optimal treatment of glenohumeral arthrosis in young patients has yet to be firmly established. Whereas arthroplasty options provide reliable relief in older, lower-demand patients, the long-term longevity of these implants is not established in a young, high-demand population. Arthroscopic debridement and capsular release are reported to provide satisfactory results in young, active patients with mild or moderate arthrosis. When indicated, the addition of a humeral osteoplasty and axillary nerve decompression

may provide symptomatic relief that is greater than that with simple debridement alone.

REFERENCES

1. Matsen FA III, Ziegler DW, DeBartolo SE. Patient self-assessment of health status and function in glenohumeral degenerative joint disease. *J Shoulder Elbow Surg* 1995;4:345-351.
2. Gartsman GM, Brinker MR, Khan M, Karahan M. Self-assessment of general health status in patients with five common shoulder conditions. *J Shoulder Elbow Surg* 1998;7:228-237.
3. Silverstein E, Leger R, Shea KP. The use of intra-articular hylan G-F 20 in the treatment of symptomatic osteoarthritis of the shoulder: A preliminary study. *Am J Sports Med* 2007;35:979-985.
4. Kasten P, Pape G, Raiss P, et al. Mid-term survivorship analysis of a shoulder replacement with a keeled glenoid and a modern cementing technique. *J Bone Joint Surg Br* 2010;92:387-392.
5. Nakagawa Y, Hyakuna K, Otani S, Hashitani M, Nakamura T. Epidemiologic study of glenohumeral osteoarthritis with plain radiography. *J Shoulder Elbow Surg* 1999;8:580-584.
6. Weinstein DM, Bucchieri JS, Pollock RG, Flatow EL, Bigliani LU. Arthroscopic debridement of the shoulder for osteoarthritis. *Arthroscopy* 2000;16:471-476.
7. Van Thiel GS, Sheehan S, Frank RM, et al. Retrospective analysis of arthroscopic management of glenohumeral degenerative disease. *Arthroscopy* 2010;26:1451-1455.
8. Richards DP, Burkhart SS. Arthroscopic debridement and capsular release for glenohumeral osteoarthritis. *Arthroscopy* 2007;23:1019-1022.
9. Kerr BJ, McCarty EC. Outcome of arthroscopic debridement is worse for patients with glenohumeral arthritis of both sides of the joint. *Clin Orthop Relat Res* 2008;466:634-638.
10. Cahill BR, Palmer RE. Quadrilateral space syndrome. *J Hand Surg Am* 1983;8:65-69.
11. Collins DN. Pathophysiology, classification, and pathoanatomy of glenohumeral arthritis and related disorders. In: Iannotti J, Williams G, eds. *Disorders of the shoulder: Diagnosis and management*. Philadelphia: Lippincott Williams & Wilkins, 1999;421-470.
12. Boileau P, Ahrens PM, Hatzidakis AM. Entrapment of the long head of the biceps tendon: The hourglass biceps—A cause of pain and locking of the shoulder. *J Shoulder Elbow Surg* 2004;13:249-257.
13. Millett PJ, Sanders B, Gobezie R, Braun S, Warner JJ. Interference screw vs. suture anchor fixation for open subpectoral biceps tenodesis: Does it matter? *BMC Musculoskelet Disord* 2008;9:121.
14. Boselli KJ, Ahmad CS, Levine WN. Treatment of glenohumeral arthrosis. *Am J Sports Med* 2010;38:2558-2572.
15. Boorman RS, Kopjar B, Fehringer E, et al. The effect of total shoulder arthroplasty on self-assessed health status is comparable to that of total hip arthroplasty and coronary artery bypass grafting. *J Shoulder Elbow Surg* 2003;12:158-163.
16. Churchill RS. Elective shoulder arthroplasty in patients older than ninety years of age. *J Shoulder Elbow Surg* 2008;17:376-379.
17. Fehringer EV, Kopjar B, Boorman RS, Churchill RS, Smith KL, Matsen FA III. Characterizing the functional improvement after total shoulder arthroplasty for osteoarthritis. *J Bone Joint Surg Am* 2002;84:1349-1353.
18. Price MR, Tillett ED, Acland RD, Nettleton GS. Determining the relationship of the axillary nerve to the shoulder joint capsule from an arthroscopic perspective. *J Bone Joint Surg Am* 2004;86:2135-2142.

19. Yoo JC, Kim JH, Ahn JH, Lee SH. Arthroscopic perspective of the axillary nerve in relation to the glenoid and arm position: A cadaveric study. *Arthroscopy* 2007;23:1271-1277.
20. Uno A, Bain GI, Mehta JA. Arthroscopic relationship of the axillary nerve to the shoulder joint capsule: An anatomic study. *J Shoulder Elbow Surg* 1999;8:226-230.
21. Fowler J, Owens BD. Abdominal compartment syndrome after hip arthroscopy. *Arthroscopy* 2010;26:128-130.
22. Sharma A, Sachdev H, Gomillion M. Abdominal compartment syndrome during hip arthroscopy. *Anaesthesia* 2009;64:567-569.
23. Ladner B, Nester K, Cascio B. Abdominal fluid extravasation during hip arthroscopy. *Arthroscopy* 2010;26:131-135.
24. O'Connell PW, Nuber GW, Mileski RA, Lautenschlager E. The contribution of the glenohumeral ligaments to anterior stability of the shoulder joint. *Am J Sports Med* 1990;18:579-584.
25. Turkel SJ, Panio MW, Marshall JL, Girgis FG. Stabilizing mechanisms preventing anterior dislocation of the glenohumeral joint. *J Bone Joint Surg Am* 1981;63:1208-1217.