

# Combined Posterior Osseous Bankart Lesion and Posterior Humeral Avulsion of the Glenohumeral Ligaments

## A Case Report and Pathoanatomic Subtyping of “Floating” Posterior Inferior Glenohumeral Ligament Lesions

James B. Ames, MD, MS, and Peter J. Millett, MD, MSc

*Investigation performed at the Steadman Philippon Research Institute, Vail, Colorado*

The pathoanatomy of anterior shoulder dislocations has been well documented. Perthes<sup>1</sup> described an anterior labral lesion as early as 1906, and Bankart<sup>2</sup> wrote his classic article on recurrent anterior dislocations more than seventy years ago. Until recently, much less had been written about posterior shoulder instability; to our knowledge, the first case series was reported by Reeves<sup>3</sup> in 1963. Recurrent posterior glenohumeral joint instability is far less common than anterior instability, accounting for approximately 2% to 10% of all cases of shoulder instability<sup>4</sup>. Pathoanatomic findings in patients with unidirectional posterior instability include a posterior Bankart lesion, posterior humeral avulsion of the glenohumeral ligament (PHAGL), and various combinations of the two<sup>5,6</sup>. In their article on humeral avulsion of the glenohumeral ligament (HAGL), Bui-Mansfield et al.<sup>7</sup> defined the floating posterior inferior glenohumeral ligament (floating PIGHL) as a combined posterior Bankart lesion and PHAGL. Multiple cases of this lesion have been reported in the literature<sup>7-11</sup>. To our knowledge, there has been no reported case of the specific combination of a posterior osseous Bankart lesion and a PHAGL injury. We present a case of recurrent posterior instability associated with a combined PHAGL injury and posterior osseous Bankart lesion. We also describe four pathoanatomic subtypes of floating PIGHL lesions. The patient was informed that data concerning his case would be submitted for publication, and he provided consent.

### Case Report

A twenty-three-year-old left-hand-dominant man fell while snowboarding three years prior to presentation and sustained a left shoulder dislocation. He was not certain about the direction of the dislocation. He was able to relocate the shoulder

on the mountain with the help of friends and the ski patrol. Initially, he was managed nonoperatively with a sling and physical therapy as well as a progressive return to activities. He developed progressive shoulder instability; when he presented to our clinic, he was having three or four shoulder subluxation episodes daily, with occasional episodes of subluxation during sleep.

On initial physical examination at our clinic, the patient had equal passive and active glenohumeral ranges of motion in both shoulders. For the left shoulder, the findings of the motor and sensory examinations were normal, with full strength in all distributions of the rotator cuff. Results of the load and shift test were mildly positive (grade I)<sup>12</sup>. The jerk test produced posterior pain but no “clunk” or posterior apprehension.

Radiographs of the left shoulder revealed a small posterior glenoid rim fracture, consistent with a posterior osseous Bankart lesion (Fig. 1-A). A magnetic resonance imaging (MRI) scan confirmed the osseous Bankart lesion and also (on retrospective review) revealed a soft-tissue avulsion of the posterior band of the inferior glenohumeral ligament at its humeral attachment, consistent with a PHAGL lesion (Fig. 1-B). Given the severity of the symptoms as well as the prior unsuccessful nonoperative management, the patient underwent surgical treatment.

Examination under general anesthesia revealed grade-III translation posteriorly<sup>12</sup>, with the humeral head locking over the posterior part of the glenoid rim. The sulcus sign was symmetric, and there was no increased translation anteriorly. The patient was then placed in a beach-chair position, and a pneumatic arm holder (Spider; TENET Medical Engineering, Calgary, Alberta, Canada) was used. Standard two-portal arthroscopy demonstrated (1) a discrete posterior osseous Bankart lesion

**Disclosure:** One or more of the authors received payments or services, either directly or indirectly (i.e., via his or her institution), from a third party in support of an aspect of this work. In addition, one or more of the authors, or his or her institution, has had a financial relationship, in the thirty-six months prior to submission of this work, with an entity in the biomedical arena that could be perceived to influence or have the potential to influence what is written in this work. No author has had any other relationships, or has engaged in any other activities, that could be perceived to influence or have the potential to influence what is written in this work. The complete **Disclosures of Potential Conflicts of Interest** submitted by authors are always provided with the online version of the article.

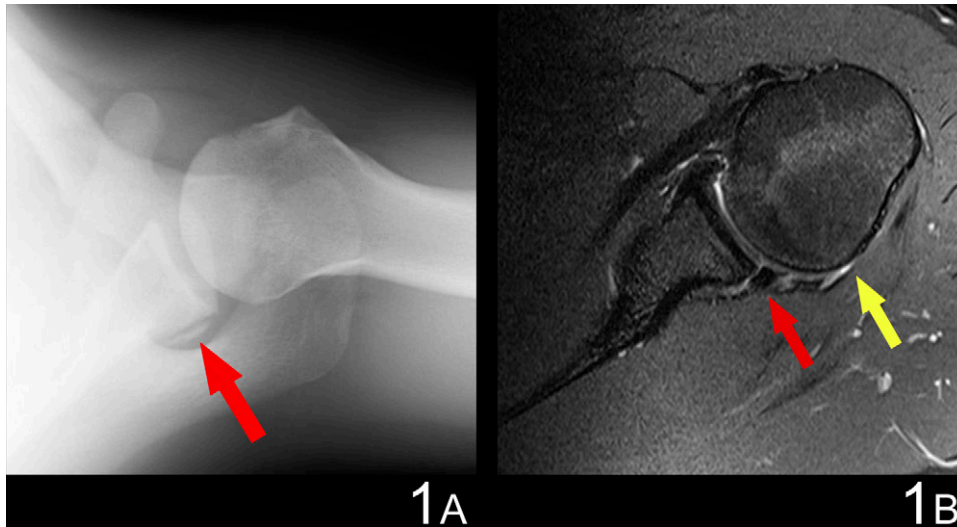


Fig. 1

**Fig. 1-A** Axillary radiograph of the left shoulder, showing the posterior osseous Bankart lesion (red arrow). **Fig. 1-B** Axial MRI of the left shoulder showing the posterior osseous Bankart lesion (red arrow) and the PHAGL lesion (yellow arrow).

from 3:00 to 6:00 (Fig. 2-A), (2) an obvious avulsion of the posterior band of the inferior glenohumeral ligament at its humeral attachment consistent with a PHAGL lesion (Fig. 2-B),

and (3) a small reverse Hill-Sachs lesion. This combination of injuries was consistent with a variant of the floating PIGHL. There was no abnormality of the anterior aspect of the labrum

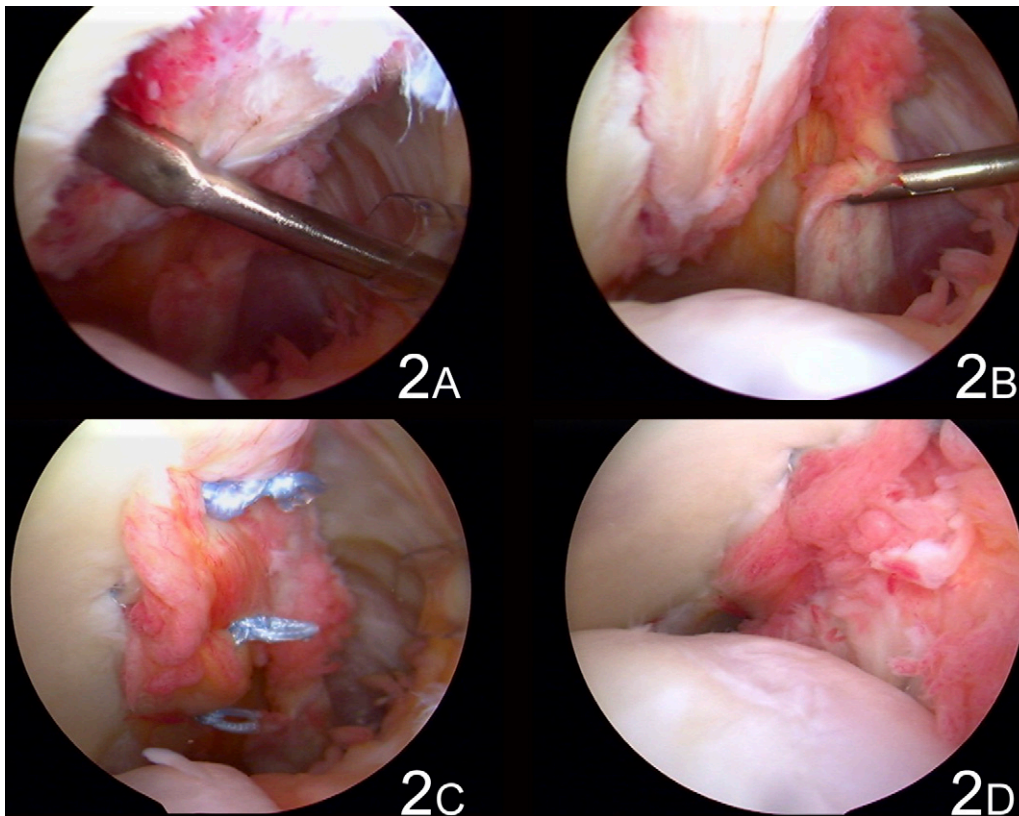


Fig. 2

Arthroscopic images showing the posterior osseous Bankart lesion (**Fig. 2-A**), the PHAGL lesion (**Fig. 2-B**), the repair of the posterior osseous Bankart lesion (**Fig. 2-C**), and the completed repair (**Fig. 2-D**).

or anterior aspect of the capsule. The biceps, subscapularis, supraspinatus, and infraspinatus tendons were intact. No other intra-articular abnormalities were found.

The arthroscope was placed anteriorly, and an accessory posterolateral portal was created. The osseous Bankart lesion and posteroinferior aspect of the labrum were mobilized and were repaired with use of three 2.4-mm anchors (Bio-SutureTak Suture Anchors; Arthrex, Naples, Florida) (Fig. 2-C). The humeral side of the PIGHL was then addressed. Using the posteromedial portal, we placed two 3.0-mm anchors (Bio-SutureTak Suture Anchors; Arthrex) at the articular margin of the rotator cuff, lateral to the bare area on the humeral head (the PHAGL avulsion site)<sup>13</sup>. The sutures were passed through the humeral side of the inferior glenohumeral ligament complex and tied extra-articularly, appropriately restoring tension to the posterior aspect of the capsule (Fig. 2-D). At this point, arthroscopic posterior drawer testing was performed, and the humerus no longer translated over the glenoid rim. The key steps in the repair can be viewed in Video 1.

At the conclusion of the surgery, the arm was placed in a shoulder immobilizer with an abduction pillow for six weeks. Three weeks after surgery, physical therapy was initiated with progressive passive shoulder motion, although posterior loading of the joint was avoided. Active shoulder motion commenced at six weeks; muscle strengthening was started at eight weeks. By three months postoperatively, the patient had achieved full shoulder motion and returned to all activities without episodes of dislocation, subluxation, or pain. At the time of the most recent follow-up (nine months postoperatively), the patient was well and

had completed a full season of snowboarding without any recurrence of shoulder symptoms.

### Discussion

We report on a patient with recurrent posterior shoulder instability and imaging and clinical findings of a reverse osseous Bankart lesion and a posterior humeral avulsion of the glenohumeral ligament (PHAGL). In their article on humeral avulsion of the glenohumeral ligament (HAGL), Bui-Mansfield et al.<sup>7</sup> defined the West Point classification system to categorize various patterns of injury to the inferior glenohumeral ligament. The posterior lesions that they defined were the PHAGL, the posterior bony humeral avulsion of the glenohumeral ligament (PBHAGL), and the floating posterior inferior glenohumeral ligament (PIGHL), which consisted of either of the first two injuries with a concurrent ligamentous labral tear. At the time of their review, the authors identified seventy-one HAGL lesions: five (7%) were posterior, and three (4%) were floating PIGHL lesions<sup>7</sup>. In a series of nine patients with a PHAGL lesion, Castagna et al.<sup>9</sup> identified three patients with a floating PIGHL lesion. In a review article, Pokabla et al.<sup>10</sup> identified an additional two patients with a floating PIGHL lesion and described the surgical reconstruction technique. Recently, Chen et al.<sup>11</sup> described a patient with a PBHAGL and a reverse osseous Bankart lesion. They suggested that this could be considered an osseous variation of the floating PIGHL lesion defined by Bui-Mansfield et al.

To our knowledge, ours is the first reported case of this specific combination of shoulder pathology (a posterior osseous Bankart lesion and a PHAGL lesion), and we suggest that

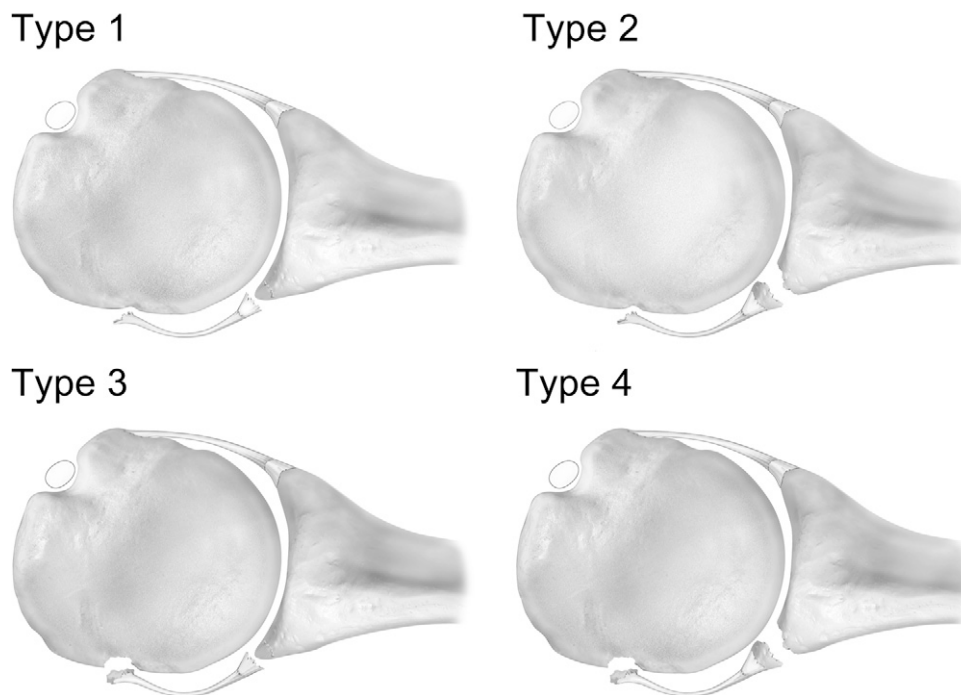


Fig. 3


Floating PIGHL subtypes. Type 1: PHAGL with a posterior Bankart lesion. Type 2: PHAGL with a posterior osseous Bankart lesion. Type 3: PBHAGL with a posterior Bankart lesion. Type 4: PBHAGL with a posterior osseous Bankart lesion. + signifies soft-tissue pathology; \* signifies bone pathology.

the floating PIGHL has four distinct pathoanatomic subtypes (Fig. 3). On the basis of our suggested nomenclature, we believe that this case is the first reported type-2 floating PIGHL.

In a recent biomechanical analysis, Wellmann et al.<sup>14</sup> noted that posterior Bankart lesions and PHAGL lesions both have a substantial biomechanical impact on posterior shoulder instability. Combined injuries had greater posteroinferior instability, and the authors suggested that both lesions should be addressed during surgical repair. The reported recurrence rate following surgical treatment of posterior glenohumeral instability is substantially higher than that following surgical treatment of anterior instability<sup>15</sup>. The cause of this is likely multifactorial. We suggest that the lack of success of some posterior stabilization procedures may have been the result of missed floating lesions. In our case, the posterior osseous Bankart lesion was identified preoperatively on imaging studies, but the posterior avulsion of the glenohumeral ligament was only seen on the MRI retrospectively. Our system encourages the complete evaluation of the posterior band of the inferior glenohumeral ligament by both the radiologist and the arthroscopist to restore proper anatomy to both sides of the ligament at

the time of surgery. Surgeons may also find pathoanatomic subtyping helpful for preoperative planning, as some may find surgical repair of certain types of lesions easier in the lateral rather than the beach-chair position and vice versa. Our proposed pathoanatomic subtyping system would ideally raise awareness of the variable injury patterns and ultimately lead to more complete treatment of patients with this pathologic condition.

### Appendix

 An arthroscopic video of the key steps of the operation is available with the online version of this article as a data supplement at [jbjs.org](http://jbjs.org). ■

James B. Ames, MD, MS  
Peter J. Millett, MD, MSc  
Steadman Philippon Research Institute,  
181 West Meadow Drive,  
Suite 1000, Vail, CO 81657.  
E-mail address for P.J. Millett: [drmillett@steadmanclinic.net](mailto:drmillett@steadmanclinic.net)

### References

- Perthes G. Über operationen bei habitueller schulterluxation. *Deutsche Z Chir.* 1906;85:199-227.
- Bankart ASB. The pathology and treatment of recurrent dislocation of the shoulder-joint. *Br J Surg.* 1938;26:23-9.
- Reeves B. Recurrent posterior dislocation of the shoulder (two cases). *Proc R Soc Med.* 1963;56:897-8.
- Bradley JP, Tejwani SG. Arthroscopic management of posterior instability. *Orthop Clin North Am.* 2010;41:339-56.
- Abrams JS. Arthroscopic repair of posterior instability and reverse humeral glenohumeral ligament avulsion lesions. *Orthop Clin North Am.* 2003;34:475-83.
- Safran O, DeFranco MJ, Hatem S, Iannotti JP. Posterior humeral avulsion of the glenohumeral ligament as a cause of posterior shoulder instability. A case report. *J Bone Joint Surg Am.* 2004;86:2732-6.
- Bui-Mansfield LT, Banks KP, Taylor DC. Humeral avulsion of the glenohumeral ligaments: the HAGL lesion. *Am J Sports Med.* 2007;35:1960-6.
- Hill JD, Lovejoy JF Jr, Kelly RA. Combined posterior Bankart lesion and posterior humeral avulsion of the glenohumeral ligaments associated with recurrent posterior shoulder instability. *Arthroscopy.* 2007;23:327.e1-3.
- Castagna A, Snyder SJ, Conti M, Borroni M, Massazza G, Garofalo R. Posterior humeral avulsion of the glenohumeral ligament: a clinical review of 9 cases. *Arthroscopy.* 2007;23:809-15.
- Pokabla C, Hobgood ER, Field LD. Identification and management of "floating" posterior inferior glenohumeral ligament lesions. *J Shoulder Elbow Surg.* 2010;19:314-7.
- Chen L, Keefe D, Park J, Resnick D. Posterior bony humeral avulsion of glenohumeral ligament with reverse bony Bankart lesion. *J Shoulder Elbow Surg.* 2009;18:e45-9.
- Lintner SA, Levy A, Kenter K, Speer KP. Glenohumeral translation in the asymptomatic athlete's shoulder and its relationship to other clinically measurable anthropometric variables. *Am J Sports Med.* 1996;24:716-20.
- Dugas JR, Campbell DA, Warren RF, Robie BH, Millett PJ. Anatomy and dimensions of rotator cuff insertions. *J Shoulder Elbow Surg.* 2002;11:498-503.
- Wellmann M, Blasig H, Bobrowitsch E, Kobbe P, Windhagen H, Petersen W, Bohnsack M. The biomechanical effect of specific labral and capsular lesions on posterior shoulder instability. *Arch Orthop Trauma Surg.* 2011;131:421-7.
- Forsythe B, Ghodadra N, Romeo AA, Provencher MT. Management of the failed posterior/multidirectional instability patient. *Sports Med Arthrosc.* 2010;18:149-61.