

Orthop Traumatol 2011 · 23:29–36  
DOI 10.1007/s00064-010-0011-9  
Online publiziert: 18. Februar 2011  
© Springer-Verlag 2011

**Redaktion**

S. Rammelt, Dresden

**Zeichnungen**

R. Himmelhan, Heidelberg

S. Braun<sup>1</sup> · M.P. Horan<sup>2</sup> · P.J. Millett<sup>3</sup>

<sup>1</sup> Abt. Sportorthopädie, Klinik für Orthopädie und Unfallchirurgie,  
Klinikum rechts der Isar, Technische Universität München

<sup>2</sup> Steadman Philippon Research Institute, Vail

<sup>3</sup> Steadman Clinic, Vail

# Open reconstruction of the anterior glenohumeral capsulolabral structures with tendon allograft in chronic shoulder instability

## Introductory remarks

Multiple etiologic aspects need to be considered in determining the correct approach to treat recurrent shoulder instability [2, 6, 7]. No other joint is as prone to dislocations as the shoulder, with more than one third of all shoulder injuries being dislocations. The shoulder joint dislocates as often as all other joints together [21]. Trauma is the most common reason for glenohumeral instability, whereas congenital instability is less frequently seen. Anterior shoulder instability secondary to traumatic dislocations as well as traumatic redislocations can be successfully addressed by arthroscopic surgery. Patient selection, surgical technique, and skills are vital for procedural success.

For most cases of anterior shoulder instability, arthroscopic capsular shift and Bankart repair are the appropriate procedure. Arthroscopic implants and techniques have evolved in the past decade, making the results equal to those of open procedures [5]. Particularly in cases of bone loss due to traumatic dislocations or bony deficiencies, such as abnormal retro- or anteversion of the glenoid, or in case of multiple failed arthroscopic procedures, open procedures are still preferred [14, 18, 22]. The failure rate of both arthroscopic and open surgery, particularly in case of traumatic dislocation, is low, leaving those patients experiencing recurrent dislocations as a challenge to surgeons. Deficiency of the subscapu-

laris tendon, the capsule, and the important enforcing structures (i.e., the middle glenohumeral ligament (MGHL) and the anterior band of the inferior glenohumeral ligament (IGHL)) can be observed after multiple (open) surgical attempts to stabilize the joint or as a complication of electrothermal capsulorrhaphy [9, 24]. Surgical attempts aim at reducing the patient's disability; however, a possible secondary benefit—to decrease the risk of early glenohumeral osteoarthritis—has yet to be proven [4].

There are two surgical principles for open procedures: anatomic and nonanatomic techniques. Anatomic techniques for open shoulder stabilization include various techniques for capsular shifts and the classic Bankart repair.

Nonanatomic approaches are usually more invasive and can make further revision surgery more difficult because of the loss of anatomical landmarks. Nonetheless, the Bristow–Latarjet technique (i.e., a transfer of the coracoid process [10, 13]), various techniques to address bone loss (e.g., glenoid reconstruction with an iliac crest bone graft [22]), and procedures addressing bone deficiencies of the humeral head (e.g., Hill–Sachs lesions) by bone grafting can successfully eliminate instability in many cases [18].

Patients without bony defects or abnormalities, who still experience severe instability after multiple attempts to tighten the joint by capsular shifts or capsulorrhaphy, have deficient stabilizing capsu-

lolabral soft tissue structures. These can be divided in intrinsic soft tissue/collagen disorders (e.g., Ehlers–Danlos or extrinsic capsule) and labral disorders in the setting of multiple surgical procedures or electrothermal capsular necrosis. There are techniques for capsulolabral reconstruction described using hamstrings [13, 23], iliotibial (IT) band [8, 11], and Achilles tendon grafts [19]. This manuscript describes our technique for anatomic capsulolabral reconstruction with a tibialis anterior allograft as a salvage procedure for end-stage glenohumeral instability due to capsular insufficiency (partially reported previously in [3]).

## Surgical principle

**Open reconstruction of the anterior shoulder capsule and the glenohumeral ligaments with an tendon allograft.**

## Advantages

- Salvage procedure for chronic recurrent anterior instability
- Reconstruction of the anterior labrum
- Reconstruction of the MGHL and anterior band of IGHL
- Open exposure allows selective and secure tensioning of the allograft
- Increase of the depth of the cavity by recreating the anterior labrum
- Procedure can avoid much more invasive and ultimate glenohumeral fusion

- Alternative use of tendon autograft possible (e.g., semitendinosus tendon)

## Disadvantages

- Salvage procedure only for selected cases
- Invasive approach
- Loss of range-of-motion
- Use of allograft (alternatively autograft)

## Indications

- Salvage procedure for chronic anterior instability and recurrent dislocations in patients with multiple previous surgical attempts to achieve stabilization
- Capsulolabral deficiency without associated bone loss
- Loss of labral structures after multiple dislocations and/or surgical attempts of labral reconstruction
- Soft tissue disorders (e.g., Ehlers-Danlos syndrome) or defects (e.g., electrothermal capsular necrosis) with anterior or anterior-inferior instability

## Contraindications

- Relevant bone loss at the anterior-inferior glenoid rim
- Large and engaging Hill-Sachs defects
- Increased ante- or retroversion of the glenoid

- Bony glenoid anomalies

## Patient information

- General surgical risks: infection of the wound, deep wound infection, embolism, thrombosis, injury of neurovascular structures
- Salvage procedure for 'end-stage' instability
- Risk of infection by using allograft
- If autograft is used: donor site morbidity
- Persisting instability of the shoulder
- Loss of maximum external rotation
- Stiffness of the glenohumeral joint
- Postoperative physical therapy
- Arm sling for 6 weeks
- Return to work/full activity at 4–6 months postoperatively

## Preoperative work-up

- Meticulous clinical evaluation of type of instability:
  - Positive sulcus sign in neutral and external rotation of the arm
  - Severe positive apprehension
  - Grade 3 anterior-posterior translation and load and shift test
  - General joint laxity
- History includes subluxation or dislocation without adequate trauma (e.g., while sleeping)
- Testing for soft tissue disorders (collagen deficiencies, e.g., Ehlers-Danlos syndrome)

- Clinical assessment of rotator cuff and biceps tendon pathologies
- MRI studies
- CT scans when indicated to define bony anatomy and rule out possible bone loss [16, 22]

## Surgical instruments and implants

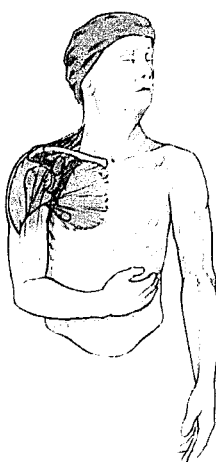
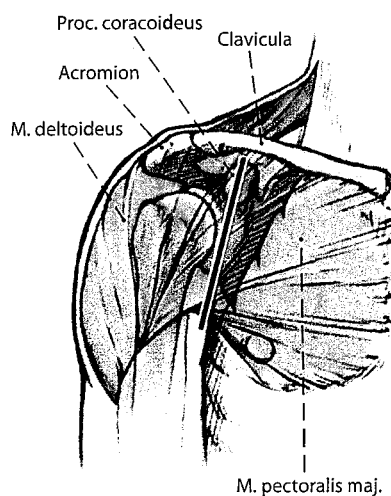
- Appropriately sized allograft tendon; the tibialis anterior tendon is preferred by the authors
- Autograft may be considered (hamstrings)
- Beach-chair table and pneumatic arm holder
- Shoulder self retractor (e.g., Mitek shoulder self retractor frame)
- Fukuda retractor
- Glenohumeral arthroscopy in cases with clinical or radiographic evidence for additional intraarticular pathologies or suspicion of an engaging Hill-Sachs defect prior to the open procedure

## Anesthesia and positioning

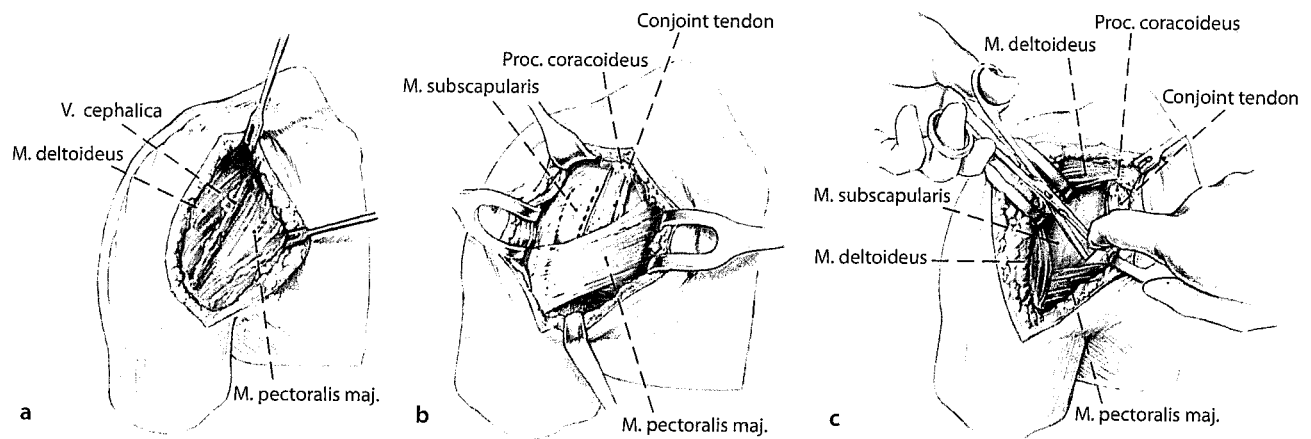
- Beach-chair position (with pneumatic arm holder, if available)
- General anesthesia
- Additional regional anesthesia preferable

## Surgical technique

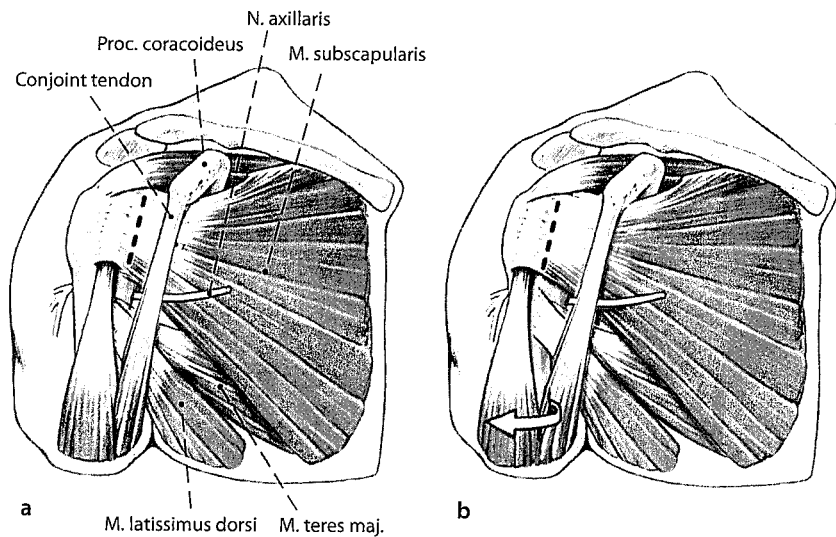
The surgical technique is illustrated in **Fig. 1, 2, 3, 4, 5, 6, 7, and Fig. 8.**



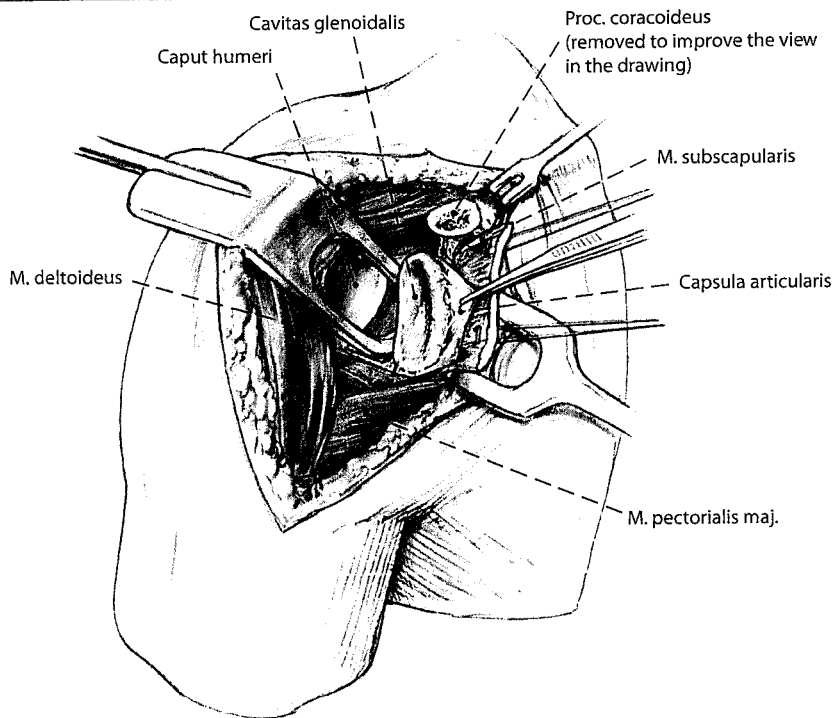
**Fig. 1** ◀ A standard deltopectoral approach is performed to expose the glenohumeral joint. The incision length is about 10–12 cm. In many cases, there is extensive scarring and altered soft tissue planes, which makes the approach more difficult. The cephalic vein is the anatomic landmark that helps identify the deltopectoral interval, usually it is protected with a Langenbeck retractor and taken laterally



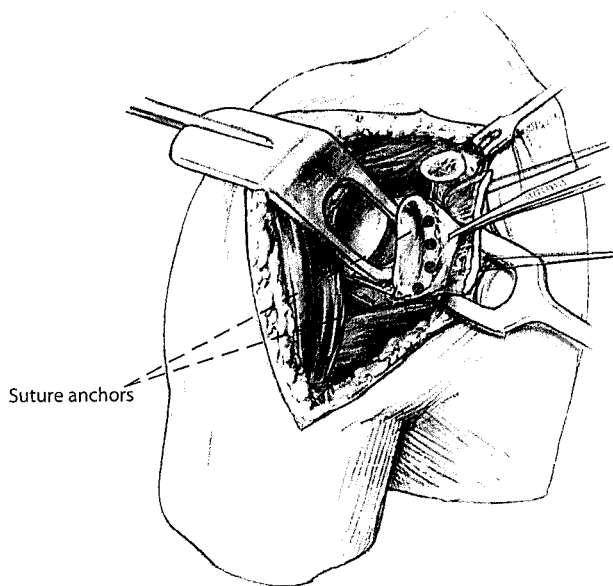
**Fig. 2 ▲** After blunt dissection of the interval (a), the conjoint tendon is the next leading structure (b). It needs to be retracted medially with the pectoralis major muscle (c). At this point use of a shoulder self retractor can be helpful. We prefer to open the bicipital groove and tenodeses the long head of the biceps, as the long head of the biceps tendon can be a postoperative source of pain especially in this patient population with multiple previous surgeries



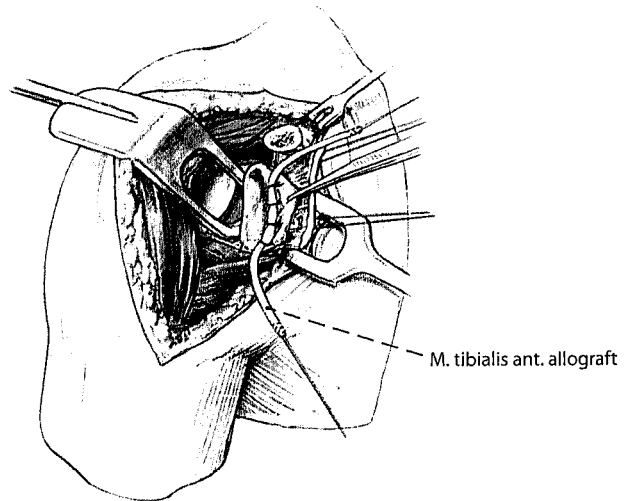
**Fig. 3 ▲** The subscapularis tendon can then be taken down from the insertion at the lesser tuberosity with the capsule in one layer (a). This simplifies the exposure. In many cases, the capsule is attached to the subscapularis. In these cases, it is necessary to incise and mobilize the subscapularis tendon and the anterior joint capsule at once. We prefer cutting the subscapularis tendon leaving about 5 mm of the tendon laterally for later repair. The subscapularis tendon is secured with strong sutures for later repair, and sutures are placed through drill holes in the bone for transosseous repair of the subscapularis tendon. Care should be taken to avoid injury to the axillary nerve, which passes inferiorly to the subscapularis tendon through the quadrangular space. External rotation of the arm may be helpful to tension and identify the tendon and to increase the distance from the incision line to the axillary nerve (b)



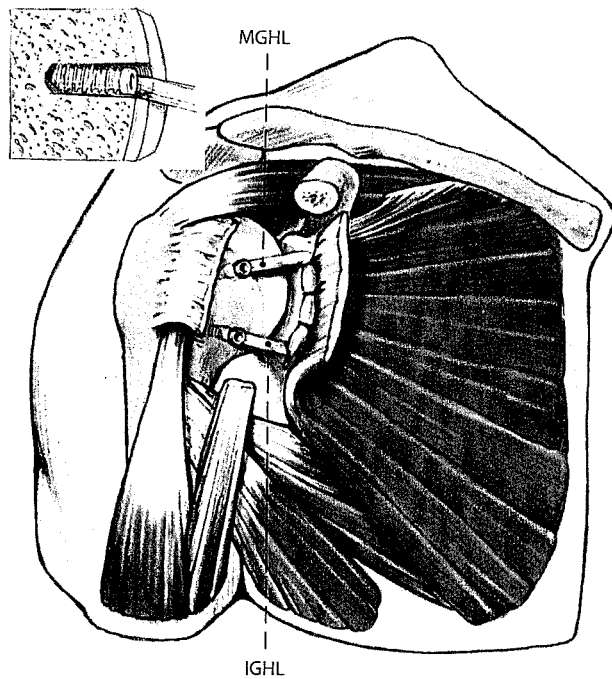
**Fig. 4 ▲** Full exposure of the glenohumeral joint is achieved by opening the rotator interval and retraction of the humeral head with a Fukuda retractor



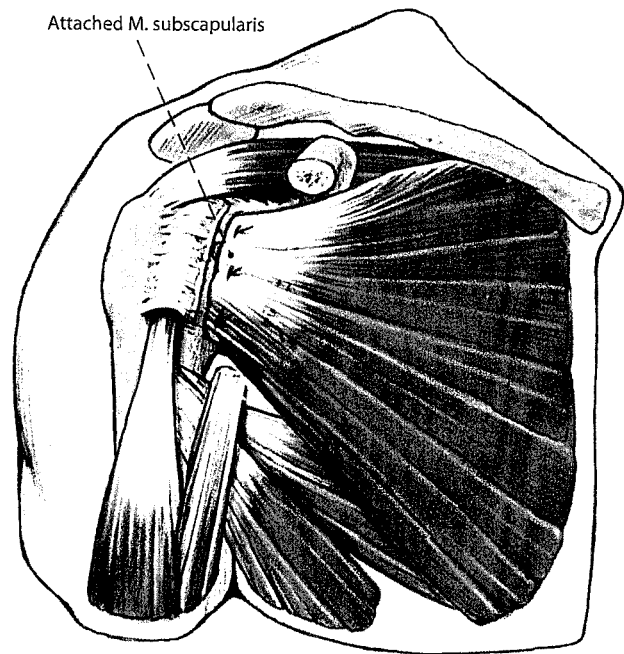
**Fig. 5 ▲** Reconstruction of the labrum. Good exposure of the glenoid is vital for the procedure. The glenoid neck and anterior rim is prepared with a burr to free the bone from any residual soft tissue and labrum, which allows better healing and fixation of the graft. Four or preferably four suture anchors are used as points of fixation of the labral reconstruction at the anterior glenoid rim, placed at the 2:00, 3:00, 4:00, and 5:30 o'clock positions



**Fig. 6 ▲** A tibialis anterior allograft with a diameter of 6–7 mm, which has been whipstitched at either end with Fiberwire (Arthrex, Naples, FL) or comparably strong sutures, is placed along the anterior glenoid rim to reconstruct the labrum. It is then secured with the anchor sutures starting at the middle and working superiorly and inferiorly. The tibialis anterior allograft nicely recreates the anterior labrum



**Fig. 7 ▲** Reconstruction of the anterior joint capsule. The medial glenohumeral ligament (MGHL) and the anterior band of the inferior glenohumeral ligament (IGHL) are reconstructed using the two free limbs of the allograft. The graft will be secured by bioabsorbable interference screws at both ends laterally in bone tunnels. The tunnels should be at the articular margin on the humerus where the native capsule attaches. The drill's diameter for the tunnel should be chosen according to the graft so that the interference screw provides good compression of the tendon in the bone tunnel. One tunnel is created for each limb of the allograft inferiorly and superiorly. The free superior and inferior limbs of the graft will be appropriately sized in length for adequate tensioning and finally fixed at the humerus with two bioabsorbable interference screws (BioTenodesis screw, Arthrex, Naples, FL) in bone tunnels. Correct tension of the allograft should allow about 30° of external rotation and fixation should be performed in about 30° of elevation. The technique of fixation is similar to that used for tenodesis of the long head of the biceps [1, 15, 17, 20]. Alternatively, to the two blind ended tunnels, one superior and one inferior complete tunnel can be created so that they span the bicipital groove. The graft ends can then be passed through each tunnel respectively, tensioned, and tied to themselves lateral to the bicipital groove. In this case, the knot needs to be secured with suture stitches. Note that the knot can be prominent and thus cause irritation. The remaining native capsular structures are sewn into the allograft with #2 Ethibond sutures to reinforce the neolabrum for additional security. This also brings in vascularity to help with healing and graft incorporation



**Fig. 8 ▲** Before reattaching the subscapularis tendon to the bone, stability can be tested intraoperatively and the tension free range of motion should be noted for the postoperative protocol. The subscapularis tendon and the adherent underlying capsule are then meticulously repaired to the lesser tuberosity through bone tunnels and directly to the allograft. The rotator interval is then closed in a pants-over-vest fashion to provide additional resistance against inferior translation. The remainder of the wound is closed layer by layer in standard fashion

Orthop Traumatol 2011 · 23:29–36 DOI 10.1007/s00064-010-0011-9  
© Springer-Verlag 2011

S. Braun · M.P. Horan · P.J. Millett

### Open reconstruction of the anterior glenohumeral capsulolabral structures with tendon allograft in chronic shoulder instability

#### Abstract

**Objective.** The presented technique aims at reconstruction of the anterior capsulolabral structures of the glenohumeral joint in the case of recurrent severe instability after multiple surgical attempts to achieve stabilization.

**Indications.** The procedure is indicated for patients experiencing significant lifestyle-limiting recurrent shoulder instability with etiologic soft tissue deficiency.

**Contraindications.** Bony defects or abnormalities can not be addressed with the index technique.

**Surgical technique.** A standard deltopectoral approach with lateral incision of the subscapularis tendon is used for exposure to prepare the anterior glenoid rim. Suture anchors placed at the glenoid rim are used for

fixation of a tibialis anterior tendon allograft, which is tightened and fixed to the bone on the humerus with interference screws. This recreates the anterior labrum and the middle glenohumeral ligament and the anterior band of the inferior glenohumeral ligament. Intraosseous repair of the subscapularis tendon and reinforcement of the capsular structures by sewing the capsule into the allograft complete the procedure.

**Postoperative management.** Postoperatively, the use of an arm sling is recommended for 6 weeks with limited physical exercises to avoid stretching the tightened and reconstructed soft tissue structures.

**Results.** The results of this salvage procedure in this highly challenging population have been satisfying. Twenty shoulders in 15

patients were operated (3 male, 12 female, average age 26 years) from July 2002 to April 2008. In 14 of the 20 (70%) shoulders, adequate stability was gained and no further surgery was required. The average ASES score increased by 37 points at a mean follow-up of 37 months (range 22–74 months). Mean satisfaction with surgical outcomes was 6.5 points (max. 10). In 5 patients, 6 shoulders were considered failures and required further surgical treatment after a mean of 9 months (range 3–24 months).

#### Keywords

Orthopedic procedures · Open capsulolabral reconstruction · Allograft · Shoulder dislocation · Glenohumeral instability

### Offene vordere Kapsel-Band-Rekonstruktion der Schulter mit einem Sehnenallograft bei chronischer Instabilität

#### Zusammenfassung

**Operationsziel.** Wiederherstellung der ventralen Kapsel-Band-Strukturen des glenohumeralen Gelenks mit einem allogenen Sehnentransplantat bei Patienten mit schwerwiegender rezidivierender Instabilität nach mehrfach fehlgeschlagenen operativen Stabilisierungsversuchen.

**Indikationen.** Schulterinstabilität mit erheblicher Einschränkung der Lebensqualität und hohem Leidensdruck bei Insuffizienz des Weichteilgewebes.

**Kontraindikationen.** Schulterinstabilität durch knöcherne Defekte oder Anomalitäten, z. B. Anteversion des Glenoids.

**Operationstechnik.** Darstellung des vorderen Glenoidrands über einen deltoideopektoralen Standardzugang mit lateraler Inzision der Subscapularissehne. Einbringen von Fadenankern an der Glenoidkante zur Fixierung eines allogenen Trans-

plantats der Tibialis-anterior-Sehne. Spannen des Transplantats und Fixation am Humerus mit Interferenzschrauben. Dadurch wird das vordere Labrum, das mittlere glenohumerale Ligament und das anteriore Band des inferioren glenohumeralen Ligamentes rekonstruiert. Die ventralen Strukturen werden durch Vernähen der Kapsel mit dem Allograft und durch transossäre Refixation der Subscapularissehne zusätzlich verstärkt.

**Weiterbehandlung.** Zur Nachbehandlung wird für 6 Wochen eine Armschlinge empfohlen. Mit Physiotherapie soll das Einsteifen des Gelenks verhindert, dabei ein Aufdehnen der operativ rekonstruierten und gestrafften Kapsel-Band-Strukturen jedoch vermieden werden.

**Ergebnisse.** Die Ergebnisse der vorgestellten Salvage-Operation bei komplizierter Ausgangssituation sind durchweg zufriedenstel-

lend. Im Zeitraum von Juli 2002 bis April 2008 wurden 20 Schultern (15 Patienten, 3 männlich, 12 weiblich, Durchschnittsalter 26 Jahre) operiert. Bei 14 Schultern (70%) wurde eine adäquate Stabilität erreicht; sie mussten nicht nochmals operiert werden. Der ASES-Score stieg nach durchschnittlich 37 Monaten um 37 (22–74) Punkte. Die durchschnittliche Zufriedenheit mit dem Ergebnis wurde mit 6,5 von 10 Punkten bewertet. Bei 5 Patienten (6 Schultern) wurde die Behandlung nach 9 (3–24) Monaten als Fehlschlag angesehen, was eine weitere operative Therapie erforderte.

#### Schlüsselwörter

Orthopädische Verfahren · Kapsel-Band-Rekonstruktion · Allograft · Schulterinstabilität · Glenohumerale Instabilität

## Postoperative management

- Arm sling for 6 weeks to allow healing of the soft tissue and secure ingrowth of the tendon on the bony tunnels [12]
- Pendulum exercises and limited passive range-of-motion start at 4 weeks
- No forceful external rotation training
- Physical therapy aims at 45° of external rotation and 140° forward flexion
- Active range-of-motion starts in week 8–10
- Postoperative follow-up visits at weeks 2 and 6
- Return to maximum function at 4–6 months

## Errors, hazards, complications

- Infection: revision, removal of implants and graft
- Persisting recurrent instability: conversion to fusion
- Insufficiency of subscapularis tendon repair: revision with subscapularis tendon repair
- Glenohumeral stiffness, although some stiffness is desirable and aspired: physical therapy, revision surgery
- Pullout of interference screws with subsequent failure of the stabilizing structures of the procedure (not observed in our patients so far): revision surgery to reinsert the graft with larger diameter screws

## Results

There were 15 patients operated with 20 surgical shoulder reconstructions (3 men, 12 women, average age 26 years) from July 2002 to April 2008 in the described technique by the senior author (Millett JP et al., unpublished data, 2010, [3]). All were faced with choosing among arthrodesis, salvage stabilization procedure, or living with permanent disability. Of the 20 shoulders, 14 (70%) gained adequate stability and required no further surgery: the average ASES score increased 37 points at a mean of 37 months (range 22–74 months). Mean satisfaction with surgical outcomes was 6.5 of 10 points. In 5 patients, 6 shoulders were

considered failures and progressed to further surgical treatment after a mean of 9 months (range 3–24 months). One had an early postoperative infection and was revised once infection resolved, and after 45 months reported no feeling of instability and was very satisfied. One patient had an avulsion of the graft from the humeral reinsertion site during early rehabilitation. The 2 others experienced recurrent instability even after the index procedure and after completing 6-month rehabilitation. Therefore, 1 patient had to undergo an additional Latarjet procedure, to add a bony fulcrum, and 1 patient had to ultimately be converted to a glenohumeral fusion.

## Corresponding address

Dr. P.J. Millett

Steadman Clinic

181 West Meadow Drive, Suite 1000, 81657 Vail, CO, USA

drmillett@steadmanclinic.net

**Conflict of interest.** The corresponding author states that one or more authors has declared a potential conflict of interest: Dr. Millett is a consultant to Arthrex and Arthrocare. He receives royalties from Arthrex and has stock options in Game Ready, Inc. and VuMedi. Dr. Braun's position as a research scholar at the Steadman Philippon Research Institute (SPRI) was generously sponsored by Arthrex, Naples, FL. All authors received indirect financial support from the SPRI. Companies that have supported the SPRI are Arthrocare, Arthrex, Orthorehab, Ossur, Siemens, and Smith & Nephew.

## References

1. Boileau P, Krishnan SG, Coste JS et al (2002) Arthroscopic biceps tenodesis: a new technique using bioabsorbable interference screw fixation. *Arthroscopy* 18(9):1002–1012
2. Bosch U, Lobenhoffer P, Blauth M (1998) Die Rekonstruktion des Labrum glenoidale und der Capsula articularis nach Jobe bei vorderer Schulterinstabilität. *Oper Orthop Traumatol* 10(3):159–168
3. Braun S, Millett PJ (2008) Open anterior capsular reconstruction of the shoulder for chronic instability using a tibialis anterior allograft. *Tech Shoulder Elbow Surg* 9:102–107
4. Cameron ML, Kocher MS, Briggs KK et al (2003) The prevalence of glenohumeral osteoarthritis in unstable shoulders. *Am J Sports Med* 31(1):53–55
5. Cole BJ, L'Insalata J, Irrgang J et al (2000) Comparison of arthroscopic and open anterior shoulder stabilization. A two to six-year follow-up study. *J Bone Joint Surg Am* 82-A(8):1108–1114
6. Flatow EL, Miniaci A, Evans PJ et al (1998) Instability of the shoulder: complex problems and failed repairs: Part II. Failed repairs. *Instr Course Lect* 47:113–125
7. Flatow EL, Warner JJ (1998) Instability of the shoulder: complex problems and failed repairs: Part I. Relevant biomechanics, multidirectional instability, and severe glenoid loss. *Instr Course Lect* 47:97–112
8. Gallie WE, LeMesurier AB (1948) Recurring dislocation of the shoulder. *J Bone Joint Surg Br* (30):9–18
9. Hawkins RJ, Krishnan SG, Karas SG et al (2007) Electrothermal arthroscopic shoulder capsulorrhaphy: a minimum 2-year follow-up. *Am J Sports Med* 35:1484–1488
10. Hovelius L, Sandstrom B, Saebo M (2006) One hundred eighteen Bristow-Latarjet repairs for recurrent anterior dislocation of the shoulder prospectively followed for fifteen years: study II—the evolution of dislocation arthropathy. *J Shoulder Elbow Surg* 15(3):279–289
11. Iannotti JP, Antoniou J, Williams GR et al (2002) Iliotibial band reconstruction for treatment of glenohumeral instability associated with irreparable capsular deficiency. *J Shoulder Elbow Surg* 11(6):618–623
12. Kilicoglu O, Koyuncu O, Demirhan M et al (2005) Time-dependent changes in failure loads of 3 biceps tenodesis techniques: in vivo study in a sheep model. *Am J Sports Med* 33(10):1536–1544
13. Lazarus MD, Harryman DT 2nd (1997) Open repair for anterior instability. In: Warner JJ, Iannotti JP, Gerber C (eds) *Complex and revision problems in shoulder surgery*. Lippincott-Raven, Philadelphia PA, pp 47–64
14. Linters TR, Franta AK, Wolf FM et al (2007) Arthroscopic compared with open repairs for recurrent anterior shoulder instability. A systematic review and meta-analysis of the literature. *J Bone Joint Surg Am* 89(2):244–254
15. Lo IK, Burkhart SS (2004) Arthroscopic biceps tenodesis using a bioabsorbable interference screw. *Arthroscopy* 20(1):85–95
16. Lynch JR, Clinton JM, Dewing CB et al (2009) Treatment of osseous defects associated with anterior shoulder instability. *J Shoulder Elbow Surg* 18(2):317–328
17. Mazzocca AD, Rios CG, Romeo AA et al (2005) Subpectoral biceps tenodesis with interference screw fixation. *Arthroscopy* 21(7):896
18. Millett PJ, Clavert P, Warner JJ (2005) Open operative treatment for anterior shoulder instability: when and why? *J Bone Joint Surg Am* 87(2):419–432
19. Moeckel BH, Altchek DW, Warren RF et al (1993) In stability of the shoulder after arthroplasty. *J Bone Joint Surg Am* 75(4):492–497
20. Romeo AA, Mazzocca AD, Tauro JC (2004) Arthroscopic biceps tenodesis. *Arthroscopy* 20(2):206–213
21. Rowe CR (1956) Prognosis in dislocations of the shoulder. *J Bone Joint Surg Am* 38-A(5):957–977
22. Warner JJ, Gill TJ, O'Hollerhan JD et al (2006) Anatomical glenoid reconstruction for recurrent anterior glenohumeral instability with glenoid deficiency using an autogenous tricortical iliac crest bone graft. *Am J Sports Med* 34(2):205–212
23. Warner JJ, Venegas AA, Lehtinen JT et al (2002) Management of capsular deficiency of the shoulder. A report of three cases. *J Bone Joint Surg Am* 84-A(9):1668–1671
24. Wong KL, Williams GR (2001) Complications of thermal capsulorrhaphy of the shoulder. *J Bone Joint Surg Am* 83-A(Suppl 2 Pt 2):151–155