

# ARTHROSCOPIC SINGLE-ROW VERSUS DOUBLE-ROW REPAIR FOR FULL-THICKNESS POSTEROSUPERIOR ROTATOR CUFF TEARS

## A Critical Analysis Review

Kevin M. Roth, MD

Ryan J. Warth, MD

Jared T. Lee, MD

Peter J. Millett, MD, MSc

Neal S. ElAttrache, MD

*Investigation performed at The Kerlan-Jobe Orthopaedic Clinic, Los Angeles, California, and The Steadman Philippon Research Institute, Vail, Colorado*

» The vast majority of biomechanical evidence favors double-row repair and/or transosseous-equivalent double-row repair with respect to footprint contact area, footprint compression, ultimate load to failure, and gap formation for full-thickness posterosuperior rotator cuff tears.

» Studies have documented a lower rate of imaging-diagnosed rotator cuff retears when traditional double-row repair is compared with traditional single-row repair types.

» Level-I clinical outcome studies have typically failed to document a difference between single-row and double-row repairs in terms of clinical outcome measures; however, these studies are often underpowered and therefore at high risk of having a type-II error.

» The authors recommend performing a transosseous-equivalent double-row repair whenever tissue mobility permits.

Over the past two decades, arthroscopic rotator cuff repair has become one of the most popular orthopaedic surgical procedures because of its proven ability to diminish pain and improve function in patients with symptomatic rotator cuff tears. As a result of this increasing demand, arthroscopic techniques have evolved rapidly in an effort to improve structural integrity, biomechanical function, and, ultimately, clinical outcomes. With the increasing number of techniques available for the repair of full-thickness rotator cuff tears, debate has arisen regarding the clinical superiority of any one of these methods over the others.

Specifically, this debate has centered on traditional single-row versus traditional double-row repair constructs (Fig. 1). Therefore, the purpose of this article is to present a critical review of the most relevant evidence and to provide clinical care recommendations regarding arthroscopic single-row versus double-row rotator cuff repair constructs.

### Anatomic Considerations

The rotator cuff represents a confluence of four tendons that envelop the humeral head—the subscapularis, supraspinatus, infraspinatus, and teres minor tendons—all of which function in synchrony to both stabilize and compress the humeral head

**Disclosure:** None of the authors received payments or services, either directly or indirectly (i.e., via his or her institution), from a third party in support of any aspect of this work. One or more of the authors, or his or her institution, has had a financial relationship, in the thirty-six months prior to submission of this work, with an entity in the biomedical arena that could be perceived to influence or have the potential to influence what is written in this work. No author has had any other relationships, or has engaged in any other activities, that could be perceived to influence or have the potential to influence what is written in this work. The complete **Disclosures of Potential Conflicts of Interest** submitted by authors are always provided with the online version of the article.

COPYRIGHT © 2014 BY THE  
JOURNAL OF BONE AND JOINT  
SURGERY, INCORPORATED

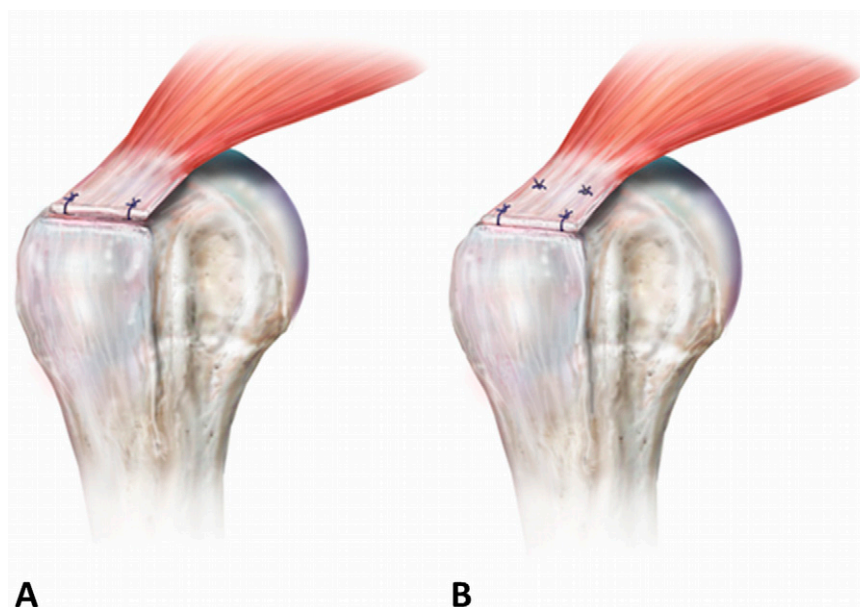


Fig. 1  
Traditional single-row suture configuration utilizes two lateral anchors tied in a simple stitch pattern (Fig. 1, A). Traditional double-row suture configuration utilizes an additional medial row of anchors with mattress stitches (Fig. 1, B).

within the glenoid fossa and to position the humerus in space. The rotator cuff tendons insert into a strong, layered fibrocartilaginous tissue matrix that makes up the footprint, or the enthesis, of the rotator cuff. This fibrocartilaginous tissue is designed to prevent tendon-footprint overloading that may ultimately result in avulsions and/or tears<sup>1</sup>.

Nevertheless, rotator cuff tears can still occur as a result of various intrinsic and/or extrinsic factors, necessitating repair of the avulsed tendon insertion to restore shoulder function. Although a repaired tendon insertion is known to be biomechanically inferior to the native insertion, healing of the anatomic insertion is important—regardless of whether a single-row or double-row technique is used—in order to alleviate pain and restore function. Therefore, a thorough understanding of rotator cuff anatomy is critical to recognizing common tear patterns and thus choosing the ideal repair construct that will adequately restore the rotator cuff footprint and result in favorable outcomes<sup>2</sup>. This is especially true for the more common posterosuperior cuff tears, as this is the area where the controversy between

traditional single-row and double-row repair exists.

The greater tuberosity has been described as having three insertional facets (superior, middle, and inferior) upon which the supraspinatus, infraspinatus, and teres minor tendons attach. The supraspinatus tendon inserts upon the most anterior aspect of the superior facet. Moving posteriorly, the fibers of the supraspinatus eventually blend with those of the infraspinatus on the middle facet, creating difficulty in identifying the interval between the two tendons. As the contribution from the supraspinatus tendon diminishes, the middle facet then contains tendon fibers solely arising from the infraspinatus muscle. The teres minor inserts upon the most inferior facet of the greater tuberosity and is only involved in the repair of massive rotator cuff tears.

Reported dimensions of the individual footprints of the posterosuperior cuff tendons have been inconsistent to date (Table I)<sup>3-9</sup>. Dugas et al.<sup>6</sup> quantified the insertional anatomy of the posterosuperior cuff in both the sagittal and coronal planes. In their study, the most medial aspect of each tendon insertion was consistently <1 mm lateral to the

articular margin. In addition, no correlation was found between the size of the humeral head and the dimensions of the insertion sites.

Curtis et al.<sup>8</sup> also described the insertional dimensions of the posterosuperior cuff. The coronal lengths reported by Curtis et al.<sup>8</sup> are approximately double those reported earlier by Dugas et al.<sup>6</sup>, whereas their respective sagittal lengths are similar. Since both studies reported that the medial edge of the footprint arose just lateral to the articular margin, it is possible that differences in coronal lengths may be due to differences in measurements regarding the lateral extension of each tendon insertion.

More recently, Mochizuki et al.<sup>9</sup> also described the dimensions of the posterosuperior cuff, specifically noting much smaller insertional dimensions of the supraspinatus compared with what had previously been reported. The footprint was described as a right triangle, with the base of the triangle along the humeral articular cartilage and the height of the triangle bordering the bicipital groove (Fig. 2). This difference is most likely due to subtraction of the joint capsule insertion, which can be

TABLE I Reported Dimensions of the Posterosuperior Cuff Insertion\*

Author, Year	Footprint Dimensions†	
	Supraspinatus	Infraspinatus
Minagawa et al. <sup>3</sup> , 1998	NR × 22.5	NR × 14.1
Roh et al. <sup>4</sup> , 2000	NR × 21.2	NR
Volk and Vangness <sup>5</sup> , 2001	27.9 × NR	NR
Dugas et al. <sup>6</sup> , 2002	12.7 × 16.3	13.4 × 16.4
Ruotolo et al. <sup>7</sup> , 2004	NR × 25	NR
Curtis et al. <sup>8</sup> , 2006	23 × 16	29 × 19
Mochizuki et al. <sup>9</sup> , 2008	6.9 × 12.6	10.2 × 32.7

\*NR = Not reported. †Mean coronal length × mean sagittal length in mm.

up to 4.5 mm in coronal width. Surprisingly, in their dissection of 113 cadaveric shoulders, 21% of supraspinatus tendons had a small area of insertion on the lesser tuberosity, contributing to the roof that covers the bicipital groove.

Mochizuki et al.<sup>9</sup> also reported the insertional dimensions of the infraspinatus and found it to be much larger than previously reported. Of note, the investigators found that the infraspinatus footprint extended anterolaterally to the posterior edge of the bicipital groove. This anterolateral extension suggests that involvement of the infraspinatus tendon in rotator cuff tears may be more common than has previously been reported<sup>10</sup>.

### Single-Row Versus Double-Row Repair: Biomechanical Evidence

After repair of the rotator cuff footprint, tendon healing initially begins with the

formation of fibrovascular tissue between the substance of the repaired tendon and the osseous footprint<sup>11</sup>. With time, osteoblasts lay woven bone that extends into this fibrovascular interface, eventually evolving into a continuous fibrous matrix containing tendon, bone, and scar tissue that anchors the tendon substance into the osseous infrastructure<sup>12</sup>. The potential for healing relies upon adequate footprint contact area and compression of the repair construct to aid in the formation of this fibrous tissue matrix; therefore, repair techniques that improve footprint contact and pressure are thought to improve the structural integrity of the healed repair.

### Footprint Contact Area

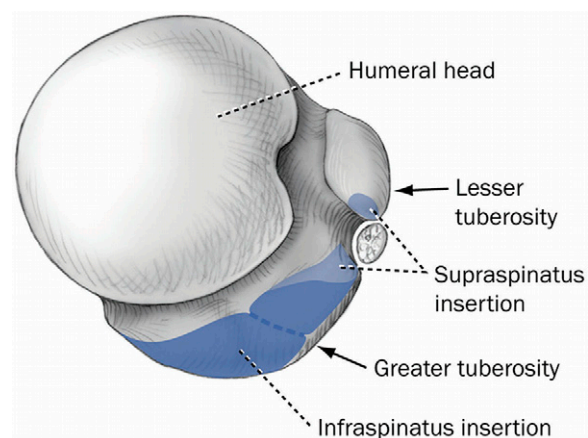
Restoration of footprint contact area is necessary to prevent retears or healing failure after rotator cuff repair<sup>13</sup>. Several biomechanical studies have found that

double-row repairs result in substantially increased contact area when compared with single-row repairs. Tuoheti et al.<sup>14</sup> found double-row repairs to improve contact areas by as much as 60% over single-row repairs. Using three-dimensional mapping, Meier and Meier<sup>15</sup> found that double-row constructs restored 100% of the native footprint whereas the single-row technique restored only 46% of the native footprint. Mazzocca et al.<sup>16</sup> also found that double-row repairs resulted in significantly improved contact areas over single-row repairs.

### Footprint Compression

Extrapolating from data from the knee, compression of the tendon to bone may theoretically facilitate increased quality and quantity of tendon-to-bone healing<sup>11,17</sup>. Park et al.<sup>18</sup> postulated that these results could be applied to repair

Fig. 2  
Posterosuperior cuff insertion sites as described by Mochizuki et al.<sup>9</sup>. (Reproduced from Mochizuki T, Sugaya H, Uomizu M, Maeda K, Matsuki K, Sekiya I, Muneta T, Akita K. Humeral insertion of the supraspinatus and infraspinatus. New anatomical findings regarding the footprint of the rotator cuff. *Surgical Technique. J Bone Joint Surg Am.* 2009 Mar 1;91 Suppl 2 Pt 1:1-7.)



of the rotator cuff tendons such that increased tendon-footprint compression may result in improved healing after rotator cuff repair. A follow-up study by Park et al.<sup>19</sup> evaluated the footprint contact characteristics for various single-row and double-row suture configurations. Using pressure monitors to measure contact pressures over the supraspinatus footprint, they found that single-row constructs repeatedly provided less footprint compression forces than double-row constructs did.

#### **Ultimate Load to Failure**

Repairs must also withstand the forces that are typically applied to the rotator cuff tendons with postoperative rehabilitation. Hughes and An<sup>20</sup> measured the maximal contraction forces exerted by the normal supraspinatus and infraspinatus tendons. In abduction and external rotation, the supraspinatus exerted a force of approximately 175 N whereas the infraspinatus exerted a force of greater than 900 N. These results have important implications in rotator cuff repairs: those tears that extend into the infraspinatus tendon will exert a much greater force on the repair construct in the early postoperative period than will those that are isolated to the supraspinatus tendon.

Several biomechanical studies have evaluated the ultimate load-to-failure of various rotator cuff repair constructs. Waltrip et al.<sup>21</sup> used cyclic loading to compare single-row and double-row construct strength. In their study, single-row repair with simple sutures failed after a mean of 1414 cycles as compared with the double-row repair, which failed after a mean of 3694 cycles. Gerber et al.<sup>22</sup> found a 23% increase in ultimate load to failure in double-row repairs (336 N) versus single-row repairs (273 N). Smith et al.<sup>23</sup> found a 42% increase in ultimate load to failure after cyclic loading in double-row repairs (320 N) versus single-row repairs (224 N). Similarly, Kim et al.<sup>24</sup> found a 48% increase in ultimate load-to-failure in double-row repairs versus single-row repairs. The limitations of these studies arise from the fact that the testing methods of each study

involved a single loading vector. Ahmad et al.<sup>25</sup> followed by evaluating the strength of different suture configurations at various angles of humeral abduction and rotation. They also found that double-row repairs were stronger in all tested positions.

Maximum strength of the repair construct is most important in the immediate postoperative period, before healing has taken place. Mazzocca et al.<sup>16</sup> found that a time-zero load to failure of greater than 250 N can withstand rehabilitation with passive range of motion. However, no minimum repair strength has been critically assessed with regard to healing rates and/or retear rates.

#### **Gap Formation**

The potential for gap formation—the development of increased space between the tendon-bone interface—is also a predictor of poor rotator cuff healing owing to decreased repair strength and decreased footprint compression. Smith et al.<sup>23</sup> found that gap formation after static loading was more frequent after single-row repairs than after double-row repairs. Kim et al.<sup>24</sup> found that single-row repairs resulted in a gap of 7.64 mm compared with double-row constructs, which resulted in a gap of 3.58 mm. Milano et al.<sup>26</sup> also found that double-row repairs were more resistant to gap formation than single-row repairs were. More recently, it was shown in one model that the number of suture passes through the tendon was the most important determinant for gap formation and load to failure regardless of whether a single-row or double-row technique was used<sup>27,28</sup>. Therefore, the reported differences in gap formation between single-row and double-row repair may be attributed to the increased number of suture passes required to complete a double-row repair, thus resulting in decreased gap formation with this repair type.

#### **Single-Row Versus Double-Row Repair: Clinical and Structural Outcomes**

In response to the volume of biomechanical evidence favoring double-row repair, several Level-I and Level-II

studies have compared clinical and structural outcomes after single-row and double-row rotator cuff repair (Table II)<sup>29-38</sup>. Most of these studies have been unable to detect any significant differences between either technique. Of importance, however, many of these studies were either underpowered or were conducted without a power calculation, placing them at risk for type-II error where differences between single-row and double-row groups may have been reported as insignificant when, in fact, they were significant. A systematic review and meta-analysis of the seven Level-I randomized trials comparing single-row versus double-row repair was recently conducted at our institution<sup>39</sup>. Using the relative risk ratio found in this meta-analysis, a sample size of 340 shoulders (170 shoulders per group) would be required for a future randomized trial to achieve 80% power to compare retear rates between single-row and double-row treatment groups. No Level-I study comes close to these numbers, suggesting that these studies may be underpowered.

Our recent meta-analysis<sup>39</sup> did not reveal any significant differences in outcomes scores between single-row and double-row repair. However, we did find a significant increase in the relative risk of imaging-proven retears in the single-row group as compared with the double-row group (relative risk, 1.76 [95% confidence interval (CI), 1.25 to 2.48];  $p = 0.001$ ). The majority of this difference was attributed to the higher rate of partial-thickness retears after single-row repairs (relative risk, 1.99 [95% CI, 1.04 to 3.82];  $p = 0.039$ ). Because this increased rate of retears in the single-row group did not correlate with a difference in outcomes scores, it was concluded that these retears must have been asymptomatic at the time of the individual studies or undetectable by the utilized outcomes scoring systems (American Shoulder and Elbow Surgeons [ASES] scores<sup>40</sup>, University of California-Los Angeles [UCLA] scores<sup>41</sup>, and Constant-Murley [Constant] scores<sup>42</sup>) after a mean 23.2-month follow-up period. Because single-row

**TABLE II Summary of Level-I and Level-II Studies Comparing Single-Row and Double-Row Rotator Cuff Repair Techniques**

Characteristics and Relevant Findings of Level-I and Level-II Studies Comparing Single-Row and Double-Row Rotator Cuff Repair*						
Study	Number of Shoulders	Level of Evidence	Tear Length (sagittal plane)	Follow-Up (months)	Assessed Outcomes	Relevant Findings
Gartsman et al. <sup>29</sup> (2013)	83 (40 SR, 43, DR)	I	SR: <2.5 cm DR: <2.5 cm	SR: NR DR: NR Mean: 10 (range, 6-12)	Subjective: NR Objective: NR Imaging: ultrasound	SR had increased retear rate (25%) compared with DR (7%) (p = 0.024)
Carbonel et al. <sup>30</sup> (2012)	160 (80 SR, 80 DR)	I	SR: 1-3 cm in 51 SR: 3-5 cm in 29 DR: 13 cm in 53 DR: 3-5 cm in 27	SR: 24 DR: 24 MRI SR: 24 MRI DR: 24	Subjective: ASES, UCLA, Constant Objective: SSI, range of motion Imaging: MRI	DR had better outcomes scores (except Constant score) in tears 3-5 cm DR had improved range of motion and SSI in tears 1-3 cm
Lapner et al. <sup>31</sup> (2012)	80 (40 SR, 40 DR)	I	SR: 1.89 cm DR: 2.38 cm	SR: 24 DR: 24 MRI SR: 24 MRI DR: 24	Subjective: ASES, WORC, Constant Objective: strength (in kg) Imaging: MRI and/or ultrasound	SR had higher retear rate Smaller initial tear sizes had better "healing rate" Those with retears had larger initial tear size Those with retears had decreased strength at final follow-up
Koh et al. <sup>32</sup> (2011)	71 (37 SR, 34 DR)	I	SR: 1.72 cm DR: 1.75 cm	SR: 31.0 DR: 32.8 MRI SR: 27.4 MRI DR: 27.6	Subjective: ASES, UCLA, VAS Objective: range of motion Imaging: MRI	DR had improved internal rotation SR had higher retear rate No differences in outcomes scores
Burks et al. <sup>33</sup> (2009)	40 (20 SR, 20 DR)	I	SR: 1-3 cm in 18 SR >3 cm in 2 DR 1-3 cm in 15 SR >3 cm in 5	SR: 12 DR: 12 MRI SR: 12 MRI DR: 12	Subjective: ASES, UCLA, Constant, SANE, WORC Objective: range of motion, strength (in Nm) Imaging: MRI	No differences in clinical or radiographic outcomes
Grasso et al. <sup>34</sup> (2009)	80 (40 SR, 40 DR)	I	SR: 1.56 cm DR: 1.61 cm	SR: N/R DR: N/R Mean 24.8	Subjective: DASH, Constant Objective: Strength (in lbs) Imaging: NR	No differences in outcomes scores
Franceschi et al. <sup>35</sup> (2007)	60 (30 SR, 30 DR)	I	SR: 3-5 cm in 18 SR: >5 cm in 8 DR: 3-5 cm in 21 DR: >5 cm in 5	Mean: 22.5	Subjective: UCLA Objective: range of motion Imaging: magnetic resonance arthrogram	No differences in clinical or radiographic outcomes
Ma et al. <sup>36</sup> (2012)	53 (27 SR, 26 DR)	II	SR: <3 cm in 19 SR: >3 cm in 8 DR: <3 cm in 17 DR: >3 cm in 9	SR: 33.3 DR: 33.5	Subjective: ASES, UCLA Objective: strength (in kg) Imaging: magnetic resonance arthrogram	DR had improved strength in tears >3 cm No difference in outcomes scores No difference in retear rates
Charoussat et al. <sup>37</sup> (2007)	66 (35 SR, 31 DR)	II	N/R	SR: 27.6 DR: 28.7	Subjective: Constant, Satisfaction Objective: NR Imaging: computed tomography arthrogram at 6 months	SR had increased retear rate No differences in outcomes scores
Park et al. <sup>38</sup> (2008)	78 (40 SR, 38 DR)	II	SR: <3 cm in 25 SR: >3cm in 15 DR: <3 cm in 21 DR: >3 cm in 17	Mean: 25.1	Subjective: ASES, Constant Objective: SSI Imaging: NR	DR had improved ASES, Constant, and SSI in tears >3 cm No differences in outcomes scores when all tears considered

\* SR = single-row; DR = double-row; NR = not reported; MRI = magnetic resonance imaging; ASES = American Shoulder and Elbow Surgeons score; UCLA = University of California-Los Angeles score; Constant = Constant-Murley score; SSI = shoulder strength index; VAS = visual analog scale; SANE = Single Assessment Numeric Evaluation; WORC = Western Ontario Rotator Cuff score; and DASH = Disabilities of the Arm, Shoulder and Hand score.

repairs typically do not cover the entire greater tuberosity footprint, it is possible that these "retears" may simply represent an alteration in anatomy of the

posterosuperior cuff tendons. In addition, suture anchors at the tendon-bone interface may interfere with the distinction between partial-thickness tears and

surgical artifacts on postoperative imaging, especially since single-row repairs have been shown biomechanically to increase tendon-bone gapping.

Another potential hypothesis is that a two-year follow-up may not be sufficient to capture those in whom asymptomatic retears have not yet progressed to symptomatic retears. Mall et al.<sup>43</sup> followed 195 patients with asymptomatic rotator cuff tears and found that only 23% (forty-four of 195) became symptomatic two years after study enrollment. Yamaguchi et al.<sup>44</sup> followed forty-five patients with asymptomatic rotator cuff tears via ultrasound and found that the majority of patients (twenty-three of forty-five; 51%) became symptomatic a mean of 2.8 years after study enrollment. These results suggest that patients with imaging-proven asymptomatic retears may require more than two years to develop clinical symptoms. As most studies only report outcomes scores as much as two years postoperatively, patients with imaging-proven retears may develop clinical symptoms and worsening outcomes scores if longer-term follow-up is implemented. However, it must be noted that the source of symptomatology may be different in those who have been treated nonoperatively compared with those who have been treated operatively.

A Level-IV retrospective study by Denard et al.<sup>45</sup> compared the clinical outcomes after single-row versus double-row repair in a series of 107 shoulders (sixty-two in the single-row group and forty-five in the double-row group) with a minimum five-year follow-up. In their study, double-row repair was 4.9 times more likely to result in a good or excellent outcome after repair of large to massive rotator cuff tears ( $p = 0.021$ ). This is the only longer-term study comparing outcomes after single-row and double-row repair and suggests that two-year follow-up may not be adequate to detect clinical differences between single-row and double-row repair, especially since many Level-I and Level-II studies have failed to demonstrate differences in clinical outcomes between single-row and double-row repair techniques after a minimum two-year follow-up.

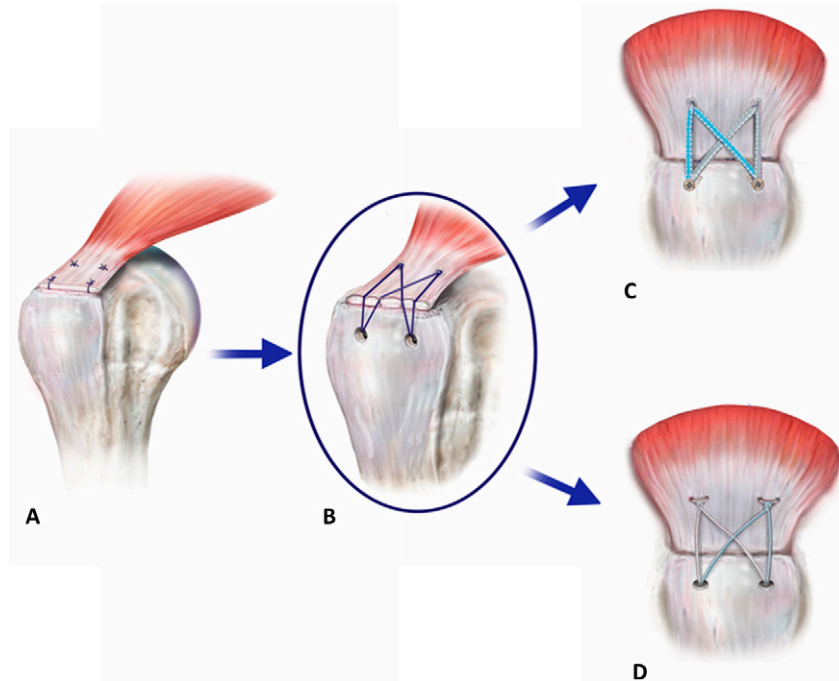
Although clinical and structural outcomes may prove to be clinically relevant with time, initial tear size also appears to be an important factor related to clinical outcomes. In a Level-II trial, Park et al.<sup>38</sup> compared the clinical outcomes after single-row versus double-row repair in a series of seventy-eight consecutive patients with full-thickness rotator cuff tears. While there were no differences in outcomes scores when all tear sizes were considered, stratification of two-year outcomes by tear size revealed significant improvements in ASES scores, Constant scores, and shoulder strength in tears larger than 3 cm<sup>2</sup> after double-row repair compared with the single-row method. Ma et al.<sup>36</sup> randomized fifty-three patients to receive either single-row or double-row repair in another Level-II trial. They found that abduction and external rotation strength was significantly improved after double-row repair as compared with single-row repair if the initial tear size was >3 cm in sagittal length. A Level-I clinical trial by Lapner et al.<sup>31</sup> found decreased retear rates after double-row repair compared with the single-row method in patients with smaller initial tear sizes. In addition, a Level-I trial by Carbonel et al.<sup>30</sup> compared the clinical outcomes after single-row versus double-row repair and stratified their results by initial tear sizes. They found improved abduction capacity after double-row repair across all tear sizes. In larger tears between 3 and 5 cm in sagittal length, the double-row method also showed significant improvements in ASES ( $p = 0.032$ ) and UCLA ( $p = 0.019$ ) scores when compared with the scores of those who underwent single-row repair. Thus, it appears that stratification of both clinical and structural outcomes by initial tear sizes may be another vehicle for detecting clinical differences between single-row and double-row rotator cuff repair.

### Current Techniques

At present, quantifying the clinical and radiographic differences between

traditional single-row and traditional double-row repair constructs may have limited applicability for contemporary surgeons. Over the past decade, many surgeons and researchers have begun experimenting with newer linked double-row suture and anchor configurations that have been reported to improve tendon-footprint compression as compared with that achieved with standard double-row repairs<sup>18,19,46,47</sup>. In these newer configurations, the medial suture limbs are preserved and are passed over the tendon substance and its footprint onto a distal-lateral row of anchors. This linked construct, first described in 2004<sup>48</sup>, has evolved into a *transosseous equivalent* technique (Fig. 3, B), which has become quite popular in recent years due to its favorable biomechanical properties, including tendon-footprint compression, ultimate load to failure, and gap formation, in addition to its surgical reproducibility<sup>18,19,48-51</sup>. Burkhart et al.<sup>46</sup> also demonstrated the self-reinforcing properties of these constructs and found that grasping strength improved as the mechanical load was increased. In addition to these advantages, this configuration allows anchors to be placed in the best-quality bone of the greater tuberosity<sup>52,53</sup> while also moving the sutures and anchors away from the tendon-bone interface where healing occurs.

More recently, surgeons and researchers have developed knotless double-row techniques that theoretically decrease the operative time associated with arthroscopic knot-tying, thereby improving the cost-effectiveness of double-row repair (Fig. 3, C and D). Compared with techniques that utilize medial knots, knotless constructs are also purported to improve blood flow to the healing tendon<sup>54,55</sup>. In addition, these knotless configurations use a newer, wider suture material that is thought to prevent suture pull-through by dissipating the applied forces over a larger tendon surface area<sup>56</sup>. Mall et al.<sup>57</sup> conducted a systematic review comparing the reported biomechanical

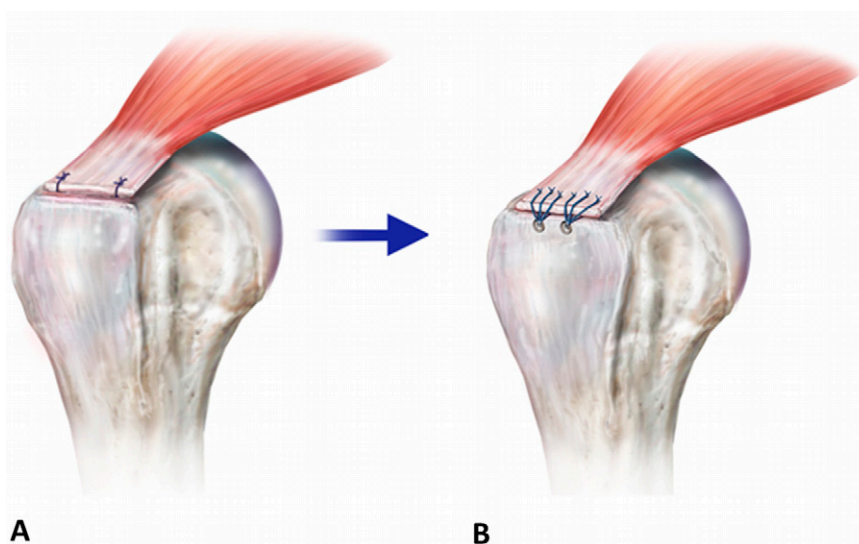


**Fig. 3**  
 Traditional double-row suture configuration utilizes two lateral anchors tied in a simple stitch pattern along with two medial anchors tied in horizontal mattress sutures (**Fig. 3, A**). The transosseous-equivalent technique brings the medial suture limbs over the tendon substance and inserts them into the lateral anchors (**Fig. 3, B**). Variations in the width of suture material and use of medial knots have been described (**Fig. 3, C and D**). Compared with the transosseous-equivalent technique with medial knots (**Fig. 3, D**), knotless transosseous-equivalent techniques with wider suture material (**Fig. 3, C**) may dissipate forces over a larger tendon area while also decreasing operative time.

properties of knotted versus knotless transosseous-equivalent techniques. They found that knotless techniques resulted in increased gap formation

and a decreased load to failure compared with transosseous-equivalent techniques in which medial knots were tied. On a few occasions, failure of the

knotless construct has been reported to be associated with suture slippage<sup>58,59</sup>. These biomechanical results have also been correlated to clinical



**Fig. 4**  
 As a modification to the traditional single-row construct (**Fig. 4, A**), triple-loaded suture anchors have been developed to increase the number of suture passes required to secure the tendon back to its footprint (**Fig. 4, B**).

TABLE III Clinical Care Recommendations

Tear Size	Recommendation	Grade of Recommendation*
<3 cm	Double-row transosseous-equivalent repair	B
3 to 5 cm	Double-row transosseous-equivalent repair	A
Massive (>5 cm)	Double-row or single-row repair	I

\*A: Good evidence (Level-I studies with consistent findings) for or against recommending intervention. B: Fair evidence (Level-II or III studies with consistent findings) for or against recommending intervention. C: Conflicting or poor-quality evidence (Level-IV or V studies) not allowing a recommendation for or against intervention. I: There is insufficient evidence to make a recommendation.

outcomes. Vaishnav and Millett<sup>60</sup> demonstrated excellent results in a series of seventeen patients treated with a knotless transosseous-equivalent technique. However, studies by Boyer et al.<sup>61</sup> and Rhee et al.<sup>62</sup> both found higher magnetic resonance imaging (MRI)-proven retear rates in their knotless groups compared with their knotted groups. Despite the increase in retears in the knotless groups, there were no differences in clinical outcomes between either cohort in either study.

Single-row repairs have also evolved extensively over the past decade. The development of double-loaded and triple-loaded anchors has facilitated the ability to place more sutures through the tendon per anchor, thus improving biomechanical properties (Fig. 4)<sup>63</sup>. Many authors have described modified suture configurations in which a horizontal mattress suture is placed in the rotator cuff tendon with one or more simple sutures passed medially, thereby creating a rip-stop configuration, similar to a Mason-Allen stitch.

Biomechanically, it appears that the double-row suture-bridge construct is stronger than both first-generation single-row and double-row repairs. Park et al.<sup>18</sup> used a pressure monitor to measure pressures over the supraspinatus footprint with three repair techniques. A 30-N force was applied to the repaired tendon, and the humerus was placed in various angles of abduction and rotation. The double-row transosseous-equivalent repair had significantly increased pressure at all angles of abduction and rotation in comparison with the pressure exerted in standard

double-row and single-row repairs. Only a few biomechanical studies have made the comparison between transosseous-equivalent constructs and single-row repairs with modified suture configurations; however, these studies showed mixed results<sup>28,63-65</sup>. At present, there are no clinical outcomes studies comparing these newer single-row and double-row techniques. However, a Level-I trial by Gartsman et al.<sup>29</sup> demonstrated a significantly increased rate of imaging-proven retears via ultrasound after single-row repair compared with transosseous-equivalent double-row repair ( $p = 0.024$ ).

### Clinical Care Recommendations

Overwhelming, biomechanical evidence suggests that double-row repair is structurally superior to single-row repair; however, this difference has not translated into an improvement in clinical outcomes scores thus far.

Despite the lack of evidence regarding the clinical superiority of double-row repairs, surgeons have already begun to perform modified double-row techniques such as transosseous-equivalent repairs with or without medial knots. The rationale behind this movement involves the improved tendon-footprint compression and operative efficiency that is achieved with these newer constructs as compared with those achieved with the standard double-row suture-anchor repair method.

Due to the numerous biomechanical advantages of the transosseous-equivalent techniques, the authors choose to perform double-row

transosseous-equivalent repair (with or without medial knots) whenever possible, especially in medium to large-size tears (Table III). In smaller full-thickness tears, this type of repair may not be necessary to achieve adequate footprint coverage and compression. However, it appears that even in smaller tears, imaging-proven retears may be higher after single-row repair<sup>29-31</sup>. Therefore, we prefer to perform double-row transosseous-equivalent repair even in tears <3 cm in sagittal length. In massive, contracted tears, tendon mobility and quality may be inadequate to safely perform a double-row transosseous-equivalent repair, and thus single-row repair may be necessary in these cases. Due to very low numbers reported in the literature, strong clinical evidence does not yet exist to guide decisions regarding single-row versus double-row repairs in massive rotator cuff tears.

### Conclusion

The vast majority of biomechanical evidence favors double-row repair with respect to footprint contact area, footprint compression, ultimate load to failure, and gap formation. In addition, numerous studies have documented a lower rate of imaging-proven rotator cuff retears when traditional double-row repair is compared with traditional single-row repair types. However, in most clinical outcome studies to date, double-row repair has not yet resulted in an improvement in clinical outcomes. Longer-term studies that are appropriately powered to show a difference between groups are required



before definitive conclusions can be made. Recently, modified double-row repairs, including various transosseous-equivalent configurations, have been adopted due to the volume of biomechanical evidence showing their improved tendon-footprint compression. Therefore, we prefer to perform double-row transosseous-equivalent repairs (with or without medial knots) whenever possible, especially in medium to large-size posterosuperior cuff tears.

### Source of Funding

There was no external funding source for this study.

Kevin M. Roth, MD<sup>1</sup>,  
Ryan J. Warth, MD<sup>2</sup>,  
Jared T. Lee, MD<sup>2</sup>,  
Peter J. Millett, MD, MSc<sup>2</sup>,  
Neal S. ElAttrache, MD<sup>3</sup>

<sup>1</sup>Webster Orthopedic Medical Group,  
3010 Colby Street, Suite 118,  
Berkeley, CA 94705

<sup>2</sup>The Steadman Philippon Research  
Institute, 181 West Meadow Drive,  
Suite 1000, Vail, CO 81657

<sup>3</sup>The Kerlan-Jobe Orthopaedic Clinic,  
6801 Park Terrace, Los Angeles,  
CA 90045

E-mail address for N.S. ElAttrache:  
elattrache@aol.com

### References

- Thomopoulos S, Williams GR, Gimbel JA, Favata M, Soslowky LJ. Variation of biomechanical, structural, and compositional properties along the tendon to bone insertion site. *J Orthop Res*. 2003 May;21(3):413-9.
- Davidson J, Burkhart SS. The geometric classification of rotator cuff tears: a system linking tear pattern to treatment and prognosis. *Arthroscopy*. 2010 Mar;26(3):417-24. Epub 2009 Dec 29.
- Minagawa H, Itoi E, Konno N, Kido T, Sano A, Urayama M, Sato K. Humeral attachment of the supraspinatus and infraspinatus tendons: an anatomic study. *Arthroscopy*. 1998 Apr;14(3):302-6.
- Roh MS, Wang VM, April EW, Pollock RG, Bigliani LU, Flatow EL. Anterior and posterior musculotendinous anatomy of the supraspinatus. *J Shoulder Elbow Surg*. 2000 Sep-Oct;9(5):436-40.
- Volk AG, Vangsness CT Jr. An anatomic study of the supraspinatus muscle and tendon. *Clin Orthop Relat Res*. 2001 Mar;(384):280-5.
- Dugas JR, Campbell DA, Warren RF, Robie BH, Millett PJ. Anatomy and dimensions of rotator cuff insertions. *J Shoulder Elbow Surg*. 2002 Sep-Oct;11(5):498-503.
- Ruotolo C, Fow JE, Nottage WM. The supraspinatus footprint: an anatomic study of the supraspinatus insertion. *Arthroscopy*. 2004 Mar;20(3):246-9.
- Curtis AS, Burbank KM, Tierney JJ, Scheller AD, Curran AR. The insertional footprint of the rotator cuff: an anatomic study. *Arthroscopy*. 2006 Jun;22(6):e1.
- Mochizuki T, Sugaya H, Uomizu M, Maeda K, Matsuki K, Sekiya I, Muneta T, Akita K. Humeral insertion of the supraspinatus and infraspinatus. New anatomical findings regarding the footprint of the rotator cuff. *J Bone Joint Surg Am*. 2008 May;90(5):962-9.
- Harryman DT 2nd, Mack LA, Wang KY, Jackins SE, Richardson ML, Matsen FA 3rd. Repairs of the rotator cuff. Correlation of functional results with integrity of the cuff. *J Bone Joint Surg Am*. 1991 Aug;73(7):982-9.
- Rodeo SA, Arnoczky SP, Torzilli PA, Hidaka C, Warren RF. Tendon-healing in a bone tunnel. A biomechanical and histological study in the dog. *J Bone Joint Surg Am*. 1993 Dec;75(12):1795-803.
- Oguma H, Murakami G, Takahashi-Iwanaga H, Aoki M, Ishii S. Early anchoring collagen fibers at the bone-tendon interface are conducted by woven bone formation: light microscope and scanning electron microscope observation using a canine model. *J Orthop Res*. 2001 Sep;19(5):873-80.
- Apreleva M, Ozbaydar M, Fitzgibbons PG, Warner JJ. Rotator cuff tears: the effect of the reconstruction method on three-dimensional repair site area. *Arthroscopy*. 2002 May-Jun;18(5):519-26.
- Tuoheti Y, Itoi E, Yamamoto N, Seki N, Abe H, Minagawa H, Okada K, Shimada Y. Contact area, contact pressure, and pressure patterns of the tendon-bone interface after rotator cuff repair. *Am J Sports Med*. 2005 Dec;33(12):1869-74. Epub 2005 Sep 12.
- Meier SW, Meier JD. The effect of double-row fixation on initial repair strength in rotator cuff repair: a biomechanical study. *Arthroscopy*. 2006 Nov;22(11):1168-73.
- Mazzocca AD, Millett PJ, Guanche CA, Santangelo SA, Arciero RA. Arthroscopic single-row versus double-row suture anchor rotator cuff repair. *Am J Sports Med*. 2005 Dec;33(12):1861-8. Epub 2005 Oct 6.
- Weiler A, Hoffmann RF, Bail HJ, Rehm O, Südkamp NP. Tendon healing in a bone tunnel. Part II: Histologic analysis after biodegradable interference fit fixation in a model of anterior cruciate ligament reconstruction in sheep. *Arthroscopy*. 2002 Feb;18(2):124-35.
- Park MC, Cadet ER, Levine WN, Bigliani LU, Ahmad CS. Tendon-to-bone pressure distributions at a repaired rotator cuff footprint using transosseous suture and suture anchor fixation techniques. *Am J Sports Med*. 2005 Aug;33(8):1154-9. Epub 2005 Jul 6.
- Park MC, ElAttrache NS, Tibone JE, Ahmad CS, Jun BJ, Lee TQ. Part I: Footprint contact characteristics for a transosseous-equivalent rotator cuff repair technique compared with a double-row repair technique. *J Shoulder Elbow Surg*. 2007 Jul-Aug;16(4):461-8. Epub 2007 Feb 22.
- Hughes RE, An KN. Force analysis of rotator cuff muscles. *Clin Orthop Relat Res*. 1996 Sep;(330):75-83.
- Waltrip RL, Zheng N, Dugas JR, Andrews JR. Rotator cuff repair. A biomechanical comparison of three techniques. *Am J Sports Med*. 2003 Jul-Aug;31(4):493-7.
- Gerber C, Schneeberger AG, Beck M, Schlegel U. Mechanical strength of repairs of the rotator cuff. *J Bone Joint Surg Br*. 1994 May;76(3):371-80.
- Smith CD, Alexander S, Hill AM, Huijsmans PE, Bull AMJ, Amis AA, De Beer JF, Wallace AL. A biomechanical comparison of single and double-row fixation in arthroscopic rotator cuff repair. *J Bone Joint Surg Am*. 2006 Nov;88(11):2425-31.
- Kim DH, Elattrache NS, Tibone JE, Jun BJ, DeLaMora SN, Kvitne RS, Lee TQ. Biomechanical comparison of a single-row versus double-row suture anchor technique for rotator cuff repair. *Am J Sports Med*. 2006 Mar;34(3):407-14. Epub 2005 Nov 10.
- Ahmad CS, Vorys GC, Covey A, Levine WN, Gardner TR, Bigliani LU. Rotator cuff repair fluid extravasation characteristics are influenced by repair technique. *J Shoulder Elbow Surg*. 2009 Nov-Dec;18(6):976-81. Epub 2009 Mar 17.
- Milano G, Grasso A, Zarelli D, Deriu L, Cillo M, Fabbriani C. Comparison between single-row and double-row rotator cuff repair: a biomechanical study. *Knee Surg Sports Traumatol Arthrosc*. 2008 Jan;16(1):75-80. Epub 2007 Aug 8.
- Jost PW, Khair MM, Chen DX, Wright TM, Kelly AM, Rodeo SA. Suture number determines strength of rotator cuff repair. *J Bone Joint Surg Am*. 2012 Jul 18;94(14):e100.
- Lorbach O, Kieb M, Raber F, Busch LC, Kohn D, Pape D. Comparable biomechanical results for a modified single-row rotator cuff reconstruction using triple-loaded suture anchors versus a suture-bridging double-row repair. *Arthroscopy*. 2012 Feb;28(2):178-87. Epub 2011 Nov 23.
- Gartsman GM, Drake G, Edwards TB, Elkousy HA, Hammerman SM, O'Connor DP, Press CM. Ultrasound evaluation of arthroscopic full-thickness supraspinatus rotator cuff repair: single-row versus double-row suture bridge (transosseous equivalent) fixation. Results of a prospective, randomized study. *J Shoulder Elbow Surg*. 2013 Nov;22(11):1480-7. Epub 2013 Sep 4.
- Carbonel I, Martinez AA, Calvo A, Ripalda J, Herrera A. Single-row versus double-row arthroscopic repair in the treatment of rotator cuff tears: a prospective randomized clinical study. *Int Orthop*. 2012 Sep;36(9):1877-83. Epub 2012 May 16.
- Lapner PLC, Sabri E, Rakhra K, McRae S, Leiter J, Bell K, Macdonald P. A multicenter randomized controlled trial comparing single-row with double-row fixation in arthroscopic rotator cuff repair. *J Bone Joint Surg Am*. 2012 Jul 18;94(14):1249-57.
- Koh KH, Kang KC, Lim TK, Shon MS, Yoo JC. Prospective randomized clinical trial of single-versus double-row suture anchor repair in 2- to 4-cm rotator cuff tears: clinical and magnetic resonance imaging results. *Arthroscopy*. 2011 Apr;27(4):453-62.
- Burks RT, Crim J, Brown N, Fink B, Greis PE. A prospective randomized clinical trial comparing arthroscopic single- and double-row rotator cuff repair: magnetic resonance

- imaging and early clinical evaluation. *Am J Sports Med.* 2009 Apr;37(4):674-82. Epub 2009 Feb 9.
- 34.** Grasso A, Milano G, Salvatore M, Falcone G, Deriu L, Fabbriani C. Single-row versus double-row arthroscopic rotator cuff repair: a prospective randomized clinical study. *Arthroscopy.* 2009 Jan;25(1):4-12. Epub 2008 Nov 1.
- 35.** Franceschi F, Ruzzini L, Longo UG, Martina FM, Zobel BB, Maffulli N, Denaro V. Equivalent clinical results of arthroscopic single-row and double-row suture anchor repair for rotator cuff tears: a randomized controlled trial. *Am J Sports Med.* 2007 Aug;35(8):1254-60. Epub 2007 Jun 6.
- 36.** Ma HL, Chiang ER, Wu HTH, Hung SC, Wang ST, Liu CL, Chen TH. Clinical outcome and imaging of arthroscopic single-row and double-row rotator cuff repair: a prospective randomized trial. *Arthroscopy.* 2012 Jan;28(1):16-24. Epub 2011 Oct 7.
- 37.** Charousset C, Grimberg J, Duranthon LD, Bellaiche L, Petrover D. Can a double-row anchorage technique improve tendon healing in arthroscopic rotator cuff repair?: A prospective, nonrandomized, comparative study of double-row and single-row anchorage techniques with computed tomographic arthrography tendon healing assessment. *Am J Sports Med.* 2007 Aug;35(8):1247-53. Epub 2007 Apr 23.
- 38.** Park JY, Lhee SH, Choi JH, Park HK, Yu JW, Seo JB. Comparison of the clinical outcomes of single- and double-row repairs in rotator cuff tears. *Am J Sports Med.* 2008 Jul;36(7):1310-6. Epub 2008 Apr 15.
- 39.** Millett PJ, Warth RJ, Dornan GJ, Lee JT, Spiegl UJ. Clinical and structural outcomes after arthroscopic single-row versus double-row rotator cuff repair: a systematic review and meta-analysis of level I randomized clinical trials. *J Shoulder Elbow Surg.* 2014 April;23(4):586-97. Epub 2014 Jan 8.
- 40.** Richards RR, An KN, Bigliani LU, Friedman RJ, Gartsman GM, Gristina AG, Iannotti JP, Mow VC, Sidles JA, Zuckerman JD. A standardized method for the assessment of shoulder function. *J Shoulder Elbow Surg.* 1994 Nov;3(6):347-52. Epub 2009 Feb 13.
- 41.** Amstutz HC, Sew Hoy AL, Clarke IC. UCLA anatomic total shoulder arthroplasty. *Clin Orthop Relat Res.* 1981 Mar-Apr;(155):7-20.
- 42.** Constant CR, Murley AHG. A clinical method of functional assessment of the shoulder. *Clin Orthop Relat Res.* 1987 Jan;(214):160-4.
- 43.** Mall NA, Kim HM, Keener JD, Steger-May K, Teefey SA, Middleton WD, Stobbs G, Yamaguchi K. Symptomatic progression of asymptomatic rotator cuff tears: a prospective study of clinical and sonographic variables. *J Bone Joint Surg Am.* 2010 Nov 17;92(16):2623-33.
- 44.** Yamaguchi K, Tetro AM, Blam O, Evanoff BA, Teefey SA, Middleton WD. Natural history of asymptomatic rotator cuff tears: a longitudinal analysis of asymptomatic tears detected sonographically. *J Shoulder Elbow Surg.* 2001 May-Jun;10(3):199-203.
- 45.** Denard PJ, Jiwani AZ, Lädermann A, Burkhart SS. Long-term outcome of arthroscopic massive rotator cuff repair: the importance of double-row fixation. *Arthroscopy.* 2012 Jul;28(7):909-15. Epub 2012 Feb 24.
- 46.** Burkhart SS, Adams CR, Burkhart SS, Schoolfield JD. A biomechanical comparison of 2 techniques of footprint reconstruction for rotator cuff repair: the SwiveLock-FiberChain construct versus standard double-row repair. *Arthroscopy.* 2009 Mar;25(3):274-81. Epub 2008 Dec 18.
- 47.** Burkhart SS, Denard PJ, Obopilwe E, Mazzocca AD. Optimizing pressurized contact area in rotator cuff repair: the diamondback repair. *Arthroscopy.* 2012 Feb;28(2):188-95. Epub 2011 Oct 27.
- 48.** Millett PJ, Mazzocca A, Guanche CA. Mattress double anchor footprint repair: a novel, arthroscopic rotator cuff repair technique. *Arthroscopy.* 2004 Oct;20(8):875-9.
- 49.** Pauly S, Kieser B, Schill A, Gerhardt C, Scheibel M. Biomechanical comparison of 4 double-row suture-bridging rotator cuff repair techniques using different medial-row configurations. *Arthroscopy.* 2010 Oct;26(10):1281-8. Epub 2010 Jun 11.
- 50.** Kaplan K, ElAttrache NS, Vazquez O, Chen YJ, Lee T. Knotless rotator cuff repair in an external rotation model: the importance of medial-row horizontal mattress sutures. *Arthroscopy.* 2011 Apr;27(4):471-8.
- 51.** Quigley RJ, Gupta A, Oh JH, Chung KC, McGarry MH, Gupta R, Tibone JE, Lee TQ. Biomechanical comparison of single-row, double-row, and transosseous-equivalent repair techniques after healing in an animal rotator cuff tear model. *J Orthop Res.* 2013 Aug;31(8):1254-60. Epub 2013 Apr 9.
- 52.** Tingart MJ, Bouxsein ML, Zurakowski D, Warner JP, Apreleva M. Three-dimensional distribution of bone density in the proximal humerus. *Calcif Tissue Int.* 2003 Dec;73(6):531-6.
- 53.** Tingart MJ, Apreleva M, Zurakowski D, Warner JJ. Pullout strength of suture anchors used in rotator cuff repair. *J Bone Joint Surg Am.* 2003 Nov;85(11):2190-8.
- 54.** Voigt C, Bosse C, Vossenhenrich R, Schulz AP, Lill H. Arthroscopic supraspinatus tendon repair with suture-bridging technique: functional outcome and magnetic resonance imaging. *Am J Sports Med.* 2010 May;38(5):983-91.
- 55.** Cho NS, Lee BG, Rhee YG. Arthroscopic rotator cuff repair using a suture bridge technique: is the repair integrity actually maintained? *Am J Sports Med.* 2011 Oct;39(10):2108-16. Epub 2011 Feb 24.
- 56.** Barber FA, Drew OR. A biomechanical comparison of tendon-bone interface motion and cyclic loading between single-row, triple-loaded cuff repairs and double-row, suture-tape cuff repairs using biocomposite anchors. *Arthroscopy.* 2012 Sep;28(9):1197-205. Epub 2012 May 15.
- 57.** Mall NA, Lee AS, Chahal J, Van Thiel GS, Romeo AA, Verma NN, Cole BJ. Transosseous-equivalent rotator cuff repair: a systematic review on the biomechanical importance of tying the medial row. *Arthroscopy.* 2013 Feb;29(2):377-86.
- 58.** Wieser K, Farshad M, Vlachopoulos L, Ruffieux K, Gerber C, Meyer DC. Suture slippage in knotless suture anchors as a potential failure mechanism in rotator cuff repair. *Arthroscopy.* 2012 Nov;28(11):1622-7. Epub 2012 Sep 13.
- 59.** Kummer F, Hergan DJ, Thut DC, Pahk B, Jazrawi LM. Suture loosening and its effect on tendon fixation in knotless double-row rotator cuff repairs. *Arthroscopy.* 2011 Nov;27(11):1478-84. Epub 2011 Sep 15.
- 60.** Vaishnav S, Millett PJ. Arthroscopic rotator cuff repair: scientific rationale, surgical technique, and early clinical and functional results of a knotless self-reinforcing double-row rotator cuff repair system. *J Shoulder Elbow Surg.* 2010 Mar;19(2)(Suppl):83-90.
- 61.** Boyer P, Bouthors C, Delcourt T, Stewart O, Hamida F, Mylle G, Massin P. Arthroscopic double-row cuff repair with suture-bridging: a structural and functional comparison of two techniques. *Knee Surg Sports Traumatol Arthrosc.* 2013 Feb 13 [Epub ahead of print].
- 62.** Rhee YG, Cho NS, Parke CS. Arthroscopic rotator cuff repair using modified Mason-Allen medial row stitch: knotless versus knot-tying suture bridge technique. *Am J Sports Med.* 2012 Nov;40(11):2440-7. Epub 2012 Sep 21.
- 63.** Jost PW, Khair MM, Chen DX, Wright TM, Kelly AM, Rodeo SA. Suture number determines strength of rotator cuff repair. *J Bone Joint Surg Am.* 2012 Jul 18;94(14):e100.
- 64.** Barber FA, Hapa O, Bynum JA. Comparative testing by cyclic loading of rotator cuff suture anchors containing multiple high-strength sutures. *Arthroscopy.* 2010 Sep;26(9)(Suppl):S134-41. Epub 2010 May 14.
- 65.** Park MC, Ahmad CS, Elattrache NS, Lee TQ. Regarding biomechanical advantages of triple-loaded suture anchors. *Arthroscopy.* 2010 Jul;26(7):873-4; author reply 874-6.