

Concomitant glenohumeral pathologies associated with acute and chronic grade III and grade V acromioclavicular joint injuries

Gunnar Jensen¹ · Peter J. Millett^{2,3} · Dimitri S. Tahal³ · Mireille Al Ibadi¹ · Helmut Lill¹ · Jan Christoph Katthagen^{1,3,4}

Received: 2 December 2016 / Accepted: 23 March 2017
© SICOT aisbl 2017

Abstract

Purpose The purpose of this study was to identify the risk of concomitant glenohumeral pathologies with acromioclavicular joint injuries grade III and V.

Methods Patients who underwent arthroscopically-assisted stabilization of acromioclavicular joint injuries grade III or grade V between 01/2007 and 12/2015 were identified in the patient databases of two surgical centres. Gender, age at index surgery, grade of acromioclavicular joint injury (Rockwood III or Rockwood V), and duration between injury and index surgery (classified as acute or chronic) were of interest. Concomitant glenohumeral pathologies were noted and their treatment was classified as debridement or reconstructive procedure.

Results A total of 376 patients (336 male, 40 female) were included. Mean age at time of arthroscopic acromioclavicular joint reconstruction surgery was 42.1 ± 14.0 years. Overall, 201 patients (53%) had one or more concomitant glenohumeral pathologies. Lesions of the biceps tendon complex and rotator cuff were the most common. Forty-five patients (12.0%) had concomitant glenohumeral pathologies that required an additional repair. The remaining 156 patients

(41.5%) received a debridement of their concomitant pathologies. Rockwood grade V compared to Rockwood grade III ($p = 0.013$; odds ratio 1.7), and chronic compared to acute injury were significantly associated with having a concomitant glenohumeral pathology ($p = 0.019$; odds ratio 1.7). The probability of having a concomitant glenohumeral pathology was also significantly associated with increasing age ($p < 0.0001$). **Conclusions** Concomitant glenohumeral pathologies were observed in 53% of surgically treated patients with an acute or chronic acromioclavicular joint injury of either grade III or V. Twenty-two percent of these patients with concomitant glenohumeral pathologies received an additional dedicated repair procedure. Although a significant difference in occurrence of concomitant glenohumeral pathologies was seen between Rockwood grades III and V, and between acute and chronic lesions, increasing age was identified as the most dominant predictor.

Level of Evidence: Level IV, case series.

Keywords Acromioclavicular joint injury · Arthroscopy · Shoulder · Concomitant glenohumeral pathology · Biceps tendon · SLAP complex · Rotator cuff

✉ Gunnar Jensen
gunnar.jensen@diakovere.de

¹ Diakovere Friederikenstift, Orthopedics and Traumatology, Humboldtstraße 5, Hannover, Germany

² The Steadman Clinic, 181 West Meadow Drive Suite 400, Vail, CO, USA

³ Steadman Philippon Research Institute, 181 West Meadow Drive Suite 1000, Vail, CO, USA

⁴ Department of Trauma, Hand and Reconstructive Surgery, University Hospital Münster, Albert-Schweitzer Campus 1, Münster, Germany

Introduction

Injuries of the acromioclavicular (AC) joint are among the most common injuries of the shoulder girdle with an estimated incidence of 1.8 per 1000 per year [1]. The male-female ratio is as high as 8.5:1 and more than half of all AC joint injuries occur in individuals between the ages of 20 and 39 years, mainly during sport activities [1, 2]. Accordingly, 30% of all shoulder injuries in the NFL are AC joint injuries, with an incidence of 2.6/1000 athletes per year [3]. AC joint injuries are typically classified according to Rockwood [4]. More recently, the ISAKOS upper

extremity committee introduced a new sub-classification of Rockwood grade III injuries into grade IIIA (horizontally stable) and IIIB (horizontally unstable) [5]. Present controversy concerning the treatment of Rockwood grade III injuries [6–10] may possibly be solved with use of this sub-classification. Evidence in the literature suggests that Rockwood grades I, II, and IIIA injuries can usually be treated non-operatively whereas Rockwood grades IIIB, IV, V, and VI injuries are typically treated with surgical reconstruction [5–16].

Many authors classify the first 21 days after an AC joint injury as the acute injury phase, with symptoms persisting for more than three weeks being classified as chronic [6, 12, 17–20]. If surgical treatment is performed acutely, some surgeons prefer AC joint stabilization without additional graft augmentation and, in such instances, rely on the healing of the original coracoclavicular (CC) and AC ligaments [11, 12, 14, 16]. While the use of an additional allo- or autograft augmentation is done by some for acute injuries [10, 13] graft use is clearly recommended for surgical stabilization performed more than three weeks after the injury (chronic AC joint injuries) [17, 21]. Addressing both the CC and AC ligaments may be important to restore horizontal as well as vertical AC joint stability, independent of the duration between injury and surgical treatment [9, 17, 21, 22].

The prevalence of concomitant glenohumeral pathologies (CGP) associated with surgically treated AC joint injuries has been described to lie somewhere between 15 and 43%, and several authors have emphasized glenohumeral arthroscopy prior to AC joint stabilization [12, 17, 19, 20, 23, 24]. Most studies with evaluation of CGP have focused on acute AC joint injuries, and some evidence suggests that concomitant lesions may be more common in higher grade injuries [19, 20, 24]. Arrigoni et al. found a significantly higher rate of CGP for older versus younger patients with the cutoff age arbitrarily set at 45 years [23]. Furthermore, the authors observed more CGP in patients with chronic injuries (41%) compared to patients with acute injuries (23%) but this difference was not statistically significant. Despite these previous observations, the probability of missing a CGP if AC joint stabilization surgery

is performed without glenohumeral arthroscopy remains unclear for individual patients.

The purpose of this study was to identify the risk of concomitant glenohumeral pathologies with acromioclavicular joint injuries grade III and V. We hypothesized that CGP would be more common in patients with grade V injuries compared to patients with grade III injuries. It was furthermore hypothesized that CGP would be more common in patients with chronic versus acute AC joint injuries, and that the probability of CGP would be associated with increasing age.

Materials and methods

This study consisted of a retrospective review of prospectively collected data from two surgical centres (The Steadman Clinic in Vail, Colorado, U.S.A. [Center 1] and DIAKOVERE Friederikenstift gGmbH in Hanover, Germany [Center 2]). Institutional Review Board approval was obtained before initiation of this study. Patients who underwent arthroscopically-assisted reconstruction of AC joint injuries grade III or grade V between 01/2007 and 12/2015 were identified in the patient databases of a sports medicine fellowship-trained orthopaedic surgeon and of a multi-surgeon traumatology clinic with arthroscopic specialization. The inclusion criteria were arthroscopically-assisted stabilization of AC joint injuries grade III and grade V and arthroscopic glenohumeral joint inspection with documentation of possible intraarticular CGP (Fig. 1). Patients with prior arthroscopic treatment of the affected shoulder after the AC joint injury but before the index AC joint stabilization with documentation of CGP were excluded. Furthermore, patients with a history of significant prior shoulder surgery, i.e., fracture treatment, arthroplasty or tendon transfer were excluded.

The demographic data collected included gender, age at index surgery, grade of AC joint injury (Rockwood III or Rockwood V), and duration between AC joint injury and index surgery. Depending on the duration between injury and surgery, the AC joint injuries were classified as acute (defined as 0–21 days) or

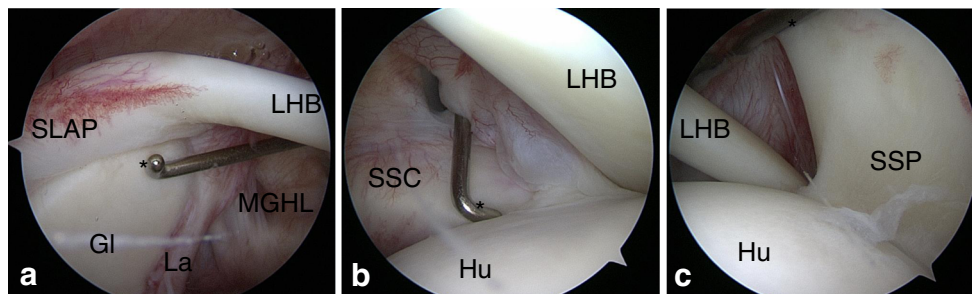


Fig. 1 Standardized glenohumeral inspection of a right shoulder at the beginning of the procedure: standard posterior viewing portal with a 30° scope using a probe (*) through an antero-inferior portal in the rotator interval. **a** 30° scope focussed on 9 o'clock position: evaluation of the SLAP-complex (SLAP) and anterior labrum (La), the medial glenohumeral ligament (MGHL), glenoid surface (Gl), and superior

aspects of the long head of the biceps tendon (LHB). **b** 30° scope focussed on 4:30 o'clock position: evaluation of the surface of the humeral head (Hu) and the medial aspects of the pulley complex with the subscapular tendon (SSC) and LHB. **c** The same orientation of the scope focussed on the lateral aspect of the pulley system with LHB and the supraspinatus tendon (SSP)

chronic (more than 21 days) [11, 12, 17, 19, 20, 25]. The identified CGP that were of interest for this study included chondral lesions of the humeral head or the glenoid, labral lesions (i.e., Bankart lesions, posterior Bankart lesions or labral fraying), SLAP lesions (according to Snyder et al. [26]), intra-articular biceps degeneration or tearing, pulley lesions and/or biceps instability, subscapularis lesions, and posterosuperior rotator cuff lesions (supraspinatus, infraspinatus) including partial- or full-thickness rotator cuff tears. The treatment of these CGP was recorded and was broadly classified as a debridement or reconstructive procedure (e.g., repair of SLAP lesions, rotator cuff repair, or biceps tenodesis, etc.) with type and technique noted. Inflammatory pathologies such as synovitis and tenosynovitis were not counted as CGP.

Statistical methods

Statistical analysis was done using R software [27]. Descriptive analysis was done for all parameters of interest. Fisher's exact test was used to test for an association between CGP and Rockwood grade, gender, and acute or chronic injury. Logistic regression was used to model CGP as a function of age. A nonlinear effect for age was modeled using a restricted cubic spline, and a likelihood ratio test was used to assess the overall statistical significance of the age effect.

Results

Between 01/2007 and 12/2015, a total of 389 patients had an arthroscopically-assisted stabilization of Rockwood grade III

or grade V AC joint injury in both study centers. Twelve patients had received prior arthroscopic treatment at an external facility after the AC joint injury but before the index AC joint stabilization surgery and were therefore excluded from the study. Another patient had an AC joint injury after having received a latissimus dorsi transfer. This patient was excluded due to the distorted glenohumeral joint anatomy. A total of 376 patients (336 male, 40 female) fit the inclusion criteria (29.8%, $n = 112$ from Center 1 and 70.2%, $n = 264$ patients from Center 2). Mean age at time of arthroscopic AC joint stabilization surgery was 42.1 ± 14.0 years (range, 13–76 years). The AC joint injury was classified as Rockwood grade III in 186 patients and as Rockwood grade V in 190 patients. Patients with grade III injury were significantly younger (mean age 39.6 years) than patients with a grade V injury (mean age 44.6 years; $p < 0.001$). The AC joint injury was classified as acute (0–21 days after trauma) in 229 patients (60.9%) and as chronic (>21 days after trauma) in 147 patients (39.1%). For patients with chronic AC joint injuries, the mean duration between the injury and the arthroscopically-assisted treatment was 99.8 ± 175.5 weeks (range, 3–863 weeks). Patients with chronic injuries that received AC joint reconstruction were significantly older (mean age 44.9 years) than patients with acute injuries (mean age 40.3 years; $p = 0.002$).

Concomitant glenohumeral pathologies

Overall, 317 CGP were identified in 376 patients (Table 1), and 45 patients (12.0%) had one or more CGP that required an additional reconstructive procedure (Table 2). Fifty-three

Table 1 Concomitant glenohumeral pathologies [SLAP = superior labrum anteroposterior]

Total concomitant lesions (debrided and reconstructed)	Overall
<i>Patients with at least 1 rotator cuff lesion</i>	86 (22.9%)
Supraspinatus	
-Full-thickness tears, $n = 9$	
-Articular-sided partial-thickness tears, $n = 62$	71 (18.9%)
Subscapularis	23 (6.1%)
Labral lesions (Bankart lesions, posterior Bankart lesions, labral fraying) from the 2-o'clock to 10-o'clock position	73 (19.4%)
<i>Patients with at least 1 biceps complex lesion</i>	97 (25.8%)
SLAP 1 lesion	60 (16.0%)
SLAP 2 lesion or higher	20 (5.3%)
Intra-articular biceps tear	18 (4.8%)
Pulley lesions/ biceps instability	14 (3.7%)
Chondral lesions of the humeral head or the glenoid	38 (10.1%)
Total number of patients with concomitant lesions	$n = 201$ of 376 (53.5%)
Total number of concomitant lesions	$n = 317$
Number of patients with >1 lesions	$n = 84$ (22.3%)

Overall, 45 patients (12.0%) had one or more CGP that required an additional reconstructive procedure (Table 2). The remaining 156 patients (41.5%) with CGP received a debridement of their lesion(s) only

Table 2 Concomitant lesions that were treated with an additional reconstructive procedure [DR RCR = double-row rotator cuff repair; PASTA = partial articular supraspinatus tendon avulsion; SLAP = superior labrum anterior posterior]

Total reconstructed concomitant lesions	Number	Procedure
Rotator cuff lesions	19 (5.1%)	
Supraspinatus		
-Full-thickness tears, $n = 9$		$n = 9$ DR RCR
-Articular-sided partial-thickness tears, $n = 1$	10	$n = 1$ PASTA repair
Subscapularis tears	9	$n = 1$ healing response [43] 8 repairs
Labral lesions (i.e., Bankart or posterior Bankart lesions) from the 2-o'clock to 10-o'clock position	9	$n = 9$ repairs
Biceps complex lesion	36 (9.6%)	
SLAP lesions (type 2, 3, or 4 according to Snyder et al.)	15	$n = 8$ SLAP repairs $n = 14$ biceps tenodesis
Intra-articular biceps degeneration/tear	13	$n = 13$ biceps tenodesis
Pulley lesions and/or biceps instability	8	$n = 8$ biceps tenodesis
Chondral lesions of the humeral head or the glenoid	2	$n = 2$ microfracture
Total number of patients with reconstructed concomitant lesions	45 (12.0%)	
Total number of reconstructed concomitant lesions	$n = 61$	

percent of the patients had at least one CGP with lesions of the biceps tendon complex (especially SLAP lesions) and lesions of the rotator cuff being the two most common.

Patients with a Rockwood grade V AC joint injury were significantly more likely to have a CGP (114/190, 60%) than patients with a grade III injury (87/186, 46.8%; $p = 0.013$; odds ratio 1.7). Patients with a chronic AC joint injury were significantly more likely to have a CGP (90/147, 61.2%) than patients with an acute injury (111/229, 48.5%; $p = 0.019$; odds ratio 1.7). Gender was not associated with a higher risk for having CGP (female 22/40, 55%; male 179/336, 53.3%; $p = 0.87$; odds ratio 0.93). The probability of having a CGP was significantly associated with increasing age ($p < 0.0001$; Table 3, Fig. 2).

Although a significant difference in occurrence of CGP was seen between Rockwood grades III and V AC joint injuries, and between acute and chronic injuries, age was found to be the most dominant predictor (Fig. 3).

Table 3 Concomitant glenohumeral pathologies (CGP) per decade of age

Decade of age (years)	Number of patients with no CGP (n)	Number of patients with CGP (n)	Percentage of patients with no CGP (%)	Percentage of patients with CGP (%)
10s	12	3	80.0	20.0
20s	51	28	64.6	35.4
30s	36	34	51.4	48.6
40s	48	63	43.2	56.8
50s	17	40	29.8	70.2
60s	10	26	27.8	72.2
70s	1	7	12.5	87.5

Patients with a chronic AC joint injury were more likely to present with a CGP within the first 20 weeks after the trauma and then again at a year or more after the injury (Fig. 4). The time from injury of approximately 20–50 weeks had the lowest risk for patients with a chronic injury to present with a CGP.

There was no significant association between the Rockwood grade ($p = 0.20$) and the need for an additional reconstructive procedure. Patients with chronic AC joint injuries were more likely to have a CGP that needed additional reconstruction ($p = 0.02$; odds ratio 2.1). The likelihood to need additional reconstructive surgery was significantly associated with age ($p = 0.03$; Table 4, Fig. 5).

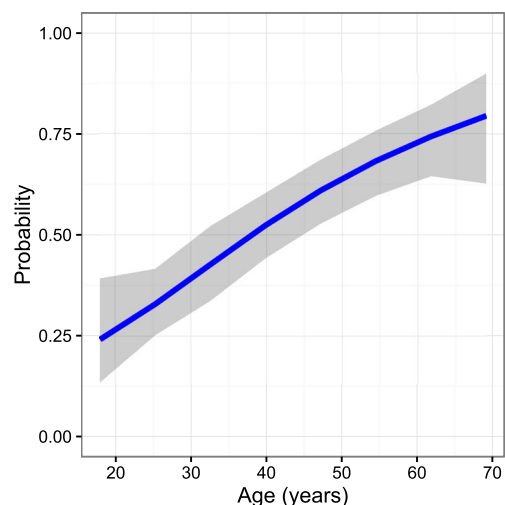
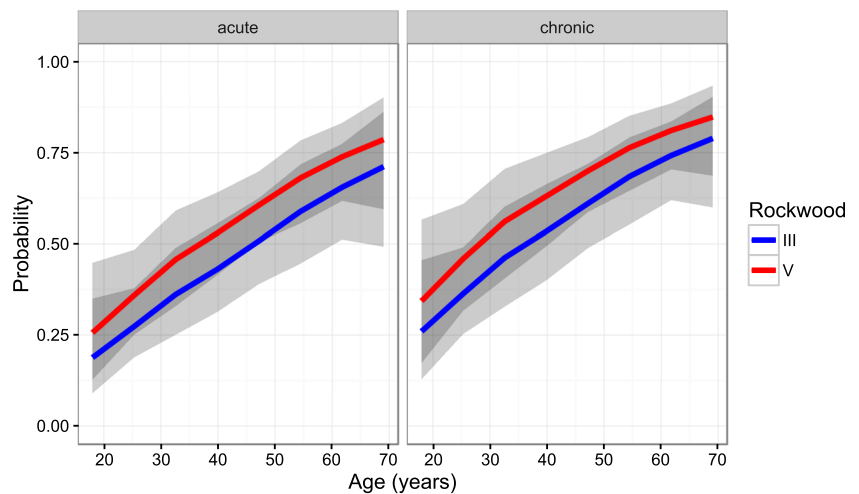
**Fig. 2** Association of the modeled probability of having concomitant glenohumeral pathology with age (e.g., probability of 0.4 = 40%)

Fig. 3 Modeled probability of having concomitant glenohumeral pathology depending on age, Rockwood grade, and acute or chronic AC joint injury (e.g., Probability of 0.4 = 40%)



Discussion

The most important finding of this study was that CGP can be expected in more than 50% of surgically treated patients older than 30 years with an acute or chronic AC joint injury of either grade III or V. In addition, although a significant difference in occurrence of CGP was seen between Rockwood grades III and V, and between acute and chronic lesions, age was identified as the most dominant predictor. Overall, 12.0% of the patients had one or more CGP that required an additional reconstructive procedure.

The prevalence of CGP associated with surgically treated AC joint injuries has previously been reported to lie somewhere between 15 and 43% [12, 17, 19, 20, 23, 24]. Tischer et al. in 2009 found 14 CGP among 77 patients (18.2%) and concluded that CGP obtained during traumatic AC joint separation may be more frequent than previously thought [24]. The authors furthermore found CGP associated with the AC joint injury in

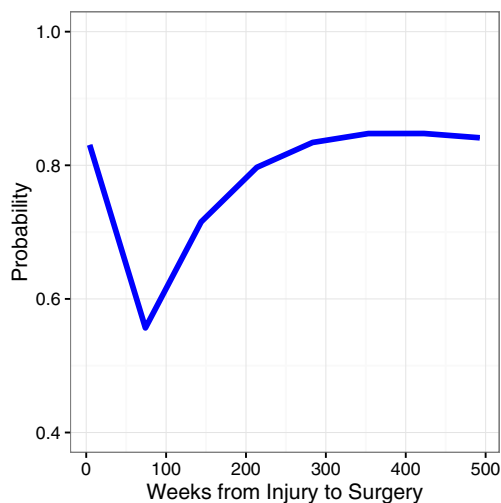


Fig. 4 Relationship between the duration since trauma and the modeled probability of presenting with concomitant glenohumeral pathology for patients with a chronic AC joint injury (e.g., probability of 0.7 = 70%)

patients with Rockwood grade IV and grade V injuries, but not in patients with Rockwood grade III injuries. Pauly et al. published similar results among 40 patients with AC joint injuries in 2009, and described traumatic intraarticular lesions in 15% of the patients [19]. In 2012, Pauly et al. tried to distinguish between acute intra-articular lesions, related to the trauma which caused the AC joint injury, and degenerative lesions, considered to be unrelated to the recent trauma, among 125 patients [20]. Their study showed a high prevalence (30%) of CGP, of which some indicated for an additional arthroscopic surgical procedure. The authors also found difficulties in differentiating the cause of each CGP. In 2014, Arrigoni et al. reported on associated lesions requiring additional surgical treatment in grade III AC joint dislocations with an attempt to identify patients at risk [23]. The authors found CGP in 43% of 98 patients with surgical treatment of a Rockwood grade III injury, and 29.5% of all patients required an additional dedicated reconstructive procedure. The increasing percentage of CGP detected over time may be related to an increased awareness of CGP. For their attempt to identify patients at risk, Arrigoni et al. used an arbitrary cutoff age between younger (<45 years) and older patients (>45 years), and also an arbitrary definition of acute (<30 days) and chronic (>120 days) injuries [23]. The authors found that the frequency of CGP was significantly associated with age older than 45 years.

Despite these prior publications, the probability of missing a diagnosis of CGP if AC joint stabilization surgery is performed without glenohumeral arthroscopy remains unclear for individual patients dependent on the type of lesion (Rockwood III vs V, acute vs chronic injury) and the patients' age. Apart from a high suspicion of additional pathologies during clinical examination, possible consequences included additional preoperative imaging, such as ultrasound and/or MRI, or arthroscopic treatment of all AC joint injuries in order to not miss clinically relevant CGP.

The data presented in this study can help determine the probability of individual patients with acute or chronic, grade

Table 4 Concomitant glenohumeral pathologies (CGP) with the need for an additional reconstructive procedure per decade of age

Decade of age (years)	Number of patients with CGP not requiring additional reconstructive procedure (n)	Number of patients with CGP requiring additional reconstructive procedure (n)	Percentage of patients with CGP not requiring additional reconstructive procedure (%)	Percentage of patients with CGP requiring additional reconstructive procedure (%)
10s	14	1	93.3	6.7
20s	75	4	94.9	5.1
30s	62	8	88.6	11.4
40s	95	16	85.6	14.4
50s	51	6	89.5	10.5
60s	28	8	77.8	22.2
70s	6	2	75.0	25.0

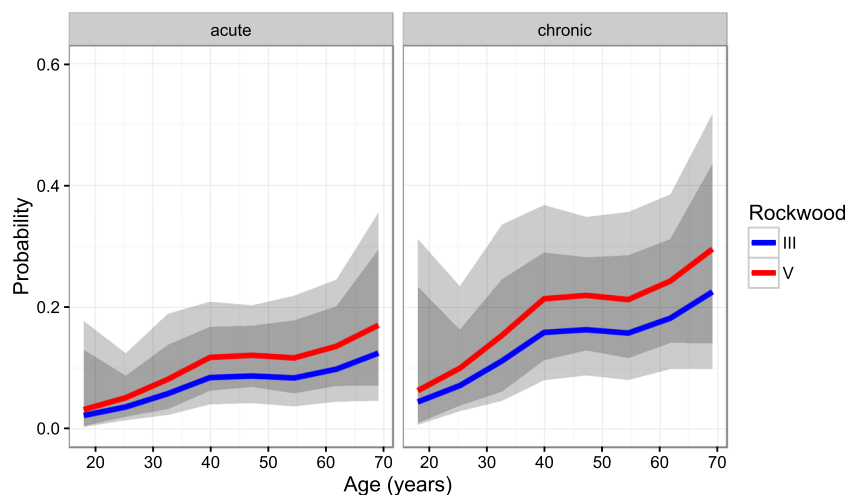
III or grade V AC joint injuries to have a CGP. Considering the fact that CGP are common and many of the CGP require additional surgery, the knowledge of the probability for an individual patient to have an additional CGP associated with the AC joint injury seems clinically relevant. On one hand, it is important for appropriate consultation of the patient during the clinic visit, and on the other hand, it allows for adequate planning of the procedure and the associated surgical time. It is in the patient's best interest to identify and treat CGP at the time of the index surgery in order to avoid future surgery, additional rehabilitation time, and inferior outcomes.

Although there is a generally high correlation between MRI and arthroscopic pathologic findings in the shoulder joint [28], the importance of MRI for the diagnosis of CGP of AC joint injuries still needs to be determined [20]. Specifically, MRI has the lowest sensitivity and specificity concerning the diagnosis of anterior shoulder structures, which were commonly affected in association with AC joint injuries [18, 28]. MRI has previously been used to describe findings of AC joint dislocation in comparison with radiographic findings, and to evaluate CC and AC ligaments under stress, but special protocols are needed to visualize the CC and AC ligaments [29–31]. However, none of the aforementioned studies

reported on eventual CGP. Generally, it has to be noted that MRI imaging does not represent the imaging modality of first choice in diagnosing AC joint injuries [29].

Arthroscopically-assisted and open surgical treatment of high grade AC joint injuries were found to have similar outcomes after minimum two year follow up [12, 32]. Arthroscopically-assisted procedures, however, offer the possibility to diagnose and treat CGP [12, 17, 19, 20, 23, 24]. It is important to notice that to date it remains unclear if the treatment of these CGPs improve the patient's outcome in comparison to leaving the CGP untreated. In addition to a potential benefit from the possibility to treat CGP, no secondary implant removal is necessary, and non-rigid arthroscopically assisted CC fixation was recently found to provide better quality-of-life outcomes than hook plate fixation [14]. Techniques with less cortical drilling and smaller drill-holes recently helped to reduce complication rates of initial arthroscopic-assisted techniques, which were previously found to be as high as 27.1% [33, 34]. For those who still prefer to perform AC joint reconstruction with hook-plate fixation, it may be relevant that arthroscopy has also recently been combined with hook-plate fixation of AC joint dislocations [35].

Fig. 5 Relationship between the modeled probability of having concomitant glenohumeral pathology with the need for an additional reconstructive procedure and age, Rockwood grade, and acute or chronic AC joint injury (e.g., probability of 0.1 = 10%)



Generally, it seems difficult to judge which CGP were preexisting and non-symptomatic, which CGP were caused by the same trauma as the AC joint injury, and which CGP may cause persistent shoulder pain [20, 36]. Although Pauly et al. distinguished between traumatic and degenerative cause of the CGP, the authors had difficulties in differentiating the cause of each CGP. Especially in patients with a long, chronic history of AC-joint injury, this question becomes even more complicated to answer. The relevance of the CGP that were treated with debridement only remains unclear and will not be answered by this study. Progression of partial-thickness rotator cuff tears to full-thickness rotator cuff tears has been described [37, 38], and a substantial percentage of asymptomatic rotator cuff tears becomes symptomatic and undergoes anatomic deterioration [39]. At least in the context of partial-thickness rotator cuff tears, debridement may have a certain importance. On the other hand, in some instances there may be the risk of ‘over-treatment’ of CGP that may not have become clinically apparent. Future investigations will be needed to clarify which CGP should be treated to achieve improved outcomes and which can be left untreated or neglected.

The higher prevalence of CGP among patients with grade V AC joint injuries may be explained by the more severe injury pattern with disruption of the deltoid fascia, which is likely caused by more severe trauma mechanisms. The fact that CGP were more common in patients with chronic injuries may be explained by the selection bias of patients with ongoing symptoms caused by a CGP. Arrigoni et al. accordingly found a higher percentage of CGP in patients with chronic AC joint injuries compared to acute lesions but their study was likely underpowered to detect a significant difference [23]. Among patients with arthroscopic treatment of chronic AC joint injuries, CGP showed a bimodal distribution. The first peak occurred between weeks 4 to 20, and may be caused by patients for which non-operative treatment of AC joint injuries was unsuccessful due to symptomatic CGP. In this context, more than two-thirds of patients with failure of non-operative treatment after grade III AC joint injury were recently found to present with some kind of CGP [8]. The second peak began in the second year after the injury. Secondary symptoms associated with CGP may be caused by the effect of persistent scapular dyskinesia which can be found after non-operative and operative treatment of AC joint injuries, and may create or exacerbate abnormal glenohumeral kinematics and can subsequently cause articular pathologies [14, 15, 31, 40–42].

Limitations

As a limitation of this study, no sub-analysis was possible for Rockwood IIIA and IIIB injuries as radiographic analysis of horizontal instability recently evolved and was not retrospectively available for many of these patients with Rockwood grade III injury. The patient population presenting with AC joint

injuries may vary considerably among different centres. The fact that the data of two high-volume surgical centres located in different continents were combined, and a large number of patients were included are considered strengths of this study.

Conclusion

Concomitant glenohumeral pathologies were observed in 53% of surgically treated patients with an acute or chronic AC joint injury of either grade III or V. Twenty-two percent of these patients with CGP received an additional dedicated reconstructive surgical procedure. Although a significant difference in occurrence of CGP was seen between Rockwood grades III and V, and between acute and chronic lesions, increasing age was identified as the most dominant predictor.

Acknowledgments The authors thank Grant J. Dorman, MSc, for his assistance with statistical analysis.

Compliance with ethical standards

Conflict of interests Dr. Millett receives research support from Steadman Philippon Research Institute (SPRI), Vail, Colorado and corporate sponsorship for SPRI is received from Smith & Nephew, Arthrex, Siemens, Ossur and Vail Valley medical Center. He is a consultant for Arthrex Inc., Naples, FL. and Myos Inc. and receives Royalties from Arthrex and Springer Publishing. He has stock or stock options in GameReady and VuMedi.

Dr. Katthagen’s research position at SPRI was sponsored by Arthrex Inc., for the calendar year. Prof. Dr. Lill is a consultant for Arthrex and DePuySynthes.

The other authors state, that there is no conflict of interests.

References

- Chillemi C, Franceschini V, Dei Giudici L et al (2013) Epidemiology of isolated acromioclavicular joint dislocations. *Emerg Med Int* 2013:171609
- Pallis M, Cameron KL, Svoboda SJ, Owens BD (2012) Epidemiology of acromioclavicular joint injury in young athletes. *Am J Sports Med* 40(9):2072–2077
- Lynch TS, Saltzman MD, Ghodasra JH, Bilimoria KY, Bowen MK, Nuber GW (2013) Acromioclavicular joint injuries in the National Football League: epidemiology and management. *Am J Sports Med* 41(12):2904–2908
- Rockwood C (1984) Injuries in the acromioclavicular joint: subluxations and dislocations about the shoulder. In: Rockwood CA Jr, Green D (eds) *Fracture in adults*. Lippincott, Philadelphia, pp 890–910
- Beitzel K, Mazzocca AD, Bak K et al (2014) ISAKOS upper extremity committee consensus statement on the need for diversification of the Rockwood classification for acromioclavicular joint injuries. *Arthroscopy* 30(2):271–278
- Korsten K, Gunning AC, Leenen LPH (2014) Operative or conservative treatment in patients with Rockwood type III acromioclavicular dislocation: a systematic review and update of current literature. *Int Orthop* 38(4):831–838

7. Modi CS, Beazley J, Zywiell MG, Lawrence TM, Veillette CJ (2013) Controversies relating to the management of acromioclavicular joint dislocations. *Bone Joint* 95-B(12):1595–1602
8. Petri M, Warth RJ, Greenspoon JA, Horan MP, Abrams RF, Kokmeyer D, Millett PJ (2016) Clinical results after conservative Management for Grade III acromioclavicular joint injuries: does eventual surgery affect overall outcomes? *Arthroscopy* 32(5): 740–746
9. Tauber M (2013) Management of acute acromioclavicular joint dislocations: current concepts. *Arch Orthop Trauma Surg* 133(7): 985–995
10. Warth RJ, Martetschlager F, Gaskill TR, Millett PJ (2013) Acromioclavicular joint separations. *Curr Rev Musculoskelet Med* 6(1):71–78
11. De Carli A, Lanzetti RM, Ciompi A, Lupariello D, Rota P, Ferretti A (2015) Acromioclavicular third degree dislocation: surgical treatment in acute cases. *J Orthop Surg Res* 10:13
12. Jensen G, Katthagen JC, Alvarado LE, Lill H, Voigt C, (2014) Has the arthroscopically assisted reduction of acute AC joint separations with the double tight-rope technique advantages over the clavicular hook plate fixation? *Knee Surg Sports Traumatol Arthrosc* 22(2): 422–430
13. Millett PJ, Horan MP, Warth RJ (2015) Two-year outcomes after primary anatomic coracoclavicular ligament reconstruction. *Arthroscopy* 31(10):1962–1973
14. Natera-Cisneros L, Sarasquete-Reiriz J, Escola-Benet A, Rodriguez-Miralles J (2015) Acute high-grade acromioclavicular joint injuries treatment: arthroscopic non-rigid coracoclavicular fixation provides better quality of life outcomes than hook plate ORIF. *Orthop Trauma Surg Res* 102(1):31–39
15. Rasmont Q, Delloye C, Bigare E, Isacker TV (2015) Is conservative treatment still defensible in grade III acromioclavicular dislocation? Are there predictive factors of poor outcome? *Acta Orthop Belg* 81(1):107–114
16. Rosslenbroich SB, Schliemann B, Schneider KN et al (2015) Minimally invasive coracoclavicular ligament reconstruction with a flip-button technique (MINAR): clinical and radiological midterm results. *Am J Sports Med* 43(7):1751–1757
17. Jensen G, Katthagen JC, Alvarado L, Lill H, Voigt C (2013) Arthroscopically assisted stabilization of chronic AC-joint instabilities in GraftRope™ technique with an additive horizontal tendon augmentation. *Arch Orthop Trauma Surg* 133(6):841–851
18. Lorbach O, Trennheuser C, Anagnostakos K (2014) Diagnostic and therapy of isolated lesions of the proximal biceps. *Obere Extrem* 9: 10–16
19. Pauly S, Gerhardt C, Haas NP, Scheibel M (2009) Prevalence of concomitant intraarticular lesions in patients treated operatively for high-grade acromioclavicular joint separations. *Knee Surg Sports Traumatol Arthrosc* 17(5):513–517
20. Pauly S, Kraus N, Greiner S, Scheibel M (2013) Prevalence and pattern of glenohumeral injuries among acute high-grade acromioclavicular joint instabilities. *J Shoulder Elb Surg* 22(6): 760–766
21. Tauber M, Valler D, Lichtenberg S, Magosch P, Moroder P, Habermeyer P (2016) Arthroscopic stabilization of chronic acromioclavicular joint dislocations: triple-versus single-bundle reconstruction. *Am J Sports Med* 44(2):482–489
22. Beitzel K, Obopilwe E, Apostolakis K et al (2014) Rotational and translational stability of different methods for direct acromioclavicular ligament repair in anatomic acromioclavicular joint reconstruction. *Am J Sports Med* 42(9):2141–2148
23. Arrigoni P, Brady PC, Zottarelli L et al (2014) Associated lesions requiring additional surgical treatment in grade 3 acromioclavicular joint dislocations. *Arthroscopy* 30(1):6–10
24. Tischer T, Salzmann GM, El-Azab H, Vogt S, Imhoff AB (2009) Incidence of associated injuries with acute acromioclavicular joint dislocations types III through V. *Am J Sports Med* 37(1):136–139
25. Flint JH, Wade AM, Giuliani J, Rue JP (2014) Defining the terms acute and chronic in orthopaedic sports injuries: a systematic review. *Am J Sports Med* 42(1):235–241
26. Snyder SJ, Karzel RP, Del Pizzo W, Ferkel RD, Friedman MJ (1990) SLAP lesions of the shoulder. *Arthroscopy* 6(4):274–279
27. R Core Team (2015) R: A language and environment for statistical computing. R foundation for statistical computing, Vienna
28. Momenzadeh OR, Gerami MH, Sefidbakht S, Dehghani S (2015) Assessment of correlation between MRI and arthroscopic pathologic findings in the shoulder joint. *Arch Bone Jt Surg* 3(4):286–290
29. Alyas F, Curtis M, Speed C, Saifuddin A, Connell D (2008) MR imaging appearances of acromioclavicular joint dislocation. *Radiographics* 28(2):463–479
30. Izadpanah K, Winterer J, Vicari M et al (2013) A stress MRI of the shoulder for evaluation of ligamentous stabilizers in acute and chronic acromioclavicular joint instabilities. *J Magn Reson Imaging* 37(6):1486–1492
31. Nemeč U, Oberleitner G, Nemeč SF et al (2011) MRI versus radiography of acromioclavicular joint dislocation. *AJR Am J Roentgenol* 197(4):968–973
32. Jensen G, Ellwein A, Voigt C, Katthagen JC, Lill H (2015) [Injuries of the acromioclavicular joint: hook plate versus arthroscopy]. *Unfallchirurg* 118(12):1041–1055 (in German)
33. Martetschlager F, Horan MP, Warth RJ, Millett PJ (2013) Complications after anatomic fixation and reconstruction of the coracoclavicular ligaments. *Am J Sports Med* 41(12):2896–2903
34. Spiegl UJ, Smith SD, Euler SA, Dornan GJ, Millett PJ, Wijdicks CA (2014) Biomechanical consequences of coracoclavicular reconstruction techniques on clavicle strength. *Am J Sports Med* 42(7): 1724–1730
35. Gille J, Heinrichs G, Unger A, Riepenhof H, Herzog J, Kienast B, Oheim R (2013) Arthroscopic-assisted hook plate fixation for acromioclavicular joint dislocation. *Int Orthop* 37(1):77–82
36. Gill TK, Shanahan EM, Allison D, Alcorn D, Hill CL (2014) Prevalence of abnormalities on shoulder MRI in symptomatic and asymptomatic older adults. *Int J Rheum Dis* 17(8):863–871
37. Mall NA, Kim HM, Keener JD et al (2010) Symptomatic progression of asymptomatic rotator cuff tears: a prospective study of clinical and sonographic variables. *J Bone Joint Surg Am* 92(16):2623–2633
38. Maman E, Harris C, White L, Tomlinson G, Shashank M, Boyton E (2009) Outcome of nonoperative treatment of symptomatic rotator cuff tears monitored by magnetic resonance imaging. *J Bone Joint Surg Am* 91(8):1898–1906
39. Moosmayer S, Tarig R, Smith HJ (2013) The natural history of asymptomatic rotator cuff tears: a three-year follow-up of fifty cases. *J Bone Joint Surg Am* 95(14):1249–1255
40. Kibler WB, Sciascia A, (2016) The role of the scapula in preventing and treating shoulder instability. *Knee Surg Sports Traumatol Arthrosc* 24(2):390–397
41. Ludewig PM, Reynolds JF (2009) The association of scapular kinematics and glenohumeral joint pathologies. *J Orthop Sports Phys Ther* 39(2):90–104
42. Nowotny J, Kopkow C, Mauch F, Kasten P (2016) Effective rehabilitation in patients with scapular dyskinesis. *Obere Extrem* 11(1): 40–46
43. Osti L, Del Buono A, Maffulli N (2013) Microfractures at the rotator cuff footprint: a randomized controlled study. *Int Orthop* 37(11):2165–2171