

Isolated Biceps Reflection Pulley Tears Treated With Subpectoral Biceps Tenodesis: Minimum 2-Year Outcomes



Alexander R. Vap, M.D., J. Christoph Katthagen, M.D., Dimitri S. Tahal, M.Sc.,
Marilee P. Horan, M.P.H., Erik M. Fritz, M.D., Jonas Pogorzelski, M.D., M.H.B.A., and
Peter J. Millett, M.D., M.Sc.

Purpose: To investigate if patients younger than 50 years old had improved functional outcomes after subpectoral biceps tenodesis (BT) for the treatment of biceps reflection pulley (BRP) lesions at minimum 2-year postoperative follow-up. **Methods:** Patients who had arthroscopically confirmed BRP tears that were treated with subpectoral BT and were at least 2 years out from surgery were included; patients were excluded if they had concomitant reconstructive or reparative procedures at index surgery. Patient-centered outcomes including return to activity, American Shoulder and Elbow Surgeons (ASES), Quick Disabilities of the Arm, Shoulder and Hand (QuickDASH), and Short Form-12 Physical Component Summary (SF-12 PCS) scores, and patient satisfaction were collected. The pre- and postoperative scores were compared with a Wilcoxon test. Failure was defined as revision BT. **Results:** Between January 2006 and July 2014, of 1,184 patients who underwent open subpectoral BT, 14 patients (6 male, 8 female) with mean age 37 (range, 16-49 years) met the inclusion criteria. Minimum 2-year outcomes data were available for all 14 patients (100% follow-up). The mean follow-up was 3.6 ± 1.3 years. There were significant improvements postoperatively for all outcome scores ($P = .017$ ASES, $P = .002$ QuickDASH, $P = .003$ SF-12 PCS). There was no correlation between age and outcome scores ($P > .05$). Median patient satisfaction was 9 of 10. Five patients (36%) reported return to recreational activity with no modifications; 9 (64%) indicated a return to activity with modifications. The 5 patients who returned to recreational activity with no modification had significantly less time from initial injury/onset of symptoms until surgery in comparison with the 9 patients who modified their activity ($P = .028$). No complications or reoperations were reported. **Conclusions:** Patients younger than 50 years old with a symptomatic isolated BRP lesion experienced excellent results, high return to recreational activity, little postoperative pain, and high degrees of satisfaction when treated with subpectoral BT. **Level of Evidence:** Level IV, therapeutic case series.

See commentary on page 1795

From the Steadman Philippon Research Institute (A.R.V., J.C.K., D.S.T., M.P.H., E.M.F., J.P., P.J.M.); and the Steadman Clinic (A.R.V., P.J.M.), Vail, Colorado, U.S.A.

The authors report the following potential conflicts of interest or sources of funding: A.R.V. receives support from Steadman Philippon Research Institute. J.C.K. receives support from Smith & Nephew, Ossur, Siemens, and Arthrex. D.S.T., M.P.H., and E.M.F. receive support from Steadman Philippon Research Institute. J.P. receives support from Steadman Philippon Research Institute and Arthrex. P.J.M. receives support from Arthrex, Medbridge, Springer Publishing, the Steadman Clinic, Smith & Nephew, Siemens, Össur, GameReady, and VuMedi.

Received December 21, 2016; accepted April 12, 2017.

Address correspondence to Peter J. Millett, M.D., M.Sc., Center for Outcomes-based Orthopaedic Research, Steadman Philippon Research Institute, 181 West Meadow Drive, Suite 1000, Vail, CO 81657, U.S.A. E-mail: armillett@thesteadmanclinic.com

© 2017 by the Arthroscopy Association of North America
0749-8063/161281/16\$36.00

<http://dx.doi.org/10.1016/j.arthro.2017.04.021>

Lesions of the long head of the biceps (LHB) tendon are commonly recognized as generators of anterior shoulder pain.¹⁻³ In particular, disruption of the biceps reflection pulley (BRP) has been shown to be part of the differential considered when evaluating the LHB and anterior shoulder pain.⁴ The BRP is a capsuloligamentous complex that stabilizes the LHB tendon in the bicipital groove and is composed of 4 major structures: the superior glenohumeral ligament, the coracohumeral ligament, the upper margin of the subscapularis (SSC) tendon, and anterior fibers of the supraspinatus (SSP) tendon.^{5,6} More precisely, the BRP is located within the rotator interval between the anterior edge of the SSP tendon and the superior edge of the SSC tendon.^{6,7} Recent biomechanical work by Braun et al.⁸ has shown that BRP lesions may be a

direct result of increased shear loads in a forward flexion position with internal or neutral rotation, and in a neutral arm position with internal rotation. Le Huec et al.⁹ similarly described a fall on the outstretched arm in combination with full external or internal rotation, as well as a fall backward on the hand or elbow as a trigger for pulley lesions. In contrast, Gerber and Sebesta¹⁰ reported repetitive forceful internal rotation above the horizontal plane as the inciting cause. Although there is no specific consensus on the mechanism of BRP lesions, it is likely a combination of chronic lesions and acute triggers that are responsible for most BRP lesions.¹¹ Because of the infrequent occurrence, surgical management of this pathology, in particular biceps tenodesis (BT), has not been thoroughly evaluated; however, BRP lesions do have the potential to diminish patient quality of life and prevent patients from engaging in sports and other recreational activities.^{2,4,11} Indeed, surgeons and patients may have concerns regarding BT in young and active patients under the age of 50 years because this procedure is more common in elderly people.¹²

Therefore, the purpose of the study was to investigate if patients younger than 50 years old had improved functional outcomes after subpectoral BT for the treatment of BRP lesions at minimum 2-year postoperative follow-up. Further goals were to determine whether a correlation exists between patient age and clinical outcome scores and to ascertain the ability of patients to return to activity. It was hypothesized that subpectoral BT would result in reduced pain, improved functional outcomes, and a high return-to-activity rate.

Methods

Study Population

An institutional review board approved, retrospective review using prospectively collected data of a single-surgeon series (P.J.M.) from January 2006 to July 2014 identified patients meeting the following inclusion criteria: arthroscopically confirmed diagnosis of a symptomatic BRP lesion (all Bennett types, [Table 1](#),

Table 1. Bennett Classification of Biceps Subluxation Instability¹³

Type 1: injury of the intra-articular subscapularis tendon without involvement of the medial head of the coracohumeral ligament (CHL)
Type 2: injury of the medial sheath (composed of the superior glenohumeral ligament-medial CHL ligament complex), without subscapularis involvement
Type 3: injury involving both the medial sheath and subscapularis tendon
Type 4: injury involving the supraspinatus and lateral head of the CHL
Type 5: injury involving all structures: intra-articular subscapularis tendon, medial sheath, supraspinatus tendon, and lateral CHL

[Fig 1](#)), self-reported history of a previous sport activity with involvement of the injured shoulder, less than 50 years of age, and a minimum period of 2 years from index surgery.^{14,15} Patients were deemed to have an isolated BT if there was no concomitant reconstructive or reparative procedure at the same time. Subacromial decompression (SAD) with or without partial acromioplasty, subcoracoid decompression (SCD), and SSP debridement were not categorized as reconstructive or reparative procedures. When the time from injury to surgery was over a year, the BRP lesions were considered chronic. Subjective evaluations were obtained preoperatively and after a minimum 2-year follow-up postoperatively with the American Shoulder and Elbow Surgeons (ASES); Quick Disabilities of the Arm, Shoulder and Hand; and Short Form-12 Physical Component Summary scores, including asking patients for "pain during activities of daily living," "pain during work," "pain in recreational activities," and "pain when lying on the shoulder." Patients were also asked about their general ability to "return to recreational activity" at the latest follow-up and the answer choices included return to activities: (1) Yes with no modifications, (2) Yes with modifications, and (3) No.

Surgical Technique

Before surgery, all patients had positive physical examination findings for BRP lesions that were further confirmed with magnetic resonance imaging showing the lesion with biceps tendon subluxation. All patients underwent varying time periods of conservative management that included rest and supervised physical therapy. After failed conservative management, all patients were medically cleared for surgical intervention. Surgeries were performed using general anesthesia with additional interscalene nerve blocks. All patients were positioned in the beach-chair position. The operative extremity was placed in a pneumatic arm holder, and the shoulder was prepared and draped using the sterile technique. In every single case, a diagnostic arthroscopy was then performed using standard posterior and anterior portals and a 30° arthroscope. After identification of a BRP lesion ([Fig 2](#)), the LHB tendon was released arthroscopically/tenotomized for later open subpectoral BT. If any partial fraying of the rotator cuff was present, this was debrided. Diagnostic arthroscopy was continued, and debridement of the intra-articular structures and any other necessary nonreconstructive procedures, such as SAD and acromioplasty, SCD, debridement of partial SSC, or SSP cuff tear, were performed if indicated. Patients who had concomitant repair of the SSP or SSC were excluded.

After arthroscopy was concluded and all arthroscopic instruments were removed from the shoulder, a 2.5-cm incision was created in the proximal axillary crease and sharply taken down to the fascia of the

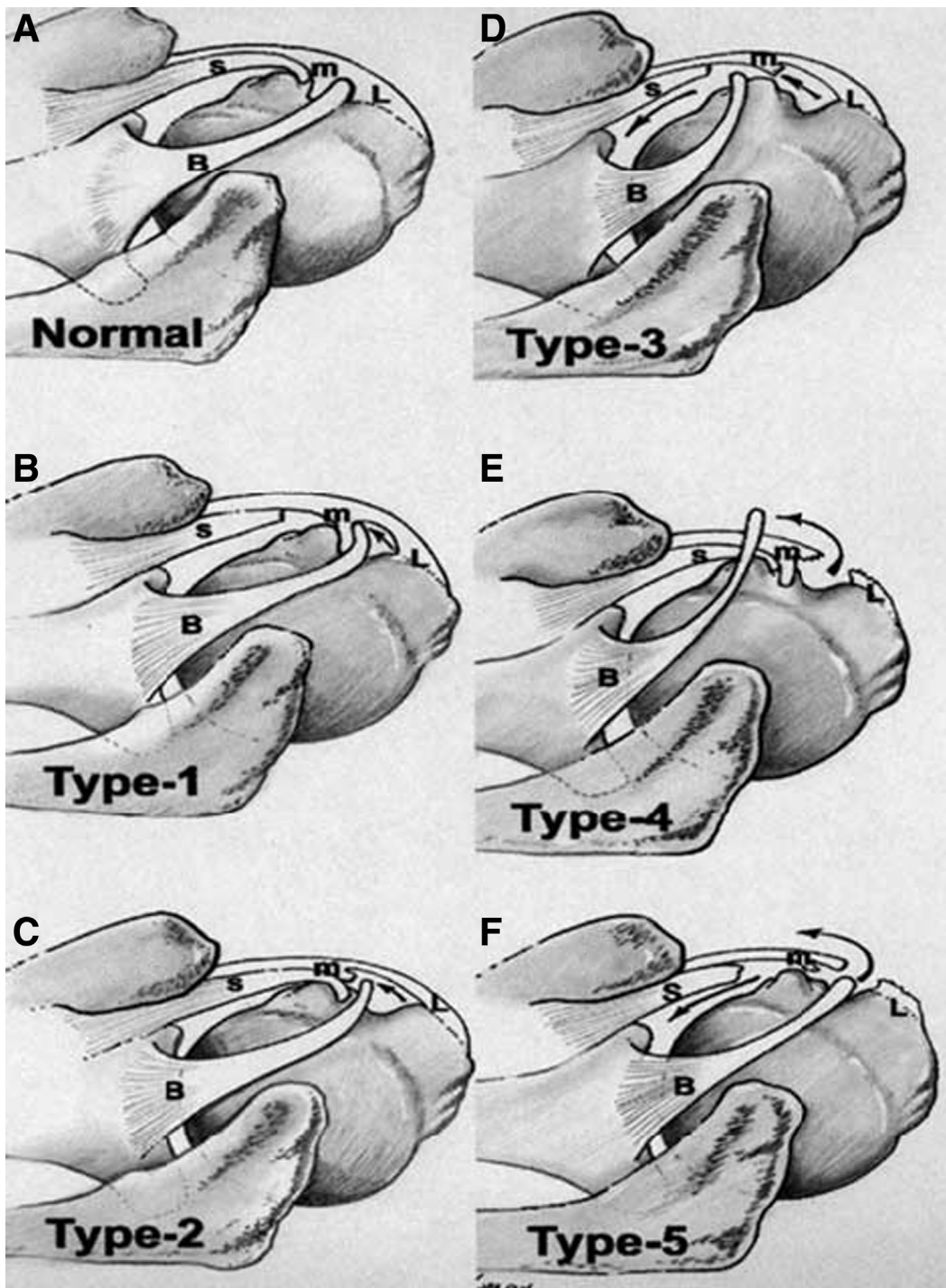


Fig 1. Bennett classification of biceps subluxation and instability.¹³ (A) Normal anatomy of the biceps reflection pulley. (B) Bennett type 1 lesion showing a tear of the subscapularis (SSC) without involvement of the medial head of the coracohumeral ligament (CHL). (C) Bennett type 2 lesion showing involvement of the medial head of the CHL without a tear of the SSC. (D) Bennett type 3 lesion showing both a tear of the SSC and involvement of the medial head of the CHL. (E) Bennett type 4 lesion showing tears of the supraspinatus (SSP) and the lateral head of the CHL. (F) Bennett type 5 lesion showing tears of the SSC and involvement of both the medial and lateral heads of the CHL, including the leading edge of the SSP. Arrows represent the direction of biceps subluxation/instability. (B, biceps; L, lateral head CHL; m, medial head CHL; S, SSC.)

short head of the biceps. The fascia between the pectoralis major and the short head of the biceps was incised, and the LHB was identified, extracted, and

whip-stitched close to the musculocutaneous junction. A 7- or 8-mm hole was drilled in the bicipital groove, and the biceps tendon was secured line to line using

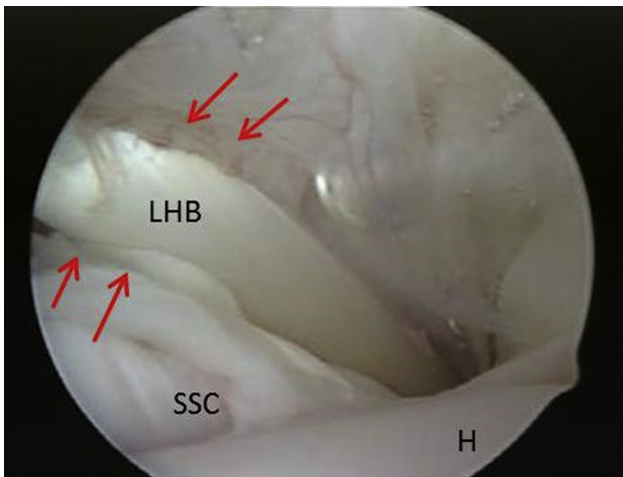


Fig 2. Right shoulder, posterior viewing portal. Bennett type 2 biceps reflection pulley lesion with disruption of the medial pulley (red arrows) and medial subluxation of the long head of the biceps (LHB). (H, humeral head; SSC, subscapularis tendon.)

the same diameter PEEK (polyether ether ketone) tenodesis screw, typically 7 × 10 mm or 8 × 12 mm (Arthrex, Naples, FL).¹⁶ All incisions were then closed and the surgery was ended.

Postoperatively, all shoulders were immobilized in a sling for 3 weeks. Patients were allowed early pendulum and passive range of motion exercises, with full passive, active-assisted, and active range of motion begun immediately after surgery. Strengthening and resisted elbow flexion were delayed until 6 weeks postoperatively. Full, unrestricted activities were typically permitted between 12 and 16 weeks postoperatively according to patient tolerance and kinematic progress.

Statistical Methods

Statistical analyses were performed using SPSS version 11.0 (SPSS, Chicago, IL). Because of the limited number of patients included, a formal post hoc power analysis was not performed. Instead the effect size of our study was generated directly from our sample size. In this data set, continuous variables were non-normally distributed. The pre- and postoperative scores of each patient were compared with a Wilcoxon test, and association between patient age and outcome

scores was investigated with a Spearman correlation test. The comparison of the 2 groups “return to activity without modification” and “return to activity with modification” concerning patient age, overhead activity, time from symptom onset to surgery, and patient satisfaction was performed with a Mann-Whitney *U* test. *P* values of less than .05 indicated statistical significance.

Results

Between January 2006 and July 2014, the senior surgeon (P.J.M.) performed 1,184 open subpectoral BT in total. A total of 1,170 patients were excluded because of concomitant reparative or reconstructive procedures. In 14 patients (14 shoulders), a subpectoral BT was specifically performed for BRP lesions, as defined in this study. Fourteen shoulders in 14 patients were eligible for inclusion (6 female, 8 male; mean age 37 years; range 16-49). Mean body mass index for these 14 patients was 28.4 (range 20.4-47.0) with 3 Workman’s Compensations claims. Minimum 2-year outcomes data were available for 14 patients (100%). The mean follow-up was 3.6 years (range, 2.0-6.8 years). The Bennett classification for the group was 10 = type II; 2 = type IV; 2 = type V.

Nonreconstructive concomitant procedures performed included SAD with partial acromioplasty, SCD, and debridement of partial-thickness SSP tear (Table 2).

All postoperative outcome scores improved significantly when compared with preoperative baselines (Table 3). There was no correlation between age and outcome scores ($P > .05$).

“Pain during activities of daily living” ($P = .015$), “pain during work” ($P = .006$), “pain in recreational activities” ($P = .007$), and “pain when lying on the shoulder” ($P = .011$) also improved significantly postoperatively for all patients.

For all 14 of the shoulders, the question concerning return to recreational activity was answered. Five (36%) of these shoulders were able to return to recreational activities with no modifications. Nine (64%) of these shoulders returned to recreational activities with modifications. There was a statistically significant

Table 2. Concomitant Procedures Performed

Concomitant Procedures	BRP Lesion, n
Subacromial decompression ± acromioplasty	14
Subcoracoid decompression	4
Debridement of supraspinatus partial tear	4
Debridement of subscapularis	2
Total number of concomitant procedures	22

BRP, biceps reflection pulley.

Table 3. Comparison of Pre- and Postoperative Outcome Parameters

Outcome Measure	Preoperative	Postoperative	Significance
ASES score	62 (33-80)	97 (28-100)	$P = .017^*$
QuickDASH	39 (11-70)	7 (0-54)	$P = .002^*$
SF-12 PCS	43 (22-58)	56 (39-59)	$P = .003^*$

NOTE. Numbers expressed as median (range).

ASES, American Shoulder and Elbow Surgeons; QuickDASH, Quick Disabilities of the Arm, Shoulder and Hand; SF-12 PCS, Short Form-12 Physical Component Summary.

*Indicates a significant difference.

Table 4. Intergroup Analysis of Outcomes Based On Return to Recreational Activity

	Return to Recreational Activity With no Modifications	Return to Recreational Activity With Modifications	Significance
Patients	5 patients	9 patients	
Age, mean \pm SD	36.0 \pm 12.3 yr	38.6 \pm 7.1 yr	$P = .43$
Overhead activity	3 patients	2 patients	$P = .58$
Time from symptom-onset to surgery, median (range)	215 (49-414) d	1375 (79-7472) d	$P = .028^*$
Median satisfaction, median (range)	10 (8-10)	8 (3-10)	$P = .024^*$

SD, standard deviation.

*Indicates a significant difference.

greater period of time between initial injury/onset of symptoms and BT for patients who modified their activities (Table 4). Patient age and whether they were involved in overhead sports were not statistically different between the 2 groups (Table 4). Patients with acute lesions had significantly higher postoperative ASES scores than patients with chronic lesions (acute mean 97.3, standard deviation 6.0; chronic mean 79.6; standard deviation 22.9; $P = .029$).

Sport involvement included both overhead and nonoverhead disciplines (Table 5). Overall, median patient satisfaction with the outcome of the procedure was 9 of 10 (range, 3-10). No patient required revision surgery and no intraoperative adverse events occurred.

Discussion

The most important finding of this study was that subpectoral BT for isolated BRP lesions resulted in excellent outcomes and high levels of patient satisfaction. In this study population in which all patients were less than 50 years old, age did not influence clinical outcomes. Patients who modified their activities were significantly more likely to have a longer period of time from injury/onset of symptoms to surgical management, indicating that increased chronicity of injury may have a negative impact on outcomes. Furthermore, there were no complications and no subsequent surgeries in this series.

Before this study, there had been limited work on evaluating the expected patient outcomes for surgical treatment of BRP lesions. Bennett¹⁷ evaluated arthroscopic repair of BRP lesions that affected both the medial and lateral wall in a prospective study including 18 patients. The authors reported significant improvement in the outcome measurements that were used (ASES index, Total Constant scores, Subjective Constant score, Objective Constant scores, visual analog scale, and percent function). However, that study revealed 1 patient (6%) with a postoperative biceps disruption and 2 patients (11%) with a recurrence of biceps inflammation. In addition, the BRP lesions in that study were in the setting of combined SSP and SSC tears that required repair, thus making it difficult to solely attribute their clinical improvement to the BRP

lesion repair. Other studies in the literature have focused on establishing the demographics and incidence of BRP lesions rather than treatment outcomes. Braun et al.⁸ found that BRP lesions were significantly associated with rotator cuff injury and SLAP tears. This was in agreement with studies by Walch et al.⁶ and Lafosse et al.,¹⁸ who reported a correlation between rotator cuff lesions and instability of the LHB tendon and/or pulley tears. No prior studies evaluated patients' abilities to return to recreational activity after the treatment of a BRP lesion. Although only 5 of 14 patients returned to full recreational activity without modifications, we do think that it is important that this appears to be related to whether the BRP lesion is treated early or in a delayed manner. Shorter time between injury/onset of symptoms until surgery appears to influence positively the patient's ability to return to preinjury recreational activities without any modifications. Moreover, patients with acute injuries had higher postoperative ASES scores than those with chronic injuries, which can most likely be explained by better tissue quality and a better intra-articular healing environment.

In our study, patients with nonreconstructive procedures (SAD with or without partial acromioplasty, and subcoracoid resection) were not excluded because the impact of these nonreconstructive procedures on other reconstructive procedures has been shown to be negligible.¹⁹⁻²⁴

Limitations

This study has several limitations. First, the inclusion criteria that were used to obtain a pure group did result in a limited study size. Although there has been an

Table 5. Sports Participation by Patients

	Primary Sport Indicated
Overhead	Swimming (1), racquetball (1), tennis (1), weightlifting (2), volleyball (1)
Nonoverhead	Alpine skiing (2), ice hockey (1), ballroom dancing (1), figure skating (1), backpacking (1)

NOTE. Two patients did not report a specific sport because of medical illness or pre-existing nonshoulder-related disability.

increase in the number of BT procedures being performed,¹² most are performed in combination with other reparative or reconstructive shoulder procedures, most commonly rotator cuff repair.^{12,25-28} This study attempted to isolate the clinical impact of BT by excluding patients who had concomitant reparative or reconstructive procedures. Although this does affect the overall power of our study, we still found improvements in clinical and patient-reported outcomes that provide valuable clinical information for both surgeons and patients. The limited power of the study could result in a type II error, which may be the reason why we found no difference in outcome scores at different ages. Moreover, although we attempted to isolate BRP lesions, concomitant procedures were still performed as outlined in Table 2; it is possible that these procedures had an impact on the observed benefit in outcome scores. Lastly, selection bias may be a factor as the senior surgeon treats patients at a sports medicine referral clinic with patients who are usually healthy and athletic. This potential bias could limit the generalizability of the findings to the population as a whole.

Conclusions

Patients younger than 50 years old with a symptomatic isolated BRP lesion experienced excellent results, high return to recreational activity, little postoperative pain, and high degrees of satisfaction when treated with subpectoral BT.

References

1. Becker DA, Cofield RH. Tenodesis of the long head of the biceps brachii for chronic bicipital tendinitis. Long-term results. *J Bone Joint Surg Am* 1989;71:376-381.
2. Elser F, Braun S, Dewing CB, Giphart JE, Millett PJ. Anatomy, function, injuries, and treatment of the long head of the biceps brachii tendon. *Arthroscopy* 2011;27:581-592.
3. Patzer T, Santo G, Olender GD, Wellmann M, Hirschler C, Schofer MD. Suprapectoral or subpectoral position for biceps tenodesis: Biomechanical comparison of four different techniques in both positions. *J Shoulder Elbow Surg* 2012;21:116-125.
4. Braun S, Horan MP, Elser F, Millett PJ. Lesions of the biceps pulley. *Am J Sports Med* 2011;39:790-795.
5. Gaskill TR, Braun S, Millett PJ. Multimedia article. The rotator interval: Pathology and management. *Arthroscopy* 2011;27:556-567.
6. Walch G, Nove-Josserand L, Levigne C, Renaud E. Tears of the supraspinatus tendon associated with "hidden" lesions of the rotator interval. *J Shoulder Elbow Surg* 1994;3:353-360.
7. Gleason PD, Beall DP, Sanders TG, et al. The transverse humeral ligament: A separate anatomical structure or a continuation of the osseous attachment of the rotator cuff? *Am J Sports Med* 2006;34:72-77.
8. Braun S, Millett PJ, Yongpravat C, et al. Biomechanical evaluation of shear force vectors leading to injury of the biceps reflection pulley: A biplane fluoroscopy study on cadaveric shoulders. *Am J Sports Med* 2010;38:1015-1024.
9. Le Huec JC, Schaefferbeke T, Moinard M, et al. Traumatic tear of the rotator interval. *J Shoulder Elbow Surg* 1996;5:41-46.
10. Gerber C, Sebesta A. Impingement of the deep surface of the subscapularis tendon and the reflection pulley on the anterosuperior glenoid rim: A preliminary report. *J Shoulder Elbow Surg* 2000;9:483-490.
11. Habermeyer P, Magosch P, Pritsch M, Scheibel MT, Lichtenberg S. Anterosuperior impingement of the shoulder as a result of pulley lesions: A prospective arthroscopic study. *J Shoulder Elbow Surg* 2004;13:5-12.
12. Werner BC, Brockmeier SF, Gwathmey FW. Trends in long head biceps tenodesis. *Am J Sports Med* 2015;43:570-578.
13. Bennett WF. Arthroscopic repair of anterosuperior (supraspinatus/subscapularis) rotator cuff tears: A prospective cohort with 2- to 4-year follow-up. Classification of biceps subluxation/instability. *Arthroscopy* 2003;19:21-33.
14. Bennett WF. Subscapularis, medial, and lateral head coracohumeral ligament insertion anatomy. Arthroscopic appearance and incidence of "hidden" rotator interval lesions. *Arthroscopy* 2001;17:173-180.
15. Snyder SJ, Karzel RP, Del Pizzo W, Ferkel RD, Friedman MJ. SLAP lesions of the shoulder. *Arthroscopy* 1990;6:274-279.
16. Millett PJ, Sanders B, Gobeze R, Braun S, Warner JJ. Interference screw vs. suture anchor fixation for open subpectoral biceps tenodesis: Does it matter? *BMC Musculoskelet Disord* 2008;9:121.
17. Bennett WF. Arthroscopic bicipital sheath repair: Two-year follow-up with pulley lesions. *Arthroscopy* 2004;20:964-973.
18. Lafosse L, Reiland Y, Baier GP, Toussaint B, Jost B. Anterior and posterior instability of the long head of the biceps tendon in rotator cuff tears: A new classification based on arthroscopic observations. *Arthroscopy* 2007;23:73-80.
19. Chahal J, Mall N, MacDonald PB, et al. The role of subacromial decompression in patients undergoing arthroscopic repair of full-thickness tears of the rotator cuff: A systematic review and meta-analysis. *Arthroscopy* 2012;28:720-727.
20. Gartsman GM, O'Connor DP. Arthroscopic rotator cuff repair with and without arthroscopic subacromial decompression: A prospective, randomized study of one-year outcomes. *J Shoulder Elbow Surg* 2004;13:424-426.
21. MacDonald P, McRae S, Leiter J, Mascarenhas R, Lapner P. Arthroscopic rotator cuff repair with and without acromioplasty in the treatment of full-thickness rotator cuff tears: A multicenter, randomized controlled trial. *J Bone Joint Surg Am* 2011;93:1953-1960.
22. Milano G, Grasso A, Salvatore M, Zarelli D, Deriu L, Fabbriani C. Arthroscopic rotator cuff repair with and without subacromial decompression: A prospective randomized study. *Arthroscopy* 2007;23:81-88.
23. Park YB, Koh KH, Shon MS, Park YE, Yoo JC. Arthroscopic distal clavicle resection in symptomatic acromioclavicular joint arthritis combined with rotator cuff tear:

- A prospective randomized trial. *Am J Sports Med* 2015;43:985-990.
24. Shin SJ, Oh JH, Chung SW, Song MH. The efficacy of acromioplasty in the arthroscopic repair of small- to medium-sized rotator cuff tears without acromial spur: Prospective comparative study. *Arthroscopy* 2012;28:628-635.
 25. Mazzocca AD, Cote MP, Arciero CL, Romeo AA, Arciero RA. Clinical outcomes after subpectoral biceps tenodesis with an interference screw. *Am J Sports Med* 2008;36:1922-1929.
 26. Checchia SL, Doneux PS, Miyazaki AN, et al. Biceps tenodesis associated with arthroscopic repair of rotator cuff tears. *J Shoulder Elbow Surg* 2005;14:138-144.
 27. Lee HI, Shon MS, Koh KH, Lim TK, Heo J, Yoo JC. Clinical and radiologic results of arthroscopic biceps tenodesis with suture anchor in the setting of rotator cuff tear. *J Shoulder Elbow Surg* 2014;23:e53-e60.
 28. Nho SJ, Frank RM, Reiff SN, Verma NN, Romeo AA. Arthroscopic repair of anterosuperior rotator cuff tears combined with open biceps tenodesis. *Arthroscopy* 2010;26:1667-1674.



In the Know, On the Go

Available
on all iOS
and Android
devices



Arthroscopyjournal.org

Get Access

bit.ly/ArthroscopyApp

Arthroscopy mobile app

Take advantage of your free *Arthroscopy* mobile app and take your journal with you anywhere you go!

Download **TODAY**

