

Surgical Anatomy of the Sternoclavicular Joint

A Qualitative and Quantitative Anatomical Study

Jared T. Lee, MD, Kevin J. Campbell, BS, Max P. Michalski, MSc, Katharine J. Wilson, MSc, Ulrich J.A. Spiegl, MD, Coen A. Wijdicks, PhD, and Peter J. Millett, MD, MSc

Investigation performed at the Department of BioMedical Engineering, Steadman Philippon Research Institute, Vail, Colorado

Background: The quantitative anatomical relationships of the main ligamentous, tendinous, and osseous structures of the sternoclavicular joint have not been widely investigated. The purpose of this study was to provide a quantitative description of the sternoclavicular joint in relation to relevant surgical landmarks.

Methods: We dissected eleven nonpaired, fresh-frozen cadaveric sternoclavicular joints from four men and seven women (mean age at death, fifty-three years; range, thirty-three to sixty-four years) and measured the ligaments, musculature, and osseous landmarks with use of a three-dimensional coordinate-measuring device.

Results: The clavicular pectoralis ridge, located at the 9:30 clock-face position on a right clavicle, served as a reliable osseous landmark for reference to the soft-tissue attachments around the sternoclavicular joint. The costoclavicular ligament was the largest ligament of the sternoclavicular joint, with 80% greater footprint area than that of the posterior sternoclavicular ligament. Articular cartilage covered 67% of the medial end of the clavicle and was located anteroinferiorly. The sternohyoid muscle inserted directly over the posterior sternoclavicular joint and the medial end of the clavicle, whereas the sternothyroid muscle inserted 9.5 mm inferior to the posterior-superior articular margin of the manubrium and coursed 19.8 mm laterally along the first rib. An avascular plane that can serve as a “safe zone” for posterior dissection was observed in each specimen, posterior to the sternoclavicular joint and anterior to the sternohyoid and sternothyroid muscles.

Conclusions: The clavicular pectoralis ridge can be used as an intraoperative guide for clavicle orientation and tunnel placement in sternoclavicular ligament reconstruction. Sternoclavicular joint resection arthroplasty should avoid injuring the costoclavicular ligament, which is the largest sternoclavicular joint ligament. Resection of only the anteroinferior aspect of the medial end of the clavicle may provide adequate decompression while preserving the stability of the clavicle. The location of the sternohyoid and sternothyroid musculotendinous insertions appear to provide a “safe zone” for posterior clavicle and manubrial dissection.

Peer Review: This article was reviewed by the Editor-in-Chief and one Deputy Editor, and it underwent blinded review by two or more outside experts. The Deputy Editor reviewed each revision of the article, and it underwent a final review by the Editor-in-Chief prior to publication. Final corrections and clarifications occurred during one or more exchanges between the author(s) and copyeditors.

Disability following injury to the sternoclavicular joint can range from pain, deformity, and discomfort to devastating neurovascular complications¹⁻⁸. Sternoclavicular pathology can be inflammatory or degenerative but is typically due to a direct blow or indirect force transmitted from the shoulder^{9,10}. The injury pattern is predominantly either an anterior or posterior dislocation with some degree of associated ligamentous, disc, or cartilage damage^{11,12}.

The ligamentous structures that stabilize the sternoclavicular joint are the posterior sternoclavicular ligament, the anterior

sternoclavicular ligament, the costoclavicular ligament, the interclavicular ligament, and the intra-articular discoligamentous complex¹²⁻¹⁴. Several authors have proposed that the costoclavicular ligament is the predominant stabilizer of the sternoclavicular joint^{10,15-17}. However, other biomechanical data suggest that the posterior sternoclavicular ligament is the primary stabilizer¹³.

Although some anterior sternoclavicular joint dislocations can be treated nonoperatively, reduction and stabilization of posterior sternoclavicular joint injuries is necessary as they can cause catastrophic injury to the underlying mediastinal

Disclosure: None of the authors received payments or services, either directly or indirectly (i.e., via his or her institution), from a third party in support of any aspect of this work. One or more of the authors, or his or her institution, has had a financial relationship, in the thirty-six months prior to submission of this work, with an entity in the biomedical arena that could be perceived to influence or have the potential to influence what is written in this work. No author has had any other relationships, or has engaged in any other activities, that could be perceived to influence or have the potential to influence what is written in this work. The complete **Disclosures of Potential Conflicts of Interest** submitted by authors are always provided with the online version of the article.

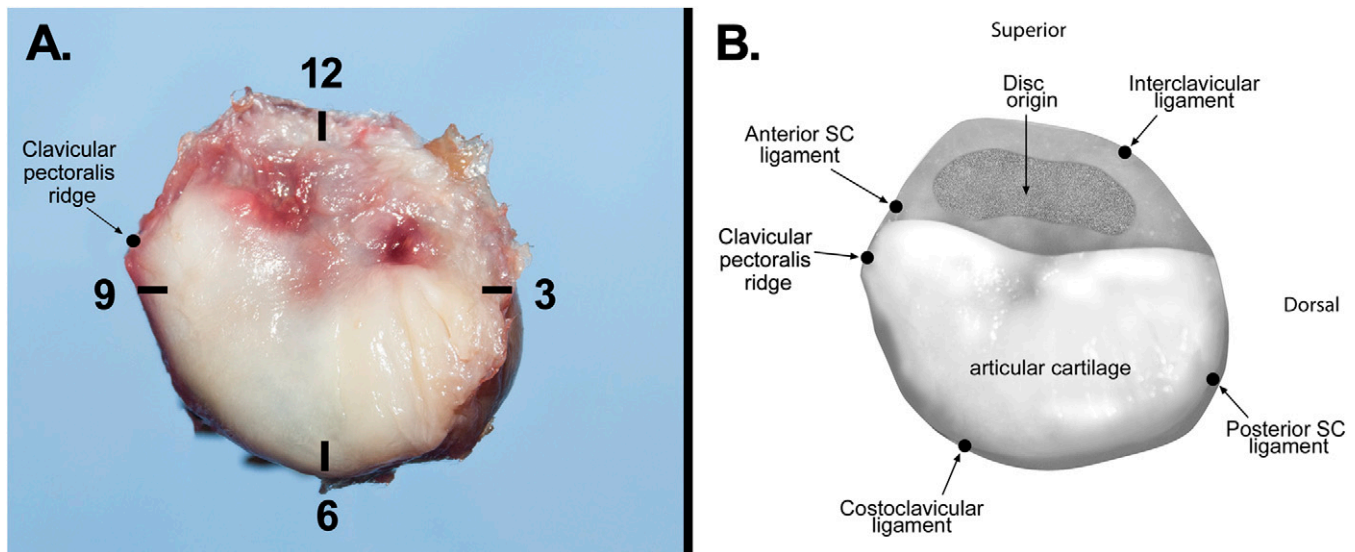


Fig. 1

Fig. 1-A Lateral view of the sternoclavicular (SC) joint at the medial end of a right clavicle with clock-face positions indicated. The most anatomically superior point is 12 o'clock, and 9 o'clock faces anteriorly. The arrow indicates the clavicular pectoralis ridge, positioned at 9:30. **Fig. 1-B** Anatomical illustration of the medial end of the clavicle, showing the extent of the articular surface and the attachment locations of the sternoclavicular, interclavicular, and costoclavicular ligaments. Note the limited articular cartilage coverage and the large attachment area of the intra-articular disc.

structures¹⁸. Surgical reconstruction requires posterior dissection of the clavicle and a blind posterior dissection of the manubrium¹⁹⁻²¹. The mediastinal vasculature is, on average, 6.6 mm deep from the posterior aspect of the sternoclavicular joint²². Just anterior to the mediastinal vessels reside the strap muscles, and these muscles could provide some protection during posterior sternoclavicular joint dissection. Other muscles inserting around the sternoclavicular joint include the pectoralis major, sternocleidomastoid, and subclavius muscles. The anatomical locations of the muscle insertions at the medial end of the clavicle and at the manubrium are not well defined.

Currently, a paucity of information exists regarding the quantitative anatomy of the sternoclavicular joint²³. The purpose of this study was to define the sternoclavicular joint anatomy, to quantify the ligament and muscle-tendon insertions surrounding the sternoclavicular joint, and to define pertinent osseous landmarks, which can serve as reproducible anatomical landmarks during sternoclavicular joint surgery.

Materials and Methods

Dissections were performed on eleven nonpaired, fresh-frozen cadaveric sternoclavicular joints from four men and seven women with no history of clavicle, sternoclavicular joint, or manubrial surgery (mean age at death, fifty-three years; range, thirty-three to sixty-four years). Radiographs of all specimens were made to ensure absence of osteoarthritis and osseous abnormalities. Specimens were randomly allocated; six right and five left sternoclavicular joints were dissected.

Specimen Preparation

After removal of skin and subcutaneous fat from the forequarter specimen, the clavicular origin of the pectoralis major muscle was marked and then the muscle was removed. Meticulous dissection of the subclavius, sternocleidomastoid, sternohyoid, and sternothyroid muscle insertions was performed. Additionally, the anterior sternoclavicular, interclavicular, posterior sterno-

clavicular, and costoclavicular ligaments were isolated and tagged with 2-0 silk suture.

The sternum was potted in a polymethyl methacrylate cylinder, and the specimens were secured in a custom fixture, which rigidly stabilized the manubrium, clavicle, and first rib. The clavicle was secured in relationship to the manubrium and first rib in neutral rotation and elevation. Two coordinate frames were secured to the anterior aspect of the manubrium and the superior aspect of the clavicle, respectively (see Appendix). For each specimen, a coordinate-measuring device (MicroScribe MX, GoMeasure3D, Amherst, Virginia) was used to collect three-dimensional positional data. The sternoclavicular coordinate system used in this study was modeled on previously published recommendations for a thoracic coordinate system²⁴. The coordinate system was defined using three points on the superior aspect of the manubrium: the most anteromedial, anterolateral, and posterolateral points. The anterior axis was aligned with the anterolateral and posterolateral points, with the superior axis orthogonal to it, in line with anteromedial and anterolateral points, and with the lateral axis orthogonal to the others. A clock-face coordinate system was generated for the clavicle with use of circumferential data points 2 cm from the joint line, with 12 o'clock defined as the most superior point (Fig. 1).

Anatomical Measurements

Three manubrial landmarks were used as reference points for data calculation and included the superior aspect of the anterior and posterior manubrial articular cartilage and the inferior aspect of the manubrial articular cartilage. Additionally, two clavicular landmarks were used for calculations: the most inferomedial aspect of the articular surface of the clavicle and a clavicular pectoralis ridge, which is described later (Figs. 2 and 3).

Muscular, tendinous, and ligamentous insertions of interest were outlined in India ink and finely removed, allowing for precise measurement. The India ink outlines were traced with the coordinate-measuring device. We calculated footprint (region-of-attachment) area and center, orientation, and distance from surgically relevant osseous landmarks. Footprint area was calculated using the Heron formula centered on the anatomical average of all border points acquired²⁵⁻²⁷. Ninety-five percent confidence intervals (95% CIs) for each measurement were calculated using a t-distribution, given a sample size of <30. One investigator (K.J.C.) performed all measurements to avoid interobserver variability.

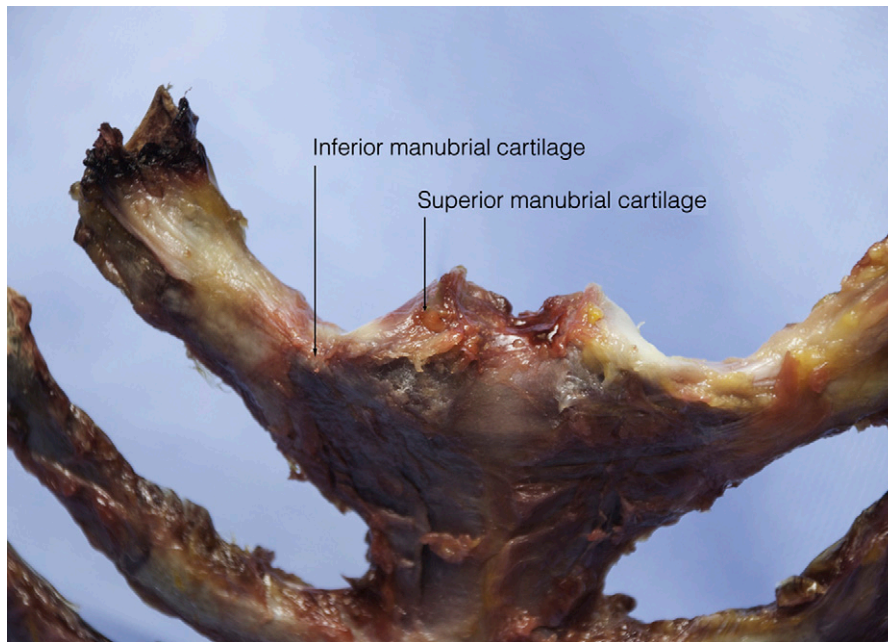


Fig. 2
Anterior view of the right sternoclavicular joint with clavicles removed.

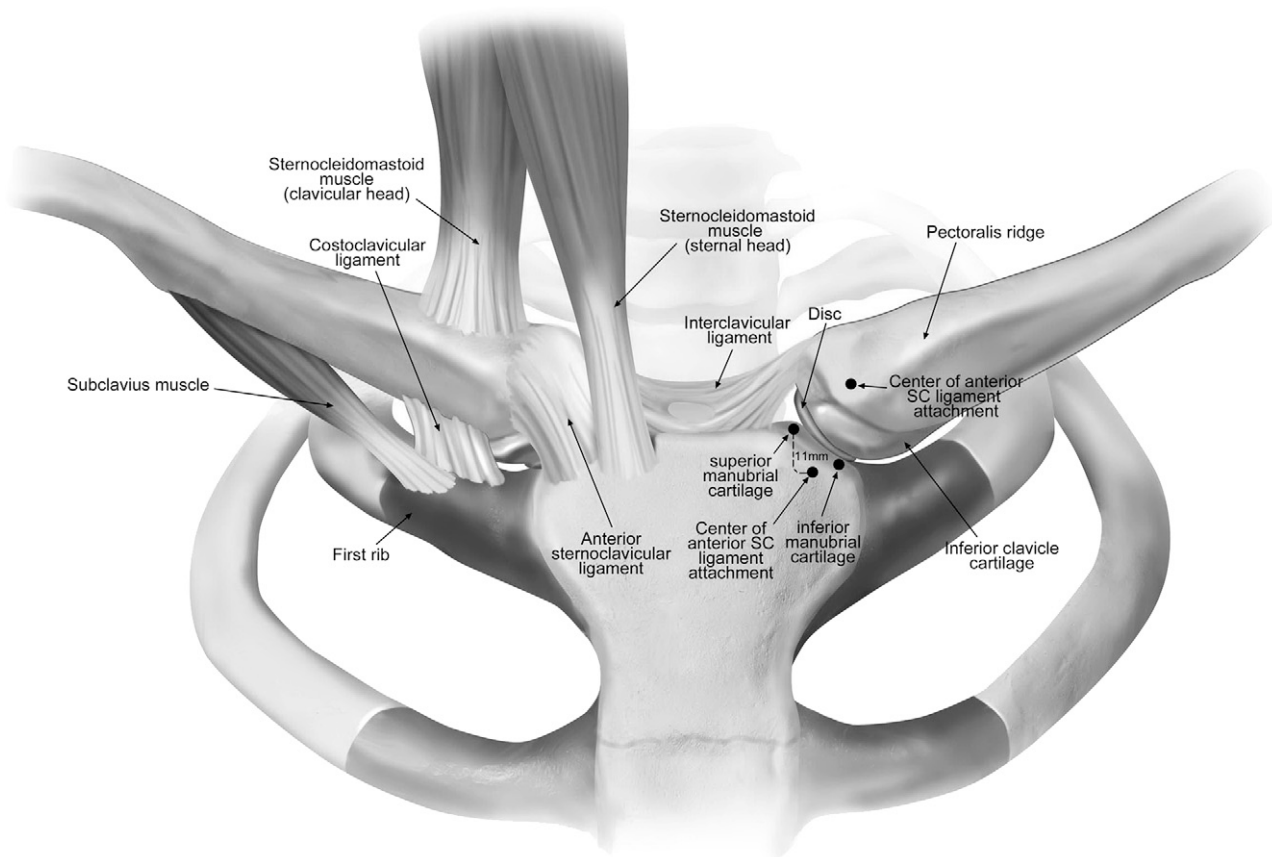


Fig. 3
Anatomical illustration of both sternoclavicular (SC) joints (anterior view). Muscle attachments are excluded from the left sternoclavicular joint to illustrate intra-articular structures. Cartilage is depicted as darker than the surrounding osseous structures.

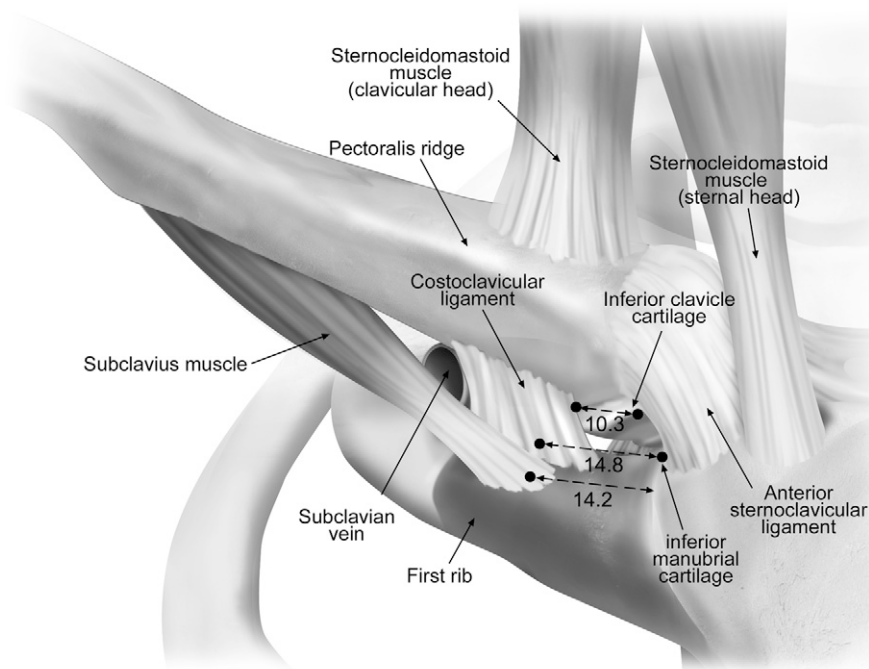


Fig. 4

Anatomical illustration of a right sternoclavicular joint (anterior view). Quantitative measurements (in mm) are given for the distance between the inferior clavicular cartilage and the most medial fibers of the costoclavicular ligament (the most cephalad line) and (the two inferior lines) the distance between the center of attachment of the costoclavicular ligament and of the subclavius tendon on the first-rib cartilage and the inferior manubrial cartilage. The subclavian vein is found posterior and lateral to the lateral edge of the costoclavicular ligament.

System Validation

To assess the accuracy of the coordinate-measuring device in our testing facility, a single point articulation test (SPAT) based on the B89.4.22 ASME standard and the manufacturer's recommendations was performed. The average SPAT result was 0.113 mm.

Statistical Methods

Data were assessed for symmetry and normality, and no evidence was found for deviations from normality. Continuous variables were reported as the mean and parametric 95% CI.

Source of Funding

No external source of funding was received.

Results

The targeted anatomical structures were identified in all eleven specimens. The calculated measurements for each ligamentous, tendinous, or osseous structure are reported in Tables I and II. For point of insertion and location of osseous landmarks, a clock face correlating with an on-end sagittal view of the medial end of a right clavicle was used for quantitative purposes (Fig. 1 and Table I).

Osseous Landmarks

Clavicular Pectoralis Ridge

A longitudinal ridge along the anterior border of the medial end of the clavicle was identified at the thin, tendinous origin of the clavicular head of the pectoralis major muscle. There-

fore, this osseous landmark was defined as the *clavicular pectoralis ridge* (Figs. 3 and 4). The pectoralis major muscle belly filled a fossa inferior to the ridge. On a right clavicle, the clavicular pectoralis ridge was located at the 9:30 clock-face position. It was raised slightly from the surrounding bone and ran the length of the origin of the pectoralis major on the clavicle.

Costoclavicular Tubercle

The insertion of the costoclavicular ligament on the medial end of the clavicle was located on the inferior edge of the clavicle, with a definable and palpable tubercle in all specimens located at the 7 o'clock position. As this tubercle is on the inferior aspect of the clavicle and is covered by the stout costoclavicular ligament, it was only palpable after dislocation of the sternoclavicular joint.

Intra-Articular Disc and Articular Cartilage

The medial end the clavicle was covered with the closely associated intra-articular disc. The disc was complete in ten of eleven specimens but had a tear in one specimen. The disc had a robust insertion on the posterosuperior aspect of the clavicle with peripheral attachments to the anterior and posterior sternoclavicular ligaments (Fig. 1). Inferiorly, the disc had a less robust attachment. The disc measured an average of 18 mm (95% CI, 14.9 to 21.1 mm) in diameter and was 5.4 mm (95% CI, 4.3 to 6.4 mm) thick and tapered centrally with

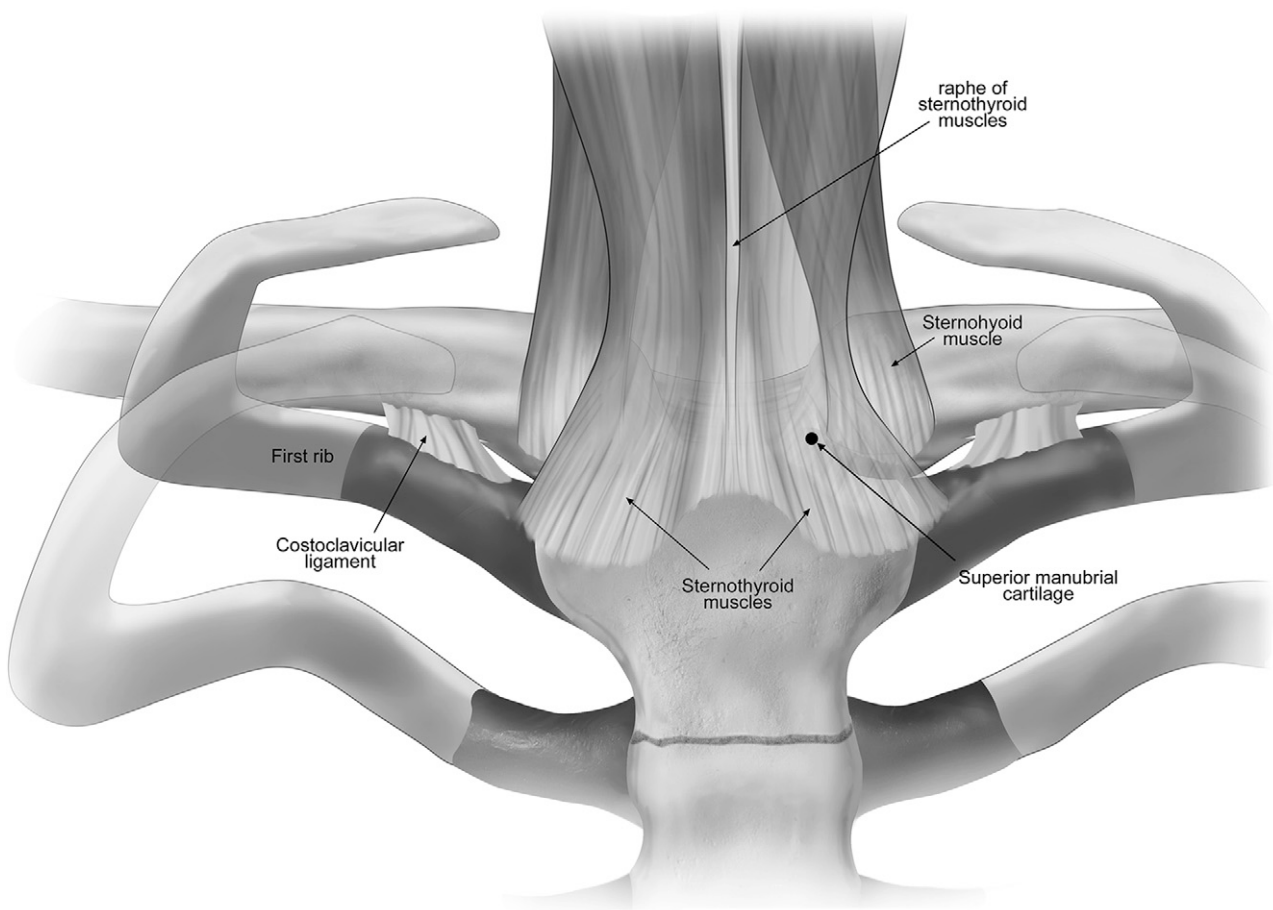


Fig. 5
Anatomical illustration of the sternoclavicular joints (posterior view), showing the topography of the muscles in relation to the joint. The sternothroid muscle is presented as translucent in order to illustrate the sternoclavicular joint and the sternohyoid muscle on the right side. Cartilage is depicted as darker than the surrounding osseous structures.

concavity appreciated on both the clavicular and manubrial sides.

Articular cartilage covered 67% (95% CI, 59.4% to 75.0%) of the medial end of the clavicle, with coverage only on the anteroinferior aspect of the clavicle and including the inferior portion and underside of the clavicle at its articulation with the manubrial and first-rib costal cartilage. The antero-superior margin of the cartilage began near the clavicular pectoralis ridge (Fig. 1).

Tendon Insertions

Sternohyoid

The sternohyoid muscle was identified as a thin strap muscle with insertion onto the posterior aspect of the sternoclavicular joint capsule and the clavicle. The majority of the sternohyoid insertion was on the clavicle (Fig. 5), with a long, thin insertion extending medial to lateral (Table II). At its most medial edge, the tendon insertion was 4.6 mm (95% CI, 1.0 to 8.2 mm) lateral to and 1.1 mm (95% CI, -1.7 to 3.9 mm) inferior to the posterior-superior manubrial articular cartilage. The lateral edge of the insertion was 19.5 mm (95% CI, 12.3 to 26.7 mm)

lateral and 5.2 mm (95% CI, 1.3 to 9.1 mm) inferior to the superior manubrial articular cartilage.

Sternothroid

The sternothroid was identified as the deeper of the two strap muscles, with a more inferior insertion on the posterior aspect of the sternum and costal cartilage. It also had a long, thin insertion running from medial to lateral. The medial edge of the insertion was 0.3 mm (95% CI, -2.4 to 3.1 mm) medial to and 9.5 mm (95% CI, 5.5 to 13.6 mm) inferior to the posterior-superior manubrial cartilage, while the lateral edge of the insertion was 19.8 mm (95% CI, 12.4 to 27.1 mm) lateral to and 5.4 mm (95% CI, 0.7 to 10.3 mm) inferior to the superior manubrial cartilage and was on the posterior first-rib costal cartilage.

We found a fascial attachment between the right and left muscle bellies of the sternohyoid and sternothroid muscles with a midline raphe that inserted onto the posterior aspect of the manubrium. Anterior to this fascial layer and the muscle bellies was a potential “safe zone” with no vascular structures (Fig. 6).

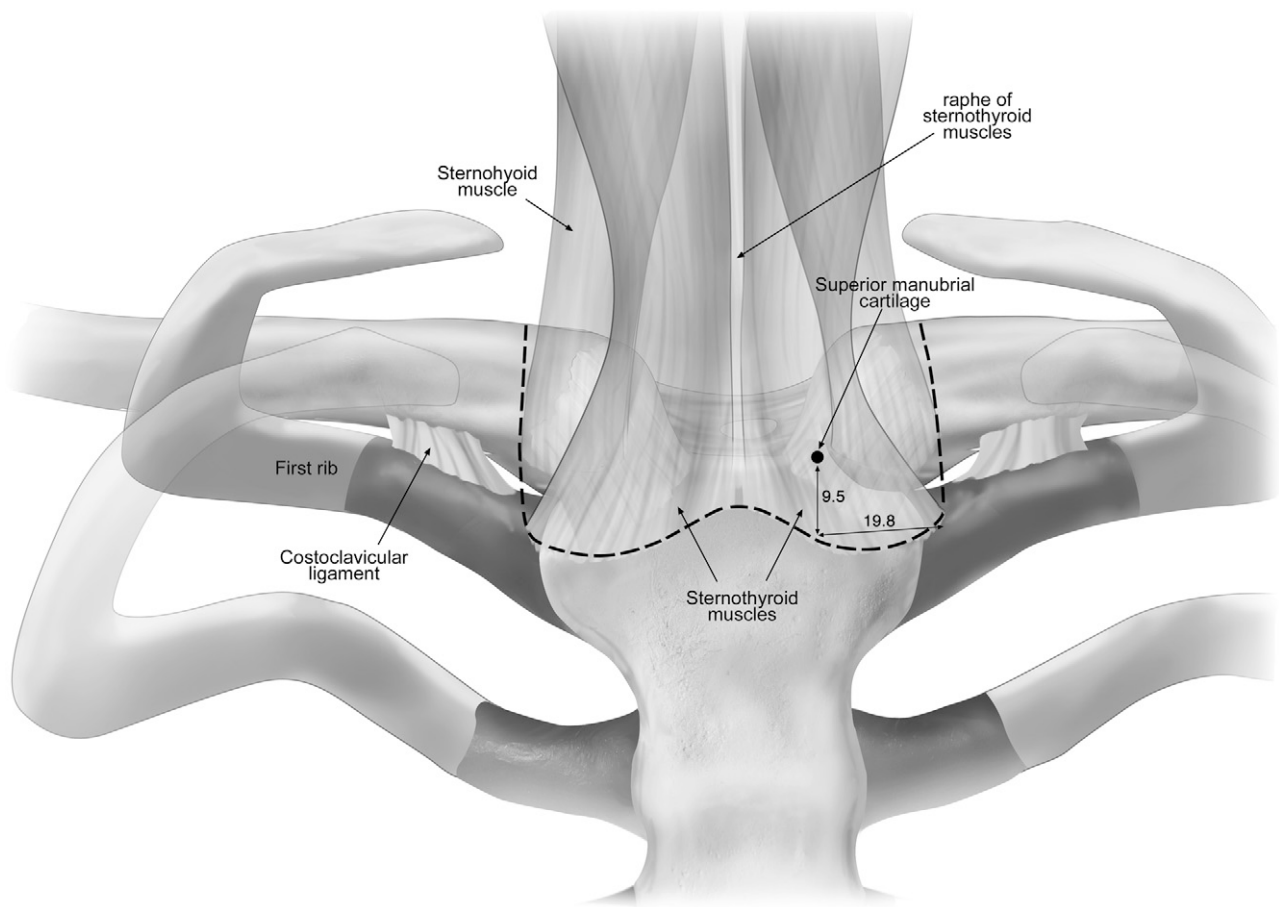


Fig. 6

The borders of the “safe zone” for posterior manubrial and clavicle dissection are outlined (dashed lines). This zone represents an avascular plane that is anterior to the mediastinum and superficial to the muscle bellies of the sternothyroid and sternohyoid muscles. Quantitative measurements (see Table II) are given in millimeters.

Sternocleidomastoid

The manubrial insertion of the sternocleidomastoid was found to have a round tendon with a footprint area of 83.2 mm² (95% CI, 67.5 to 98.9 mm²). The tendon was 7.7 mm (95% CI, 4.7 to 10.7 mm) inferior to the superior ipsilateral manubrial cartilage. The manubrial head of the sternocleidomastoid was 10.2 mm (7.0 to 13.3 mm) medial to the closest manubrial cartilage. As the tendon coursed superiorly, it crossed over the superior half of the sternoclavicular joint (Figs. 3 and 4).

The clavicular head of the sternocleidomastoid inserted on the superior surface of the clavicle, with a broad linear insertion. The insertion footprint area was 199.5 mm² (95% CI, 150.3 to 248.7 mm²), and the most medial extent of the tendon was 9.9 mm (95% CI, 2.9 to 17.0 mm) lateral to the superior articular margin of the clavicle.

Subclavius

The subclavius muscle belly had a long origin with the most medial edge starting 20 mm (95% CI, 13.2 to 26.9 mm) lateral to the inferior cartilage of the clavicle. The tendon coursed obliquely

to insert on the lateral aspect of the first-rib costal cartilage (Fig. 4, Table II).

Ligaments

Costoclavicular Ligament

The costoclavicular ligament was found to be a short, robust ligament between the first-rib costal cartilage and the costoclavicular tubercle on the medial end of the clavicle. From its origin on the first rib, it coursed from medial to lateral to insert on the inferior aspect of the clavicle. On the clavicle, the center of the costoclavicular ligament was 13.8 mm (95% CI, 9.8 to 17.7 mm) lateral to the inferior sternoclavicular articular margin and the most medial fibers were 10.3 mm (95% CI, 5.6 to 15.1 mm) lateral to the same point of reference (Fig. 4). On the first-rib cartilage, the most medial fibers of the costoclavicular ligament were 8.3 mm (95% CI, 5.9 to 10.6 mm) lateral to the inferior manubrial articular cartilage margin, and the center of the insertion was 14.8 mm (95% CI, 12.6 to 17.0 mm) lateral to the same point.

The costoclavicular ligament had the largest footprint of the sternoclavicular joint-associated ligaments (Table I). The

TABLE I Quantitative Characteristics of the Sternoclavicular Ligaments*

Structure	Manubrial Footprint (mm^2)	First-Rib Footprint (mm^2)	Clavicle Footprint (mm^2)	Origin (mm)	Insertion
Anterior sternoclavicular ligament	85.3 (64.0-106.5)		64.7 (50.9-78.5)	11.2 inferior to SMC (7.8-14.6), 3.4 medial to manubrial cartilage (1.5-5.3)	10:00 position (9:30-11:30)
Posterior sternoclavicular ligament	102.7 (79.0-126.4)		90.9 (70.3-114.4)	5.4 inferior to SMC (3.6-7.1)	4:30 position (3:30-5:30)
Costoclavicular ligament		160.8 (136.0-185.6)	182.8 (113.8-251.7)	Medial edge 8.3 lateral to IMC on superior first rib (5.9-10.6)	7:00 position (6:00-8:00) 10.3 mm lateral to inferior SCJC (5.6-15.1)
Interclavicular ligament†			37.5 (30.4-44.6)		1:30 position (1:00-2:30)
Clavicular pectoralis ridge					9:30 position (9:00-10:30)

*Values are given as the mean with the 95% confidence interval in parentheses. Distances are given to the center of the ligament except for that of the costoclavicular ligament, which represents the distance to the most medial edge. Clock-face position relates to viewing the articular surface of the right clavicle from medial to lateral. SMC = superior manubrial cartilage, IMC = inferior manubrial cartilage, and SCJC = sternoclavicular joint cartilage. †The interclavicular ligament has no direct insertion on the manubrium but bridges from clavicle to clavicle.

origin on the clavicle had a footprint area of 182.8 mm^2 (95% CI, 113.8 to 251.7 mm^2), and the footprint on the first-rib costal cartilage was 160.8 mm^2 (95% CI, 136.0 to 185.6 mm^2).

Posterior Sternoclavicular Ligament

The posterior sternoclavicular ligament appeared as a diffuse thickening of the posterior joint capsule with no discrete ligament identified. The broad manubrial attachment had an origin centered 5.4 mm (95% CI, 3.6 to 7.1 mm) inferior to the posterior-superior manubrial articular cartilage. However, the entire origin extended proximally and distally from this point

(Fig. 5). The insertion on the clavicle was also broad with the center of insertion located at the 4:30 clock-face position (Fig. 5 and Table I).

Anterior Sternoclavicular Ligament

The anterior sternoclavicular ligament was identified as an oblique capsular thickening running from inferomedial to superolateral across the anterior surface of the sternoclavicular joint. Dissection of the ligament and anterior capsule revealed it to be the anterior attachment of the intra-articular disc. The manubrial origin was 11.2 mm (95% CI, 7.8 to 14.6 mm)

TABLE II Quantitative Characteristics of Muscular Tissues Around the Sternoclavicular Joint*

Structure	Reference Point	Tendon Insertions (mm)	Footprint Area (mm^2)
Sternothyroid	Medial edge	9.5 inferior to SMC (5.5-13.6), 0.3 medial to SMC (-2.4-3.1)	279.7 (184.5-374.9)
	Lateral edge	5.4 inferior to SMC (0.7-10.3), 19.8 lateral to SMC (12.4-27.1)	
Sternohyoid	Medial edge	1.1 inferior to SMC (-1.7-3.9), 4.6 lateral to SMC (1.0-8.2)	234.5 (179.5-289.5)
	Lateral edge	5.2 inferior to SMC (1.3-9.1), 19.5 lateral to SMC (12.3-26.7)	
Sternocleidomastoid	Manubrial insertion	7.7 inferior to SMC (4.7-10.7), 10.2 medial to manubrial cartilage (7.0-13.3)	83.2 (67.5-98.9)
Subclavius	First-rib insertion	14.2 lateral to IMC (10.4-18.0)	60.3 (46.4-74.3)

*Muscle tendon locations, in relationship to osseous intraoperative landmarks of the sternoclavicular joint, as well as footprint areas are presented. Values are given as the mean with the 95% confidence interval in parentheses. SMC = superior manubrial cartilage, and IMC = inferior manubrial cartilage.

inferior to the anterior-superior manubrial articular margin and 3.4 mm (95% CI, 1.5 to 5.3 mm) medial to the articular cartilage, and just inferior and lateral to the sternocleidomastoid tendon insertion. On a right clavicle, the attachment was located at the 10 o'clock position (Figs. 1 and 3).

Interclavicular Ligament

The interclavicular ligament was found in all specimens and was the most readily identified of the sternoclavicular-associated joint ligaments as a discrete ligament between the two clavicle heads. The interclavicular ligament attachment was located at the 1:30 position (Fig. 1 and Table I).

Discussion

The most important findings of this study were the identification of osseous landmarks, including the clavicular pectoralis ridge, which was located at the 9:30 position on a right clavicle; the quantification of the costoclavicular ligament as the largest ligament of the sternoclavicular joint; the characterization of the articular surface of the medial end of the clavicle; and further characterization of the sternothyroid and sternohyoid muscle insertions located immediately posterior and inferior to the sternoclavicular joint, providing a definable layer between the posterior aspect of the sternoclavicular joint and the mediastinal structures.

The clavicular pectoralis ridge was identified on the anterior surface of the clavicle in all specimens. We named this structure the *clavicular pectoralis ridge* because it is the clavicular attachment site for the pectoralis major muscle. With its position noted in terms of a clock-face measurement, this landmark can serve as a reference for all other pertinent structures. We believe a clock-face orientation of the medial end of the clavicle is the most reproducible method for determining structure location, as large variations in clavicular size have been observed between individuals and even from side to side within the same individual^{23,28}.

With sternoclavicular joint instability or dislocation, typically all ligamentous structures have been torn, and there is no restraint to medial clavicle rotation or translation. Additionally, during surgical reconstruction of the anterior and posterior sternoclavicular ligaments, a complete release of the soft-tissue envelope surrounding the medial end of the clavicle is required for exposure^{19,20}. In these cases, the clavicular pectoralis ridge can be helpful in determining the anatomical orientation of the clavicle to prevent iatrogenic malrotation.

Sternoclavicular joint stability is predominantly attributed to the costoclavicular ligament, the posterior sternoclavicular ligament, and the anterior sternoclavicular ligament. Whether a resection arthroplasty or ligament reconstruction is performed, sternoclavicular joint stability must be maintained. Many authors have described the costoclavicular ligament as the predominant stabilizer of the sternoclavicular joint in all planes of motion except lateral clavicle depression^{14,16,17,29}. Supporting these assertions, we found the costoclavicular ligament to be the largest ligament associated with the sternoclavicular joint. However, Spencer et al. found the anterior and posterior sternoclavicular ligaments to be the primary stabilizers to anterior

and posterior stability, whereas the costoclavicular ligament provided limited stabilization¹³. Additional studies are needed to determine the biomechanical characteristics of the costoclavicular ligament.

Although the biomechanical importance of the costoclavicular ligament has yet to be defined, clinically, Rockwood et al. have shown that costoclavicular ligament preservation is necessary for good outcomes in cases of resection arthroplasty of the sternoclavicular joint³⁰. Regarding preservation of this ligament, the distance from the inferior surface of the clavicle to the center of insertion of the costoclavicular ligament previously was described, and our findings are consistent with reports of 10 mm to 12.6 mm^{31,32}. Our data support medial clavicle resections of ≤ 10 mm to avoid compromising the integrity of the costoclavicular ligament³¹.

Previous techniques of resection arthroplasty have described complete resection of the medial end of the clavicle. However, we found that the articular cartilage covered only 67% of the medial end of the clavicle, with the coverage located at the most anteroinferior aspect. Limited resection of only the articular cartilage, as opposed to the entire medial end of the clavicle, would have the benefit of maintaining the important costoclavicular and posterior sternoclavicular ligaments and may be of considerable benefit in arthroscopic sternoclavicular joint decompression³³⁻³⁵. Studies regarding the location and extent of medial clavicle resection to gain adequate decompression and maintain stability are needed.

Through our investigation, we were able to characterize the relationship of the sternohyoid and sternothyroid to the posterior aspect of the sternoclavicular joint and identified the presence of an avascular plane for posterior sternoclavicular joint dissection. This avascular "safe zone" was between the posterior aspect of the manubrium and the sternothyroid muscle belly. On average, it extended from the posterior-superior manubrial articular cartilage inferiorly 9.5 mm and extended laterally from that point 19.8 mm along the posterior border of the first rib. This "safe zone" also crossed the midline between the connective-tissue raphe of the two sternothyroid muscle bellies.

The parameters of this "safe zone" for posterior dissection are particularly useful when performing dissection of the posterior aspect of the manubrium. During figure-of-eight sternoclavicular ligament reconstructions, posterior manubrial dissection is required for safe tunnel placement^{19,20,35,36}. Dissection outside of the parameters of the "safe zone" places elevators and retractors within the mediastinum, with increased risk of vascular injury. The strap muscles are relatively thin and at risk for injury, especially with posterior sternoclavicular joint dislocation. In these cases, three-dimensional imaging should be carefully evaluated to ensure these muscles remain intact. With sternothyroid muscle disruption or attenuation, additional precautions should be taken with posterior sternoclavicular joint dissection.

The authors of previous studies have reported qualitative evaluations of the sternoclavicular joint with particular attention to the intra-articular disc and capsular and extra-capsular

joint ligaments in relation to each other^{11,29,30,37}. The current study, in addition to reaffirming and expanding on previous qualitative descriptions, provides quantitative values for footprints of the intra-articular disc, the capsular and extra-capsular ligaments, and the sternohyoid, sternothyroid, and sternocleidomastoid muscles. This study also adds to the work of Ponce et al. regarding the dangers of operating in the region of the sternoclavicular joint by describing an avascular “safe zone” for posterior clavicle and manubrial dissection²².

The strengths of this study include radiographic screening of all specimens, the use of a clock-face method to reference the location of anatomical structures without the bias of size of specimen, and the use of fresh-frozen cadaveric specimens all with an age at death of less than sixty-five years. We acknowledge that there are some limitations. A limited number of specimens were used, which may limit the generalizability of our findings. We did not report data stratified by sex or provide size comparisons of the medial end of the clavicle, which may explain why we found some variability among specimens in terms of the distance of structures from osseous landmarks. Nonetheless, the consistent location in all specimens of the clavicular pectoral ridge as well as the sternohyoid and sternothyroid functioning as a layer separating the posterior aspect of the sternoclavicular joint from the mediastinal vessels debilitate these limitations partially. Finally, we did not quantify the distance or relationship to important neurovascular structures, as other authors have already reported these values²².

This anatomical study quantitatively defined the anatomy of the sternoclavicular joint. We identified a consistent osseous prominence, the clavicular pectoralis ridge, to serve as an intraoperative landmark. The costoclavicular ligament was

identified as the largest of the ligaments associated with the sternoclavicular joint, and we found that only the anteroinferior aspect of the medial end of the clavicle was covered with articular cartilage. We also identified a “safe zone” for posterior dissection, a plane between the posterior aspect of the sternoclavicular joint and the muscle insertions of the sternohyoid and sternothyroid, which can improve safety of surgical treatment of sternoclavicular joint pathology.

Appendix

eA A figure showing the custom rig developed to secure each specimen and an anterior view of a specimen that has been secured is available with the online version of this article as a data supplement at jbjs.org. ■

Note: The authors acknowledge Kyle Jansson for his development of the custom fixture used for rigid fixation of the specimen, Angelica Wedell and Barry Eckhaus for assistance with the illustrations, and Ryan Warth, MD, for manuscript preparation.

Jared T. Lee, MD
Kevin J. Campbell, BS
Max P. Michalski, MSc
Katharine J. Wilson, MSc
Ulrich J.A. Spiegl, MD
Coen A. Wijdicks, PhD
Peter J. Millett, MD, MSc
Steadman Philippon Research Institute,
181 West Meadow Drive,
Suite #1000,
Vail, CO 81657.
E-mail address for P.J. Millett: drmillett@thesteadmanclinic.com

References

- Kennedy JC. Retrosternal dislocation of the clavicle. *J Bone Joint Surg Br.* 1949 Feb;31(1):74.
- Howard FM, Shafer SJ. Injuries to the clavicle with neurovascular complications. A study of fourteen cases. *J Bone Joint Surg Am.* 1965 Oct;47(7):1335-46.
- Wasylenko MJ, Busse EF. Posterior dislocation of the clavicle causing fatal tracheoesophageal fistula. *Can J Surg.* 1981 Nov;24(6):626-7.
- Jain S, Monbaliu D, Thompson JF. Thoracic outlet syndrome caused by chronic retrosternal dislocation of the clavicle. Successful treatment by transaxillary resection of the first rib. *J Bone Joint Surg Br.* 2002 Jan;84(1):116-8.
- O'Connor PA, Nölke L, O'Donnell A, Lingham KM. Retrosternal dislocation of the clavicle associated with a traumatic pneumothorax. *Interact Cardiovasc Thorac Surg.* 2003 Mar;2(1):9-11.
- Marcus MS, Tan V. Cerebrovascular accident in a 19-year-old patient: a case report of posterior sternoclavicular dislocation. *J Shoulder Elbow Surg.* 2011 Oct;20(7):e1-4.
- Worman LW, Leagus C. Intrathoracic injury following retrosternal dislocation of the clavicle. *J Trauma.* 1967 May;7(3):416-23.
- Keating M, Von Ungern-Sternberg BS. Compression of the common carotid artery following clavicle fracture in a twelve-year-old. *Anaesth Intensive Care.* 2010 Jul;38(4):759-60.
- Laffosse JM, Espié A, Bonneville N, Mansat P, Tricoire JL, Bonneville P, Chiron P, Puget J. Posterior dislocation of the sternoclavicular joint and epiphyseal disruption of the medial clavicle with posterior displacement in sports participants. *J Bone Joint Surg Br.* 2010 Jan;92(1):103-9.
- Rockwood CA Jr, Matsen FA III, Wirth MA, Lippitt SB, Harryman DT. The shoulder. 4th ed. Philadelphia: Saunders Elsevier; 2009.
- Wirth MA, Rockwood CA Jr. Acute and Chronic Traumatic Injuries of the Sternoclavicular Joint. *J Am Acad Orthop Surg.* 1996 Oct;4(5):268-78.
- Renfree KJ, Wright TW. Anatomy and biomechanics of the acromioclavicular and sternoclavicular joints. *Clin Sports Med.* 2003 Apr;22(2):219-37.
- Spencer EE, Kuhn JE, Huston LJ, Carpenter JE, Hughes RE. Ligamentous restraints to anterior and posterior translation of the sternoclavicular joint. *J Shoulder Elbow Surg.* 2002 Jan-Feb;11(1):43-7.
- Bearn JG. Direct observations on the function of the capsule of the sternoclavicular joint in clavicular support. *J Anat.* 1967 Jan;101(Pt 1):159-70.
- Groh GI, Wirth MA, Rockwood CA Jr. Treatment of traumatic posterior sternoclavicular dislocations. *J Shoulder Elbow Surg.* 2011 Jan;20(1):107-13. Epub 2010 Jun 26.
- Cave AJ. The nature and morphology of the costoclavicular ligament. *J Anat.* 1961 Apr;95:170-9.
- Tubbs RS, Shah NA, Sullivan BP, Marchase ND, Cömert A, Acar HI, Tekdemir I, Loukas M, Shoja MM. The costoclavicular ligament revisited: a functional and anatomical study. *Rom J Morphol Embryol.* 2009;50(3):475-9.
- Ono K, Inagawa H, Kiyota K, Terada T, Suzuki S, Maekawa K. Posterior dislocation of the sternoclavicular joint with obstruction of the innominate vein: case report. *J Trauma.* 1998 Feb;44(2):381-3.
- Spencer EE Jr, Kuhn JE. Biomechanical analysis of reconstructions for sternoclavicular joint instability. *J Bone Joint Surg Am.* 2004 Jan;86(1):98-105.
- Martetschläger F, Warth RJ, Millett PJ. Instability and degenerative arthritis of the sternoclavicular joint: a current concepts review. *Am J Sports Med.* 2014 Apr;42(4):999-1007. Epub 2013 Aug 16.
- Millett PJ, Martetschläger F, Warth RJ, Horan MP. Tendon graft reconstruction for sternoclavicular joint instability – technique and short-term results. Presented as a poster exhibit at the 30th Annual Congress of the AGA Society for Arthroscopy and Joint Surgery; 2013 Sep 19-21; Wiesbaden, Germany. Poster no P10-1200.
- Ponce BA, Kundukulam JA, Pflugner R, McGwin G, Meyer R, Carroll W, Minnich DJ, Larrison MC. Sternoclavicular joint surgery: how far does danger lurk below? *J Shoulder Elbow Surg.* 2013 Jul;22(7):993-9. Epub 2013 Jan 16.
- Wijeratna MD, Turmezei TD, Tytherleigh-Strong G. Novel assessment of the sternoclavicular joint with computed tomography for planning interventional approach. *Skeletal Radiol.* 2013 Apr;42(4):473-8. Epub 2012 Aug 30.

- 24.** Wu G, van der Helm FC, Veeger HE, Makhsous M, Van Roy P, Anglin C, Nagels J, Karduna AR, McQuade K, Wang X, Werner FW, Buchholz B; International Society of Biomechanics. ISB recommendation on definitions of joint coordinate systems of various joints for the reporting of human joint motion—Part II: shoulder, elbow, wrist and hand. *J Biomech*. 2005 May;38(5):981-92.
- 25.** Nelsen R. Heron's formula via proof's without words. *Coll Math J*. 2001;32(4):290-2.
- 26.** Johannsen AM, Civitarese DM, Padalecki JR, Goldsmith MT, Wijdicks CA, LaPrade RF. Qualitative and quantitative anatomic analysis of the posterior root attachments of the medial and lateral menisci. *Am J Sports Med*. 2012 Oct;40(10):2342-7. Epub 2012 Sep 7.
- 27.** Campbell KJ, Michalski MP, Wilson KJ, Goldsmith MT, Wijdicks CA, LaPrade RF, Clanton TO. The Ligament Anatomy of the Deltoid Complex of the Ankle: A Qualitative and Quantitative Anatomical Study. *J Bone Joint Surg Am*. 2014 Apr;96(8):654.
- 28.** Tuscano D, Banerjee S, Terk MR. Variations in normal sternoclavicular joints; a retrospective study to quantify SCJ asymmetry. *Skeletal Radiol*. 2009 Oct;38(10):997-1001. Epub 2009 Mar 24.
- 29.** Depalma AF. Surgical anatomy of acromioclavicular and sternoclavicular joints. *Surg Clin North Am*. 1963 Dec;43:1541-50.
- 30.** Rockwood CA Jr, Groh GI, Wirth MA, Grassi FA. Resection arthroplasty of the sternoclavicular joint. *J Bone Joint Surg Am*. 1997 Mar;79(3):387-93.
- 31.** Bisson LJ, Dauphin N, Marzo JM. A safe zone for resection of the medial end of the clavicle. *J Shoulder Elbow Surg*. 2003 Nov-Dec;12(6):592-4.
- 32.** Carrera EF, Archetti Neto N, Carvalho RL, Souza MA, Santos JB, Faloppa F. Resection of the medial end of the clavicle: an anatomic study. *J Shoulder Elbow Surg*. 2007 Jan-Feb;16(1):112-4. Epub 2006 Oct 19.
- 33.** Tavakkolizadeh A, Hales PF, Janes GC. Arthroscopic excision of sternoclavicular joint. *Knee Surg Sports Traumatol Arthrosc*. 2009 Apr;17(4):405-8. Epub 2008 Dec 17.
- 34.** Tytherleigh-Strong G. Arthroscopy of the sternoclavicular joint. *Arthrosc Tech*. 2013 May;2(2):e141-5. Epub 2013 Apr 18.
- 35.** Warth RJ, Lee JT, Campbell KJ, Millett PJ. Bilateral Arthroscopic Sternoclavicular Joint Resections: A Case Report. *Arthroscopy*. 2014 [In press].
- 36.** Lee JT, Nasreddine AY, Black EM, Bae DS, Kocher MS. Posterior Sternoclavicular Joint Injuries in Skeletally Immature Patients. *J Pediatr Orthop*. 2013 Oct 29. Epub 2013 Oct 29.
- 37.** van Tongel A, MacDonald P, Leiter J, Pouliart N, Peeler J. A cadaveric study of the structural anatomy of the sternoclavicular joint. *Clin Anat*. 2012 Oct;25(7):903-10. Epub 2012 Jan 3.