



# Arthroscopic Acromioclavicular Joint Treatment With Coracoclavicular Fixation and Allograft Coracoclavicular Ligament Reconstruction for Acute Acromioclavicular Dislocations

Joseph J. Ruzbarsky, M.D., Philip-C. Nolte, M.D., M.A., Justin W. Arner, M.D., Bryant P. Elrick, M.Sc., Anna-K. Tross, M.D., and Peter J. Millett, M.D., M.Sc.

**Abstract:** Treatment of severe acromioclavicular joint injuries remains controversial and has evolved over the past 4-plus decades. Although several variations on reconstruction exist, an ideal technique will likely use a combination of coracoclavicular ligament reconstruction with suture backup stabilization, minimal drill holes to reduce the risk of fracture, arthroscopic-assisted guidance for anatomic graft and suture placement in and around the coracoid, and fluoroscopic-aided reduction to ensure an anatomic acromioclavicular joint. The objective of this Technical Note is to describe an arthroscopic-assisted coracoclavicular ligament reconstruction with allograft using fluoroscopically guided and cerclage-controlled anatomic reduction of the acromioclavicular joint.

The appropriate treatment of acromioclavicular joint (ACJ) injuries is still debated. Although most surgeons would agree that Rockwood classification types IV through VI should be treated surgically and types I and II should be treated conservatively, type III injuries, with 25% to 100% increased coracoclavicular displacement compared with the uninjured side, remain controversial because some comparative studies have shown no difference in outcomes between surgically and non-operatively treated injuries.<sup>1</sup> Furthermore, even when the decision is made that surgical management is appropriate, the methods for stabilization and reconstruction are numerous. No technique has been agreed on, with greater than 150 techniques described.<sup>1</sup> Other controversies include the definition of an acute versus chronic

sprain and how each should be managed, open versus arthroscopic-assisted approaches, bone tunnels in the coracoid versus looped grafts or sutures, allograft versus autograft, and whether to extend the reconstruction to the ACJ. The purpose of this Technical Note is not to answer all of these questions or to resolve each controversy but rather to present the preferred technique of the senior author (P.J.M.) for the treatment of acute acromioclavicular (AC) dislocations using modern equipment and devices that allow for a safe and reproducible reconstruction with empirically excellent early results.

## Surgical Technique

**Video 1** presents a narrated video showing the described surgical technique.

From The Steadman Clinic, Vail, Colorado, U.S.A. (J.J.R., J.W.A., P.J.M.); and Steadman Philippon Research Institute, Vail, Colorado, U.S.A. (J.J.R., P-C.N., J.W.A., B.P.E., A-K.T., P.J.M.).

The authors report the following potential conflicts of interest or sources of funding: P-C.N. receives fellowship support from Arthrex, outside the submitted work. B.P.E. receives personal fees from Steadman Philippon Research Institute (SPRI) and is a current paid employee at SPRI, outside the submitted work. SPRI exercises special care to identify any financial interests or relationships related to research conducted here. During the past calendar year, SPRI has received grant funding or in-kind donations from Arthrex, Department of Defense Office of Naval Research, DJO, MLB, Ossur, Siemens, Smith & Nephew, and XTRE. P.J.M. is a consultant for Arthrex, Medibridge, and Springer Publishing; receives royalties from Arthrex, Medibridge, and Springer Publishing; receives grant support from Arthrex; receives stock from

VuMedi; and reports that his institution receives funding from Smith & Nephew, Siemens, and Ossur, outside the submitted work. Full ICMJE author disclosure forms are available for this article online, as [supplementary material](#).

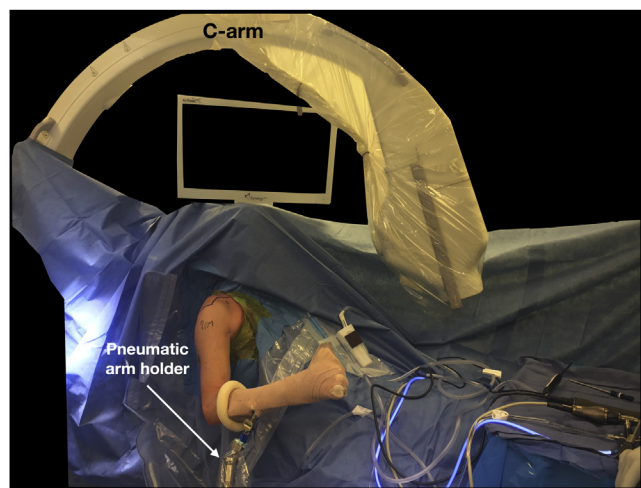
Received March 6, 2020; accepted April 29, 2020.

Address correspondence to Peter J. Millett, M.D., M.Sc., Steadman Philippon Research Institute, The Steadman Clinic, 181 W Meadow Dr, Ste 400, Vail, CO 81657, U.S.A. E-mail: [drmillett@thesteadmanclinic.com](mailto:drmillett@thesteadmanclinic.com)

© 2020 by the Arthroscopy Association of North America. Published by Elsevier. This is an open access article under the CC BY-NC-ND license (<http://creativecommons.org/licenses/by-nc-nd/4.0/>).

2212-6287/20359

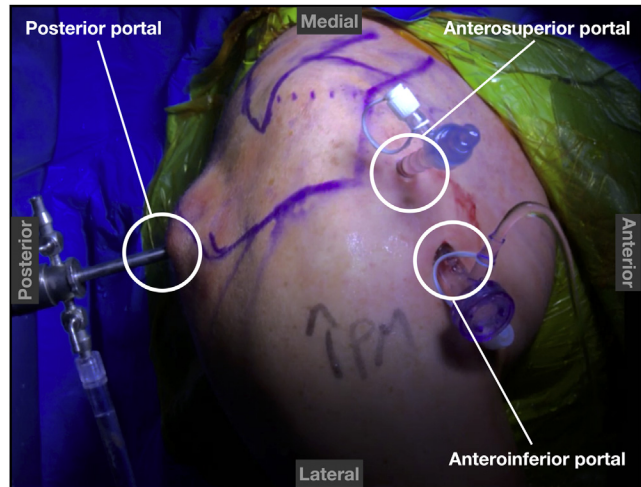
<https://doi.org/10.1016/j.eats.2020.04.025>



**Fig 1.** Patient in the beach-chair position for arthroscopic-assisted anatomic coracoclavicular joint reconstruction. The placement of the large fluoroscopy machine should be noted.

**Patient Positioning and Anesthesia**

Prior to transfer to the operating room, an indwelling interscalene catheter is placed for pain control by the regional anesthesia team. The patient is then brought to the operating room. After induction of general anesthesia in the supine position, the patient is positioned in the beach-chair position. A pneumatic arm holder is used for positioning throughout the procedure. After the arm is sterilely prepared and draped free, the positioning of a large fluoroscopy machine is reversed so that the image intensifier is positioned toward the floor. The machine is positioned to image the entire shoulder joint, sterilely draped, and moved medially near the patient’s head to allow space for the surgical procedure and facilitate ease of use throughout the case (Fig 1).



**Fig 2.** Right shoulder at the time of surgery with the patient in the beach-chair position. The 3 working portals are highlighted: posterior, anterosuperior, and anteroinferior.

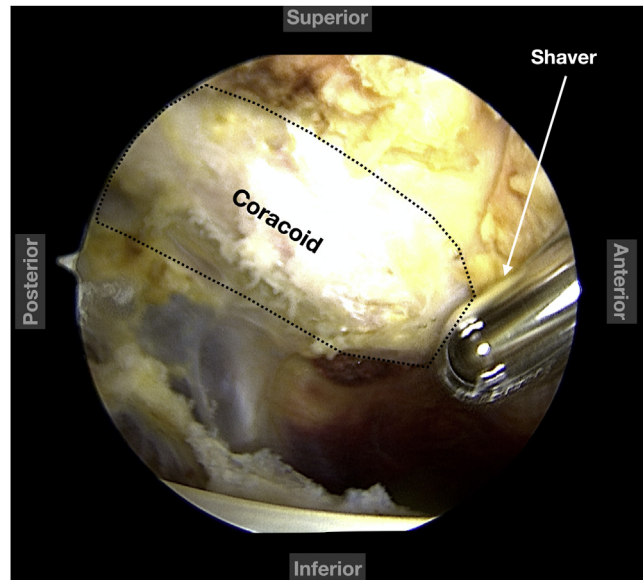
**Table 1.** Pearls and Pitfalls

Pearls	Pitfalls
An accessory anteroinferior portal is used to facilitate visualization about the coracoid during tunnel drilling and graft passage.	Ensure that the accessory anteroinferior portal is at the lateral level of the lateral border of the acromion.
A 70° arthroscope from the posterior portal can be used to aid in debridement of the inferior coracoid and subcoracoid space.	Avoid a laterally based posterior portal so that the arthroscope can be safely passed through the glenohumeral joint with the ability to look medially at the base of the coracoid and subcoracoid space to avoid deep neurovascular injury.
The large fluoroscopy machine should be wrapped in sterile cover prior to initiation of the case and moved over the patient’s contralateral shoulder during arthroscopy.	Ensure a true anteroposterior fluoroscopic view of the AC joint prior to reduction to ensure anatomic reduction and fixation.
A tensioning device under fluoroscopic imaging is used to safely and adequately reduce the AC joint.	

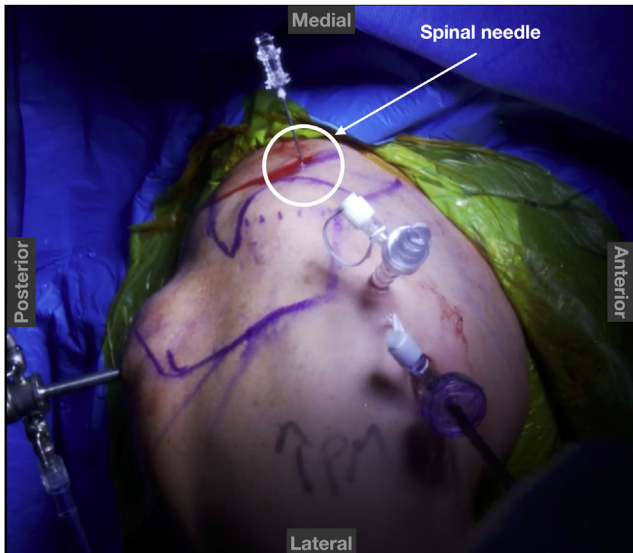AC, acromioclavicular.

**Diagnostic Arthroscopy and Subcoracoid Space Debridement**

After a surgical safety timeout, a standard posterior portal is established. A complete diagnostic arthroscopy is performed to examine for associated intra-articular pathology, which occurs in up to 40% of high-grade injuries.<sup>2,3</sup> Next, a rotator interval portal is established using an outside-in needle localization technique. This

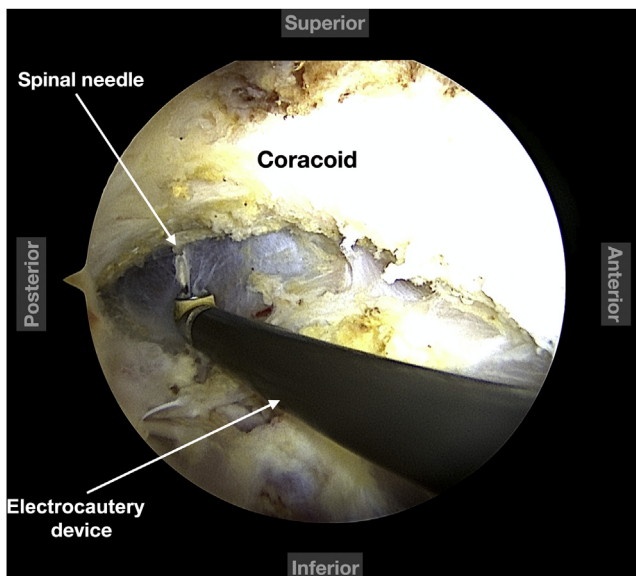


**Fig 3.** Arthroscopic view of right shoulder with the patient in the beach-chair position using a 70° arthroscope from the posterior portal showing debridement of the subcoracoid space.

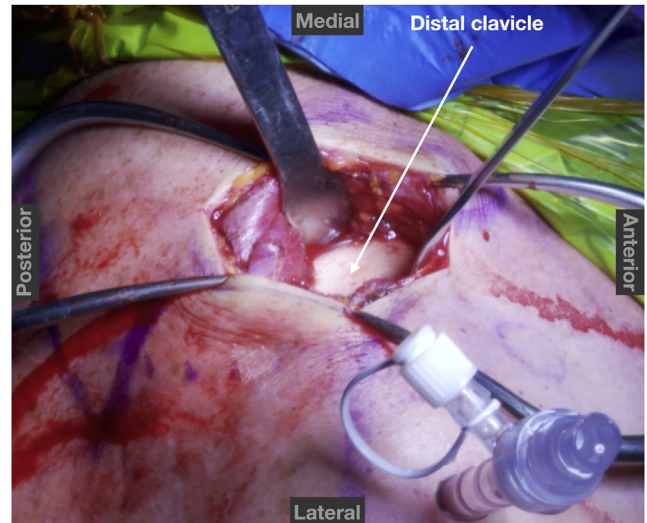


**Fig 4.** Right shoulder at the time of surgery with the patient in the beach-chair position showing the placement of the first spinal needle to determine the trajectory of the conoid ligament.

portal is placed laterally in the rotator interval to allow for ease of access to the subcoracoid space (Fig 2). If the portal is placed medially and too close to the coracoid, access to the subcoracoid space for debridement is limited by impingement of the coracoid itself. If visualization is difficult during debridement of the subcoracoid space while visualizing through the posterior portal, a 70° arthroscope can be used (Table 1). A combination of a 4.5-mm shaver and electrocautery device is then used through the rotator interval portal



**Fig 5.** Arthroscopic view of right shoulder with the patient in the beach-chair position using a 70° arthroscope from the posterior portal showing placement of the spinal needle to determine the trajectory of the conoid ligament.

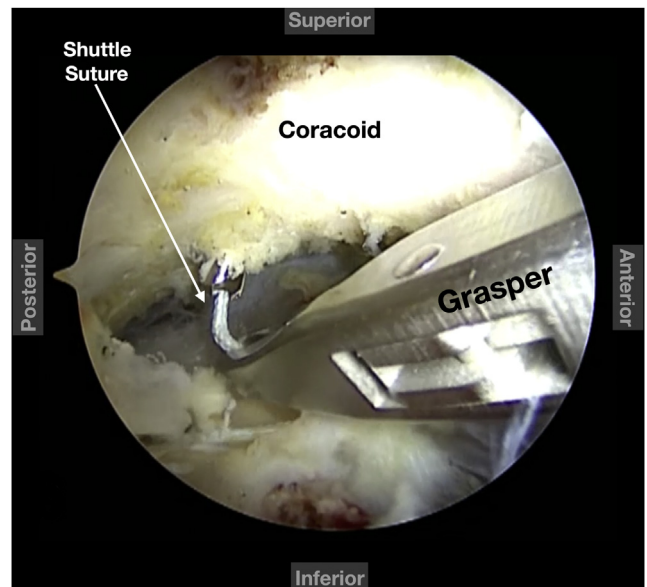


**Fig 6.** Right shoulder at the time of surgery with the patient in the beach-chair position showing the exposed distal clavicle prior to graft passage.

to skeletonize the undersurface of the coracoid to its base to aid in appropriate placement of the AC Tight-Rope (Arthrex, Naples, FL) and allograft (Fig 3).

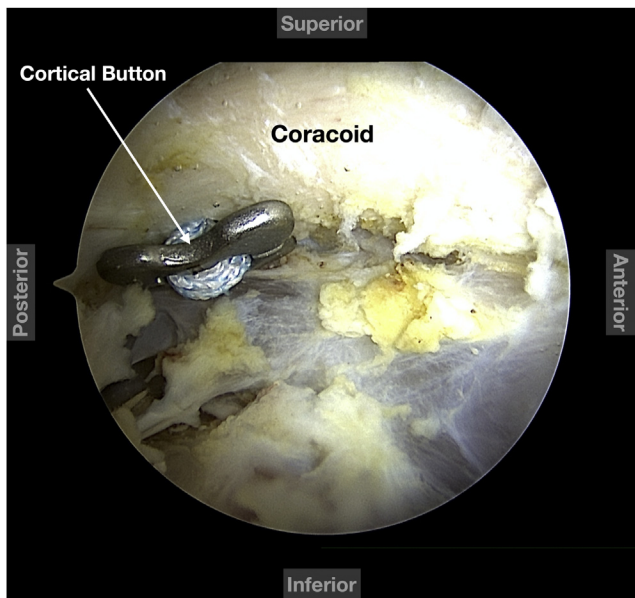
#### Anteroinferior Portal

After subcoracoid and coracoid debridement, an accessory anteroinferior portal is established, again using an outside-in needle localization technique. This portal is placed approximately 4 to 5 cm distal to the corner of the anterolateral acromion and is directed internally just above the subscapularis tendon at the lateral aspect of the rotator interval (Fig 2, Table 1). The



**Fig 7.** Arthroscopic view of right shoulder with the patient in the beach-chair position using a 70° arthroscope from the posterior portal showing grasping of the shuttle suture for later cortical button passage.



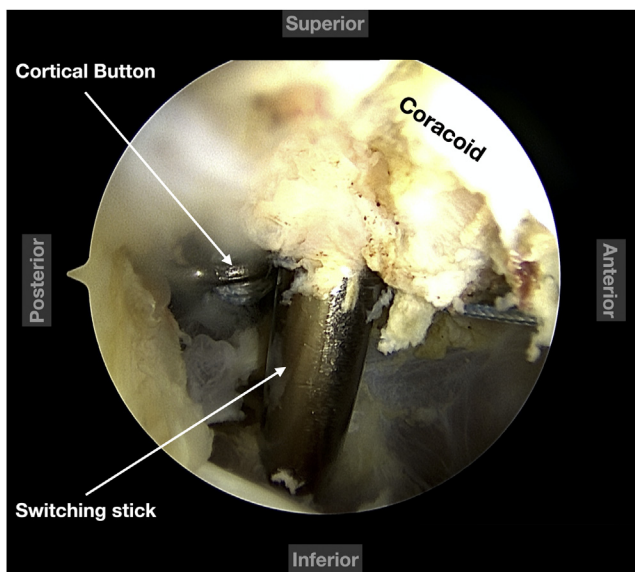


**Fig 8.** Arthroscopic view of right shoulder with the patient in the beach-chair position using a 70° arthroscope from the posterior portal showing correct placement of the cortical button.

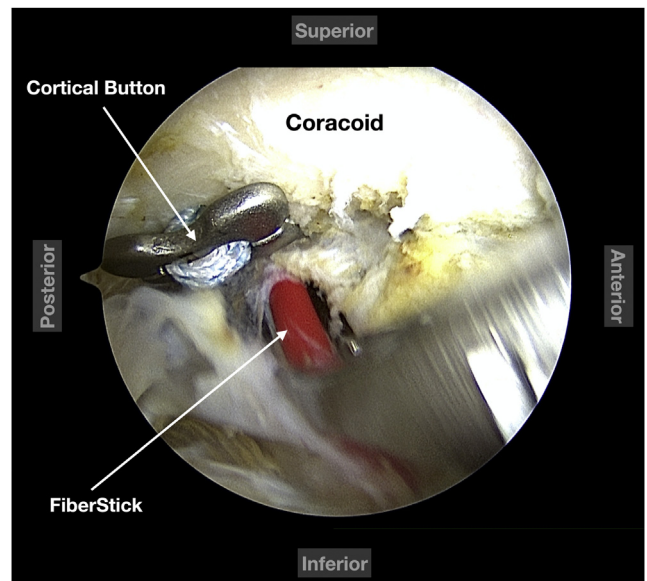
skin incision is made large enough to accommodate an Arthrex 8.25-mm  $\times$  7-cm Twist-In Cannula. Placement of the arthroscope through the cannula in the accessory anteroinferior portal will be used to visualize the coracoid during guidewire placement and allow graft passage around the coracoid.

### Coracoclavicular Ligament Reconstruction Preparation

While the coracoid is viewed from the accessory anteroinferior portal, the spinal needle is passed from




**Fig 9.** Arthroscopic view of right shoulder with the patient in the beach-chair position using a 70° arthroscope from the posterior portal showing passage of the switching stick to establish a soft-tissue canal for the graft.

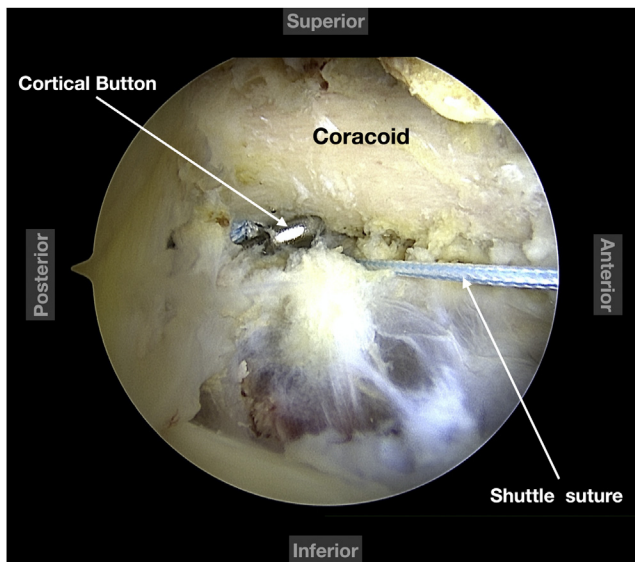


**Fig 10.** Arthroscopic view of right shoulder with the patient in the beach-chair position using a 70° arthroscope from the posterior portal showing introduction of the Arthrex FiberStick containing the shuttle suture for the graft.

posterior to the medial clavicle to exit just medial to the coracoid to determine the correct trajectory for the conoid ligament reconstruction and guide placement of the skin incision (Figs 4 and 5). A 2-cm incision is then made 25 mm medial to the ACJ from anterior to posterior over the clavicle (Fig 6). Dissection is carried out sequentially through both the deltotracheal fascia and ACJ capsule perpendicular to the skin incision to allow for later repair and imbrication at the conclusion of the reconstruction. An anterior cruciate ligament tibial guide is placed through the accessory anteroinferior portal and positioned in the central coracoid while the top of the guide is positioned in the central clavicle 25 mm medial to the ACJ. A cannulated guide pin is then advanced through the clavicle and coracoid. Once deemed in an acceptable position by arthroscopic view,

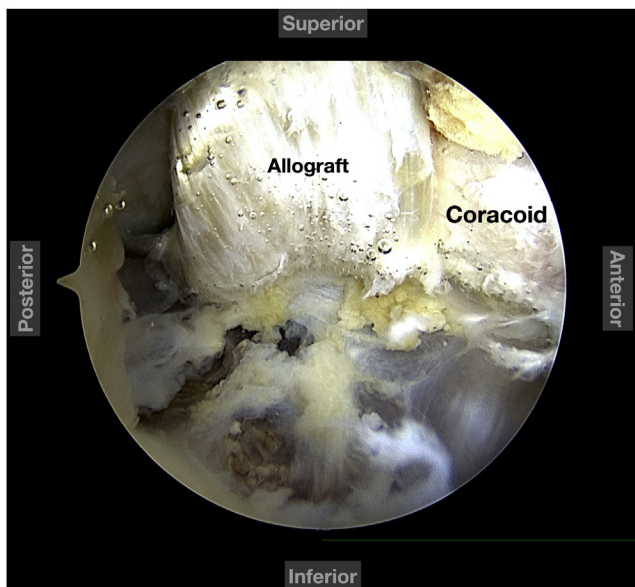


**Fig 11.** Prepared 8-mm allograft. The FiberTape that is shuttled together with the graft should be noted.

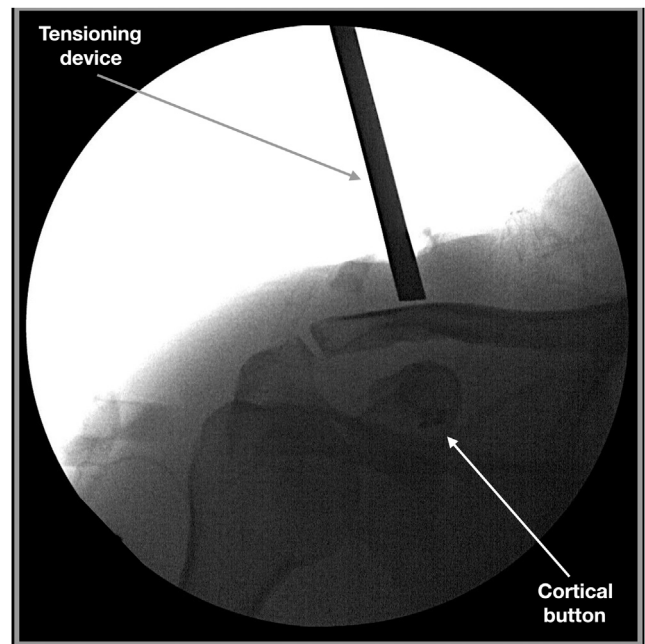


**Fig 12.** Arthroscopic view of right shoulder with the patient in the beach-chair position using a 70° arthroscope from the posterior portal showing that the shuttle suture for the graft has been passed.

a FiberStick (Arthrex) passing stitch is placed through the cannulated guidewire and retrieved out the antero-inferior portal for passage of an AC fixation device with suture tapes and cortical buttons (Fig 7). The suture tapes and Dog Bone button (Arthrex) are then passed from outside in through the antero-inferior cannula. The inferior Dog Bone cortical button is positioned flush at the inferior coracoid (Fig 8). While the



**Fig 13.** Arthroscopic view of right shoulder with the patient in the beach-chair position using a 70° arthroscope from the posterior portal showing the allograft in a looped configuration around the coracoid, re-creating the conoid and trapezoid ligaments.



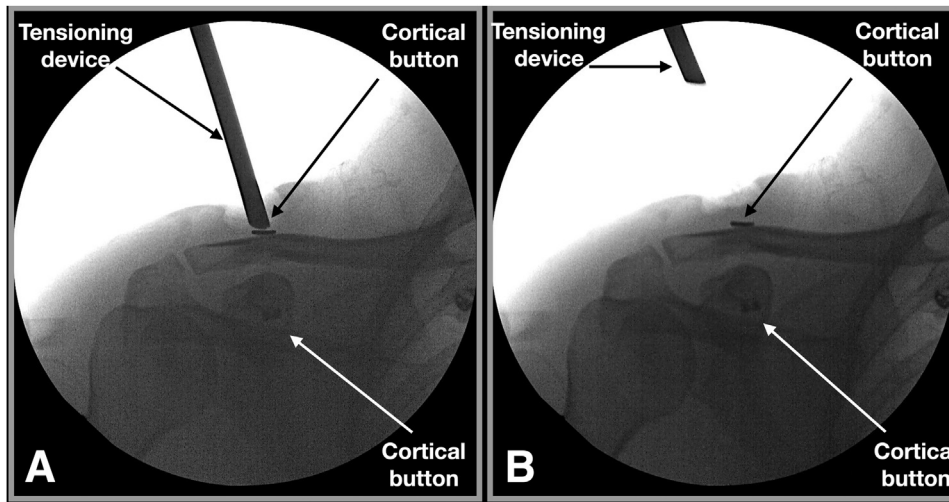
**Fig 14.** Anteroposterior fluoroscopic image of right shoulder showing reduction of the acromioclavicular joint with the tensioning device in place.

coracoid is viewed from the accessory antero-inferior portal, the spinal needle is once again passed from posterior to the medial clavicle to exit just medial to the coracoid (Fig 5). A switching stick is placed in this same trajectory, after which an 8.25-mm dilator is placed over the switching stick to create a soft-tissue tunnel to facilitate later graft passage (Fig 9). A FiberStick is then placed through this dilator, and the suture is used as a shuttle for later graft passage (Fig 10). This same process is repeated to reconstruct the trapezoid ligament with a trajectory starting from the anterior clavicle exiting lateral to the coracoid. The medial passing suture is used to shuttle an 8-mm tibialis anterior allograft, which was previously whipstitched at both ends (Fig 11), in addition to an extra-long FiberTape (Arthrex), to the posterior clavicle while the other end of the graft is shuttled to the anterior clavicle (Fig 12). This creates a loop of both the allograft and the FiberTape around the coracoid and clavicle (Fig 13).

#### Fluoroscopic-Assisted ACJ Reduction With Tensioning Device

The FiberTape previously passed around both the clavicle and coracoid is loaded into the tensioning device (FiberTape Tensioner; Arthrex). The C-arm is used to obtain a true anteroposterior image of the ACJ as the tensioner is slowly ratcheted to both clinically and fluoroscopically reduce the ACJ (Fig 14, Table 1). Once the ACJ is deemed adequately reduced, the 4 free strands of the previously passed AC fixation FiberTapes are passed through the 4 holes of a 10-mm cortical





**Fig 15.** Anteroposterior fluoroscopic images of right shoulder. (A) With the tensioning device in place, the cortical button is tied. (B) After tying of the cortical button, the tensioning device is released and fluoroscopy shows excellent reduction of the acromioclavicular joint.

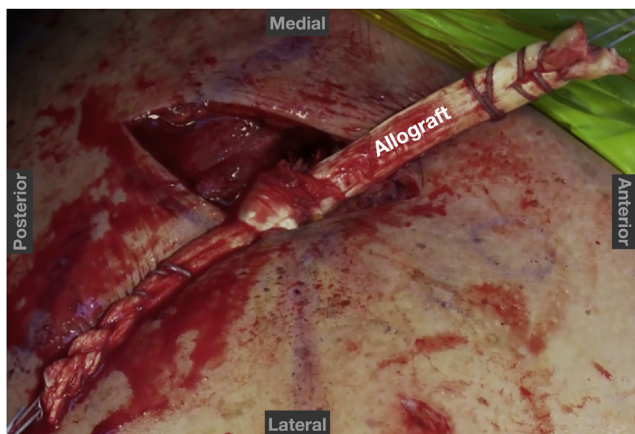
button and tied, fixing the ACJ in its reduced position, after removal of the tensioner (Fig 15).

### Completion of Coracoclavicular Ligament Reconstruction

The 2 free whipstitched ends of the allograft are twisted together in a surgeon's knot, tensioned, and secured with several figure-of-8 No. 2 nonabsorbable sutures to complete the allograft reconstruction (Fig 16). The excess free ends of the allograft are then cut.

### Closure

After copious irrigation, the remaining ACJ capsule is imbricated with a nonabsorbable suture. The delto-trapezial fascia is also closed longitudinally. The rest of the wound is closed in a layered fashion. A final anteroposterior fluoroscopic image of the ACJ is taken at the conclusion of the procedure to confirm appropriate reduction (Fig 17).



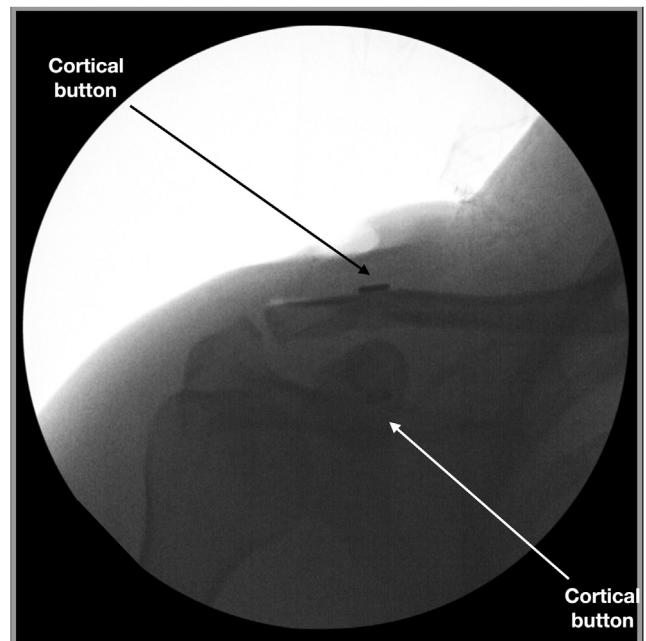
**Fig 16.** Right shoulder with the patient in the beach-chair position showing the graft, which has been tied to itself and is then secured by figure-of-8 stitches (not depicted).

### Postoperative Rehabilitation

An abduction sling is used for 6 weeks to both decrease the tension on the reconstruction and support the arm as the regional anesthesia persists. Immediate supine passive range-of-motion exercises are initiated on postoperative day 1. Active and active-assisted range-of-motion exercises begin at 4 weeks, and strengthening is initiated at 8 weeks. Return to full activities is expected by 16 weeks.

### Discussion

ACJ injuries are common, accounting for approximately 12% of the injuries to the shoulder girdle, and are especially common in certain sports including



**Fig 17.** Final anteroposterior fluoroscopic image of right shoulder after anatomic coracoclavicular joint reconstruction.

football, rugby, and downhill skiing.<sup>4</sup> Unfortunately, much controversy still exists in terms of both the management and technique of reconstruction. Regardless of the technique used, several principles are important to follow to obtain a safe and successful reconstruction. First, arthroscopy of the shoulder joint should be performed because 40% of high-grade injuries have been shown to have concomitant glenohumeral pathology,<sup>2,3</sup> which can be a recurrent pain generator if not addressed at the time of reconstruction. Second, large clavicle and coracoid bone tunnels should be avoided because these have been shown to increase the risk of fracture.<sup>5,6</sup> Our described technique uses a looped configuration of allograft to reconstruct both the conoid and trapezoid coracoclavicular ligaments to avoid bone tunnels and to decrease the risk of post-operative fracture. Finally, ACJ reduction should be performed in a controlled manner and confirmed fluoroscopically to reduce the risk of adjacent structure injury and to mitigate the risk of malreduction, which has been reported as a complication in up to 30% of cases.<sup>7</sup> Our technique uses a tensioning device to reduce, in a controlled fashion, the superiorly migrated clavicle to the acromion. Prior techniques of manually forcing the clavicle inferiorly with an instrument while axially loading the arm superiorly to elevate the acromion<sup>8</sup> are imprecise and potentially dangerous because the instrument on the superior clavicle can easily slip and injure the neurovascular structures just underneath the clavicle.

Although we are not suggesting that the proposed technique is the perfect solution for ACJ sprains, we do believe that several tenets of this technique are applicable to other techniques commonly practiced and will likely be a part of an optimal solution. Despite offering several advantages, this technique is not without limitations. First, although bone tunnels are limited, only one 2.4-mm tunnel is created through the clavicle and coracoid, which should decrease but not completely eliminate the risk of fracture. Second, the looped and tied allograft placed superiorly over the clavicle can be prominent and cause irritation in thin individuals. Finally, the fluoroscopically confirmed reduction increases the chance that the ACJ is properly reduced but

does not guarantee a perfectly reduced ACJ at final follow-up. In chronic cases or situations in which reduction is challenging, the senior author will frequently use additional ACJ fixation with a figure-of-8 FiberTape construct. Although not a panacea, our technique of anatomic coracoclavicular reconstruction using looped allograft with cerclage- and fluoroscopic-aided ACJ reduction and fixation is a safe, controlled, and reproducible technique to treat AC separations that results in consistent results.

## References

1. Kay J, Memon M, Alolabi B. Return to sport and clinical outcomes after surgical management of acromioclavicular joint dislocation: A systematic review. *Arthroscopy* 2018;34:2910-2924.e1.
2. Markel J, Schwarting T, Malcherczyk D, Peterlein CD, Ruchholtz S, El-Zayat BF. Concomitant glenohumeral pathologies in high-grade acromioclavicular separation (type III-V). *BMC Musculoskelet Disord* 2017;18:439.
3. Jensen G, Millett PJ, Tahal DS, Al Ibadi M, Lill H, Katthagen JC. Concomitant glenohumeral pathologies associated with acute and chronic grade III and grade V acromioclavicular joint injuries. *Int Orthop* 2017;41:1633-1640.
4. Aliberti GM, Kraeutler MJ, Trojan JD, Mulcahey MK. Horizontal instability of the acromioclavicular joint: A systematic review. *Am J Sports Med* 2020;48:504-510.
5. Martetschl ger F, Horan MP, Warth RJ, Millett PJ. Complications after anatomic fixation and reconstruction of the coracoclavicular ligaments. *Am J Sports Med* 2013;41:2896-2903.
6. Spiegl UJ, Smith SD, Euler SA, Dornan GJ, Millett PJ, Wijdicks CA. Biomechanical consequences of coracoclavicular reconstruction techniques on clavicle strength. *Am J Sports Med* 2014;42:1724-1730.
7. Glanzmann MC, Buchmann S, Audig  L, Kolling C, Flury M. Clinical and radiographical results after double flip button stabilization of acute grade III and IV acromioclavicular joint separations. *Arch Orthop Trauma Surg* 2013;133:1699-1707.
8. Frank RM, Trenhaile SW. Arthroscopic-assisted acromioclavicular joint reconstruction using the TightRope device with allograft augmentation: Surgical technique. *Arthrosc Tech* 2015;4:e293-e297.