CLINICAL ORTHOPAEDICS AND RELATED RESEARCH
Number 421, pp. 120–125

Glenoid Wear after Shoulder Hemiarthroplasty

Quantitative Radiographic Analysis

I. M. Parsons, IV, MD*; Peter J. Millett, MD, MSc†; and Jon J. P. Warner, MD†

Symptomatic glenoid arthrosis may limit the long-term success of shoulder hemiarthroplasty in patients who are young and functionally demanding. The principal objective of the current study was to quantify glenoid wear after proximal humeral replacement in young, active subjects. Eight patients, ages 21 to 60 years (mean, 45 years), met inclusion criteria. The mean followup was 43 months. Functional scores for the cohort averaged 60% of age and gender-adjusted healthy subjects (range, 28%–84%). Glenohumeral joint space was measured on serial axillary radiographs using a Microscribe 3-DX digitizing device (measurement accuracy, 0.23 mm). Progressive glenoid wear was found in all eight patients. The mean decrease was 2 mm (range, 1.3–2.8 mm), a 68% decrease in glenohumeral joint space. Glenoid cartilage wear also was correlated with Constant and Murley scores. Patients with residual joint spaces less than 1 mm had a mean score of 50%, compared with a score of 71% for patients with joint spaces greater than 1 mm. There were no correlations between wear and mechanism of injury, duration of symptoms, and prior surgery. This study suggests that glenoid cartilage erosion can be expected routinely after humeral head replacement in young, active individuals, and that such wear may adversely affect function or necessitate conversion to total shoulder arthroplasty.

For patients with a comminuted proximal humerus fracture or advanced avascular necrosis, humeral head replacement has been shown to yield excellent results, provided the glenoid and rotator cuff are preserved.[3,4,5,8,9] In young patients, however, the long-term outcomes after prosthetic humeral head replacement may be limited by the higher functional demands placed on the glenohumeral joint. The development of glenoid arthrosis is a recognized complication of proximal humerus replacement[15] and may contribute to less satisfactory pain relief and shoulder function. Loss of glenoid cartilage may necessitate conversion to a total shoulder arthroplasty, because there are limited surgical options to treat glenoid wear after humeral head replacement.

The incidence of clinically significant glenoid arthrosis after humeral head replacement is unknown, although outcome studies suggest that radiographic evidence of glenoid erosion and loss of glenoid cartilage occur in as many as 76% and 84% of patients, respectively.[15] Currently there are limited published data documenting the natural history of glenoid wear or its relationship to parameters such as age, preceding diagnosis, glenoid disease at the time of surgery, and functional outcome, and to our knowledge there are no studies which quantify the glenoid erosion.[3,5,9,14,15] Therefore, the principal objective of the current study was to determine by quantitative radiographic methods the glenoid wear after prosthetic humeral head replacement in young or active patients with minimal preoperative glenoid disease and an intact rotator cuff. A second objective was to correlate the degree of glenoid cartilage wear with functional outcome. It was hypothesized that accelerated glenoid wear would result in less satisfactory outcomes and would be predictive of the need for glenoid resurfacing.

MATERIALS AND METHODS

Patients were selected from a cohort of patients who had a prosthetic humeral head replacement. Criteria for inclusion in the current study included: (1) age 60 years or younger; (2) high preoperative functional demand based on continued performance of recreational activities or employment; (3) minimal glenoid cartilage degenerative changes as determined by intraoperative evaluation; (4) an intact rotator cuff at the time of surgery; and (5) sufficient radiographic followup to generate quantitative data on glenoid wear. Of 79 patients who had humeral head replacement by the senior author between 1991 and 1997, eight patients satisfied these criteria and comprised the cohort for investiga-

Received: December 3, 2001
Revised: January 21, 2003; May 14, 2003
Accepted: June 9, 2003
From the *University of Pittsburgh, Pittsburgh, PA, and †Harvard Shoulder Service, Brigham & Women's Hospital and Massachusetts General Hospital, Boston, MA.
Correspondence to: Jon J. P. Warner, MD, Harvard Shoulder Service, Massachusetts General Hospital, POB#403, 275 Cambridge St, Boston, MA 02114. Phone: 617-724-7300; Fax: 617-724-3846; E-mail: jwarner@partners.org.
DOI: 10.1097/01.blo.0000119249.61696.f1

tion. There were six men and two women with an average age of 45 years (range, 21–60 years). The dominant arm was involved in six patients.

Indications for hemiarthroplasty included an acute complex four-part proximal humerus fracture in five patients, osteonecrosis (ON) secondary to a proximal humerus fracture in two patients, and idiopathic ON in one patient. In the latter three patients, pain and functional disability unresponsive to conservative measures were the principal indications for humeral head replacement. In the group of patients with a fracture, the mechanism of injury involved high-energy trauma from a motor vehicle accident in four patients and a fall onto the upper extremity in three patients. In two patients with an acute fracture, the configuration included a head-splitting component. For the two patients with ON secondary to a fracture, one involved a displaced surgical neck fracture treated nonoperatively and the other involved a Grade I open four-part fracture dislocation treated by open reduction and internal rotation. In the latter patient, severe deformity of the humeral head had developed. Three other patients had prior shoulder surgery on the affected side. These procedures included an open capsular shift, an arthroscopic subacromial decompression, and an arthroscopic repair of a Bankart lesion.

All patients had shoulder hemiarthroplasty using an extended deltopectoral approach. In all patients, the humeral head was replaced using the Biomet Biomodular system (Biomet, Inc, Warsaw, IN). A standard surgical technique was used to restore length and proper humeral offset in the case of fractures. All components were placed in approximately 40° retroversion. To achieve these goals, preoperative templating allowed for appropriate humeral head size selection and proper humeral stem placement. In two patients the stem was a press-fit design, and in six patients it was cemented. Four patients required complex reconstruction of the greater tuberosity with local bone grafting. In all patients who required greater tuberosity reconstruction, the tendons could be repaired securely to bone without the need for complex tendon mobilization, augmentation, or transposition. At the conclusion of the procedure, the upper extremity was taken through a range of motion (ROM) in forward flexion, abduction, and internal and external rotation. This maneuver ensured proper soft tissue balancing with maintenance of concentric rotation and adequate excursion of the component under the acromion. Intraoperatively, the glenoid cartilage was inspected carefully for acute or chronic injury. Patients with significant cartilage fibrillation, early arthritic changes, or traumatic injury to the articular surface were excluded from the cohort.

Postoperatively, patients were followed up on a routine basis with a clinical examination and anteroposterior (AP) and axillary lateral radiographs. All radiographs were obtained in a standardized fashion by one experienced technician. Patient positioning was standardized by marks on the floor and wall for all radiographs. Outcome after proximal humerus replacement was assessed in terms of subjective and objective criteria. Postoperative pain was graded on a 1 to 10 scale with 10 representing severe, unremitting symptoms. Active motion in forward flexion and external rotation was assessed and overall functional outcome was graded according the Constant and Murley scoring system, which combines subjective and objective criteria to obtain a score based on a 100-point scale.[1] Values then were normalized to age- and gender-adjusted normal healthy control subjects and expressed as a percentage of the control value.

Glenoid cartilage wear was determined by measuring the width of the glenohumeral joint space on serial followup AP and axillary lateral radiographs using a Microscribe 3-DX digitizing device (Immersion Corporation, San Jose, CA) (Fig 1). This device consists of a swivel base and multidegree-of-freedom, serially articulated arm with a stylus for data acquisition. It records a Cartesian coordinate defined with respect to the coordinate system of the device's base. Its reported accuracy is 0.23 mm. Distances between points can be calculated based on the (X, Y) coordinate of the two points. For the current study, the Z coordinate was assumed to be the same between points on the radiograph because it lies on a flat surface during digitization.

The user accuracy of this digitizing technique was assessed by digitizing two points on a flat surface, which had a known fixed distance. Based on an analysis of the average measured distance between these fixed points, the user accuracy was 0.4 ± 0.17 mm. Therefore, for the current study, it was assumed that the Microscribe could reliably measure the joint space to within 0.5 mm on the radiograph, and similarly, that joint space values less than 1 mm could be measured feasibly in patients in whom there was near complete but not total glenoid cartilage erosion.

The Microscribe was used to digitize one point on the humeral head and glenoid, which grossly represented the narrowest point of articulation. Three measurements were taken on each film and an average distance was calculated from the recorded coordinates. To control for differences in magnification between films, all values were normalized by a scaling factor defined as the quotient of the known divided by measured humeral head diameter. The value for the denominator was determined using circle templates.

Although it has been suggested that a true AP film with the extremity in internal rotation provides the best profile of the

Fig 1. The Microscribe 3-DX digitizing device consists of a serially articulated arm with a terminal stylus for accurate measurement. The base contains a reference coordinate system within which a series of Cartesian coordinates can be defined. The reported accuracy for this device is 0.23 mm.

glenohumeral joint,[6,10] in the current patients a tangential image of the glenoid surface was found more reliably on the axillary lateral radiographs. True AP projections were inconsistent in imaging the joint space and did not provide useful information for joint space narrowing. Therefore, all data points were obtained from serial axillary lateral films obtained during followup.

The data were analyzed for the overall decrease in joint space from the time of initial humeral head replacement, the percent of joint space narrowing, the residual glenohumeral joint space, and the average decrease in joint space per year. These values then were correlated with patients' Constant and Murley scores determined at the most recent followup. Glenoid wear, which was defined as residual joint space and percent joint space narrowing, then was assessed for its effect on outcome by Spearman correlation coefficients. Based on the distribution of values for these two measures of glenoid wear, the data were parameterized into a residual joint space of greater than or less than 1 mm and percent wear of greater than or less than 75%. The significance of these parameters relative to the Constant and Murley score was determined with a Cochran-Mantel-Haenszel chi square test. Statistical significance was set at $p < 0.05$.

RESULTS

The mean duration of followup was 43 months (range, 25–78 months). There were no postoperative complications related to hematoma, infection, tendon rupture, adhesive capsulitis, or reflex sympathetic dystrophy. Subjectively, patients rated their postoperative pain at a mean level of 4 of 10 (range, 1 of 10–8 of 10). Six patients stated that their pain was largely activity-related whereas two patients had more persistent symptoms. These latter two involved a patient with a comminuted four-part proximal humeral fracture, which required greater tuberosity reconstruction with iliac crest bone graft, and a patient who had ON develop after a displaced surgical neck fracture. Their individual subjective pain ratings were 7 of 10 and 8 of 10, respectively. Objectively, patients in this cohort achieved a mean forward flexion of 100° (range, 45°–145°) and mean external rotation of 40° (range, 20°–60°). The average age- and gender-adjusted Constant and Murley score was 60% of normal healthy control subjects (range, 28%–84%).

Progressive glenoid wear occurred in all patients in this series within the followup studied (Fig 2). The average measured joint space on the postoperative film taken at the first office visit was 2.9 mm (range, 1.9–3.8 mm). This radiographic value was defined as the initial joint space value, as axillary lateral films were not obtained reliably in the recovery room after surgery. Based on the measured value at the most recent followup, the mean residual joint space remained 1 mm (range, 0.3–1.8 mm). This change represented an average of 2 mm of joint space narrowing during the followup interval of 43 months. Relative to the initial joint space, this degree of narrowing amounts to an average 68% (range, 26%–95%) narrowing within a short period, with this technique of evaluation. When raw values were divided by individual followup, the rate of glenoid wear was 0.9 mm/year (range, 0.6–1.2 mm/year).

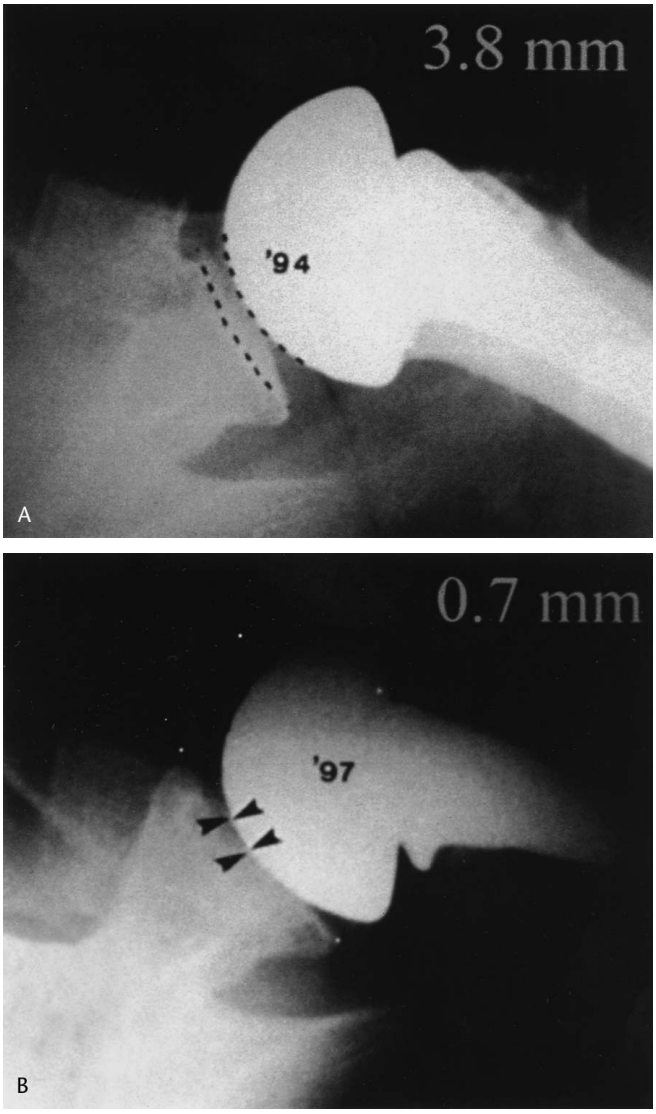

Fig 2. This series of axillary lateral radiographs shows progressive loss of glenoid cartilage during a 3-year period based on narrowing of the glenohumeral joint space. (A) This is an axillary view of the glenohumeral joint immediately after surgery that shows an articular cartilage thickness of 3.8 mm. (B) This is an axillary view of the same shoulder 3 years later. The residual glenohumeral joint space of 0.7 mm represents an 83% decrease in the thickness of the glenoid articular cartilage.

Although the Spearman correlations of the Constant and Murley score with residual joint space ($p = 0.062$; $R = 0.57$) and percent wear ($p = 0.55$; $R = 0.64$) were not

statistically significant ($p > 0.05$), the data revealed a trend that suggests that glenoid wear may influence outcome after humeral head replacement (Figs 3, 4). When the data were stratified, a statistically significant correlation could be found between a Constant and Murley score less than 60% and a residual joint space less than 1 mm at the most recent followup ($p < 0.05$) by a chi square analysis. Similarly, there was a statistically significant correlation between a Constant and Murley score less than 60% and a percent wear greater than 75% of the initial joint space. Patients whose residual joint space measured less than 1 mm achieved a mean Constant and Murley score of 50%, compared with 71% for patients with a residual joint space greater than 1 mm. Similarly, patients whose percentage of glenoid wear was greater than 75% achieved a mean Constant and Murley score of 41%, compared with 74% for patients whose degree of glenoid wear was less than 75%.

With the numbers available for study, analysis of subjective and objective outcome measures did not reveal any significant correlation between subjective pain or ROM and measures of glenoid wear. Additionally, no factors showed a statistically significant correlation with worsening glenoid wear, including mechanism of injury, duration of symptoms, prior surgery, or greater tuberosity reconstruction. The study of two patients was terminated when both had total shoulder arthroplasty. One patient had a four-part proximal humeral fracture, which required greater tuberosity reconstruction. The other patient had ON develop after a displaced surgical neck fracture, which originally was treated nonoperatively. Glenoid resurfacing occurred 4.2 and 5.6 years after the initial humeral head replacement, respectively, and was done for persistent pain. Both patients had a residual joint space measuring less than 1 mm and both had glenoid wear greater than 75% of the initial joint space value. Before total shoulder arthroplasty, their Constant and Murley scores were 38% and 41%, respectively.

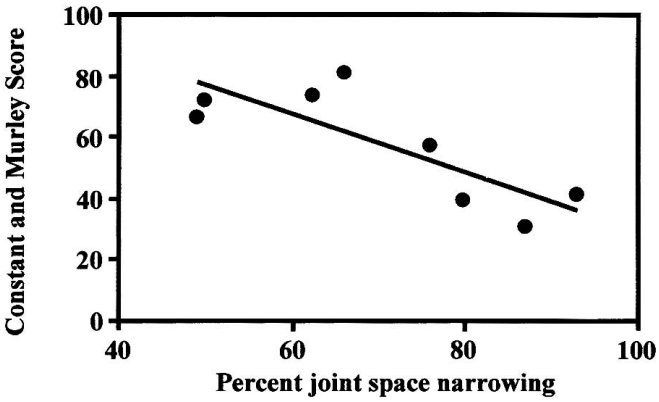

Fig 3. The graph shows the Constant and Murley score as a function of percent joint space narrowing. The trend line indicates a pattern of lower outcome scores for patients with more advanced joint space narrowing.

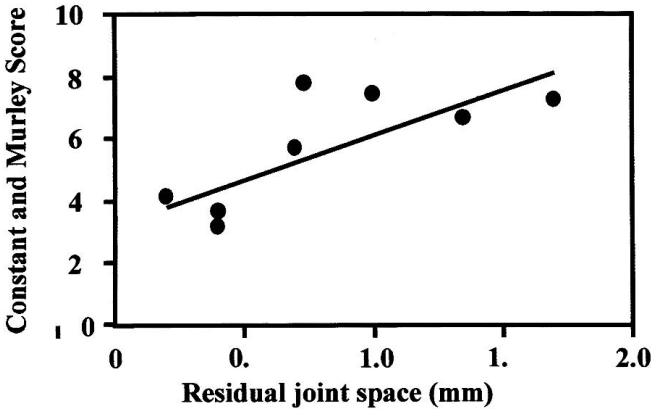

Fig 4. This graph shows the Constant and Murley score as a function of residual joint space. The trend line indicates a pattern of worsening outcomes the smaller the residual joint space. This trend is particularly evident for residual joint space values less than 1.0 mm.

DISCUSSION

The current study provides preliminary evidence that glenoid wear can be expected and detected in young or active patients with an intact rotator cuff and a normal glenoid within the first few years of prosthetic humeral head replacement. Although the sample size of this investigation precluded the determination of a statistically significant correlation between progressive glenoid wear and worse outcome, there was a trend toward such a relationship. Furthermore, for two patients with advanced glenoid wear, the conversion to a total shoulder arthroplasty with glenoid resurfacing within 5 years of the index procedure suggests that loss of glenoid cartilage portends a negative prognosis, especially when the residual joint space measures less than 1 mm.

Although previous studies have recognized glenoid wear as a potential complication of humeral head replacement, there are limited reports addressing its frequency of occurrence or its natural history with time. Sperling et al,[15] reporting on long-term outcomes in patients younger than 50 years who had a Neer hemiarthroplasty, evaluated postoperative radiographs for loss of glenoid cartilage. Qualitative radiographic evidence of cartilage loss was observed in 84% of patients, 76% of whom had preoperative glenoid cartilage deficiency. Therefore, of patients with no preoperative glenoid disease, only 8% later had glenoid wear develop. In their series, 15 of 78 patients had eventual revision surgery, 11 of which were attributable to painful

glenoid arthrosis. Loss of glenoid cartilage was not associated with an unsatisfactory outcome based on a modification of the grading system of Neer. Levine et al[7] correlated results of hemiarthroplasty to degree of glenoid erosion for patients who had proximal humerus replacement for osteoarthritis. Preoperative posterior glenoid erosion was significantly associated with unsatisfactory results, which were attributed to loss of forward elevation and external rotation. Postoperative progression of glenoid erosion was not examined.

In contrast to these studies, the uniform occurrence of glenoid wear in the cohort being investigated in the current study is likely attributable to the narrow selection criteria used for inclusion. Younger, functionally demanding patients with an intact rotator cuff and minimal or no preoperative glenoid articular disease represent a small subset of all patients who have prosthetic humeral head replacement. However, the natural history of glenoid wear in such patients is important and may predict the long-term success of humeral head replacement because symptomatic glenoid arthrosis ultimately may necessitate conversion to total shoulder arthroplasty. Such revision surgery may occur sooner than would be expected for older more sedentary patients having proximal humerus replacement for osteoarthritis. Sperling and Cofield,[14] in a review of 34 studies involving 581 cases of proximal humerus replacement, found that painful glenoid arthrosis was the most common reason for conversion to total shoulder arthroplasty. Although these results cannot be generalized, they highlight a clinical problem which may limit the long-term success of humeral head replacement in a select population of patients for whom there are limited surgical alternatives.

The development of glenoid wear likely is attributable to changes in the glenohumeral loading mechanics as a result of anatomic differences between the native and prosthetic humeral heads. The anatomy of the reconstruction regarding restoration of the native offset, inclination, head size, and version may affect joint reactive forces during loading of the glenohumeral joint. de Leest et al[2] studied the influence of component geometry on muscle forces based on an inverse dynamic three-dimensional shoulder model and found that changes in the position of the geometric center of rotation of the glenohumeral joint relative to the shaft of the humerus may result in large changes in the force generated by the deltoid muscle. The level of humeral head resection, prosthetic head size, and amount of retroversion all were found to affect the position of the center of rotation relative to the shaft. Pearl and Kurutz[11] did a geometric analysis of four commonly used humeral prostheses, including the implant system used in the current study, to determine how effectively different implants preserved the anatomic and mechanical relationships of the intact shoulder. Using a computer optimization algorithm which selected implant size based on the least displacement of the center of rotation, the Biomet Biomodular system resulted in a mean glenohumeral center of rotation displacement of 20.2 mm. Of the four implants investigated, this implant design had the strongest correlation between the radius of curvature of the head and magnitude of displacement of the center of rotation in the lateral and superior directions. These findings suggest that proximal humerus replacement using this system results in a shift in the joint center. Such a shift influences the magnitude of force transmitted across the joint by changing the moment arms of the rotator cuff and deltoid muscles.[12,13] By virtue of changes in articular conformity and changes in muscle moment arms, altered loading conditions after humeral head replacement may contribute to the development of tensile and sheer forces at the implant-cartilage interface, which cause accelerated cartilage degeneration on the glenoid side. Because of differential effects of component design on glenohumeral joint kinematics, the findings of the current study cannot be generalized to humeral head replacement using other component systems.

Despite measures to control for differences in magnification between images, radiographic studies are limited by the quality and variability of postoperative films. Such limitations precluded investigations of other important parameters, which may be associated with the etiology of glenoid wear, such as glenoid erosion, humeral offset, articular conformity, or other mechanical parameters. The method of determining glenoid arthrosis was aimed at detecting early joint space narrowing, and thus radiographic followup was limited to images which were taken with the xray beam perpendicular to the plane of the glenohumeral joint.

Additional studies should include the use of computed tomography (CT) scans for more accurate quantitative analysis of joint space narrowing and for evaluation of other parameters of glenoid arthrosis such as posterior glenoid erosion and the degree of conformity of implant-cartilage interface. Radiographic and CT findings from the contralateral shoulder would provide valuable information about the normal anatomic relationship between the humeral head and the glenoid to which comparisons from the operative side could be made. Such information might refine the understanding of mechanical factors associated with the development of glenoid arthrosis. Finally, additional study will lead to improved understanding of the clinical course and may show a relationship between glenoid wear and outcome.

References

1. Constant CR, Murley AH: A clinical method of functional assessment of the shoulder. Clin Orthop 214:160–164, 1987.

2. de Leest O, Rozing PM, Rozendaal LA, et al: Influence of glenohumeral prosthesis geometry and placement on shoulder muscle forces. Clin Orthop 330:222–233, 1996.
3. Goldman RT, Koval KJ, Cuomo F, et al: Functional outcome after humeral head replacement for acute three- and four-part proximal humeral fractures. J Shoulder Elbow Surg 4:81–86, 1995.
4. Hawkins RJ, Switlyk P: Acute prosthetic replacement for severe fractures of the proximal humerus. Clin Orthop 289:156–160, 1993.
5. Kay SP, Amstutz HC: Shoulder hemiarthroplasty at UCLA. Clin Orthop 228:42–48, 1988.
6. Kerr R, Resnick D, Pineda C, et al: Osteoarthritis of the glenohumeral joint: A radiologic-pathologic study. Am J Roentgenol 144:967–972, 1985.
7. Levine WM, Djurasovic M, Glasson JM, et al: Hemiarthroplasty for glenohumeral arthritis: Results correlated to degree of glenoid wear. J Shoulder Elbow Surg 6:449–454, 1997.
8. Moeckel BH, Dines DM, Warren RF, et al: Modular hemiarthroplasty for fractures of the proximal part of the humerus. J Bone Joint Surg 74A:884–889, 1992.
9. Neer II CS: Replacement arthroplasty for glenohumeral osteoarthritis. J Bone Joint Surg 56A:1–13, 1974.
10. Norris TR, Green A: Imaging Modalities in the Evaluation of the Shoulder. In Matsen FA, Fu FH, Hawkins RJ (eds). The Shoulder: A Balance of Mobility and Stability. Rosemont, IL, American Academy of Orthopaedic Surgeons 353–368, 1993.
11. Pearl ML, Kurutz S: Geometric analysis of commonly used prosthetic systems for proximal humerus replacement. J Bone Joint Surg 81A:660–671, 1999.
12. Poppen NK, Walker PS: Forces at the glenohumeral joint in abduction. Clin Orthop 135:165–170, 1978.
13. Rietveld AB, Daanen HA, Rozing PM, et al: The lever arm in glenohumeral abduction after hemiarthroplasty. J Bone Joint Surg 70B:561–565, 1988.
14. Sperling JW, Cofield RH: Revision total shoulder arthroplasty for the treatment of glenoid arthrosis. J Bone Joint Surg 80A:860–867, 1998.
15. Sperling JW, Cofield RH, Rowland CM: Neer hemiarthroplasty and Neer total shoulder arthroplasty in patients fifty years old or less: Long-term results. J Bone Joint Surg 80A:464–473, 1998.