



Open Anterior Capsular Reconstruction With a Dermal Allograft Is a Viable Nonarthroplasty Salvage Procedure for Irreparable Subscapularis Tears at a Minimum 2-Year Follow-up

Simon Lee, M.D., M.P.H., Dylan R. Rakowski, B.S., Marilee P. Horan, M.P.H., Jared A. Hanson, B.A., Justin J. Ernat, M.D., M.H.A., and Peter J. Millett, M.D., M.Sc.

Purpose: To elucidate the clinical outcomes of patients who underwent anterior capsular reconstruction (ACR) with dermal allograft for irreparable subscapularis tears in native shoulders at a minimum of 2-year follow-up. **Methods:** This study included patients who underwent ACR by a single surgeon between March 2015 and September 2018. Clinical and intraoperative findings were recorded. Patient-reported outcomes were evaluated pre- and postoperatively, including American Shoulder and Elbow Surgeons, Single Assessment Numeric Evaluation, General Health Short-Form 12 Physical Component Summary and patient satisfaction (on a 1-10 scale, with 10 = best). Failure was defined as revision subscapularis surgery or conversion to reverse total shoulder arthroplasty. **Results:** Seven patients who underwent ACR at a mean age of 53 ± 7.3 years at the time of surgery were included. Median time from injury to surgery was 13.8 months (range 13.8-32.0 months). Two patients had concomitant superior capsular reconstruction. One patient progressed to a reverse total shoulder arthroplasty at 6.8 months. Minimum 2-year follow-up was obtained in the remaining 6 of 6 (100%) patients, with a mean follow-up of 3.4 years (range 2.0-6.2). There was significant improvement in the Quick Disabilities of the Arm, Shoulder and Hand score (preoperative: 32.7, postoperative: 9.5, $P = .04$), whereas the American Shoulder and Elbow Surgeons score, Single Assessment Numeric Evaluation, and SF-12 PCS scores demonstrated nonsignificant improvement. Median patient satisfaction was 9.5 (range 7-10). **Conclusions:** This small cohort of patients had a significant improvement in Quick Disabilities of the Arm, Shoulder and Hand score, high patient satisfaction, and relatively low conversion rate to reverse total shoulder arthroplasty. These clinical outcomes demonstrate that ACR with a dermal allograft may be a viable salvage operation for irreparable subscapularis tears in the short-term. **Level of Evidence:** Level IV, therapeutic case series.

Irreparable subscapularis (SSc) deficiency is a relatively less-common rotator cuff pathology that presents a difficult clinical scenario for the treating shoulder surgeon and can result in severe functional

deficits for patients. Patients experience weakness and pain with internal rotation with subsequent progression to anterior shoulder instability and rotator cuff arthropathy.¹⁻³ In one series of 580 patients undergoing

From the Steadman Philippon Research Institute, Vail, Colorado (S.L., D.R.R., M.P.H., J.A.H., J.J.E., P.J.M.); Northwestern Medicine, Chicago, Illinois (S.L.); University of Utah Health, Salt Lake City, Utah (J.J.E.); and The Steadman Clinic, Vail, Colorado (P.J.M.) U.S.A.

The authors report the following potential conflicts of interest or sources of funding: S.L., D.R.R., M.P.H., and J.A.H., report other from Steadman Philippon Research Institute, outside the submitted work. J.J.E. reports personal fees from Johnson & Johnson, DePuy Mitek Sports Medicine, other from Smith & Nephew, and other from Steadman Philippon Research Institute, outside the submitted work. P.J.M. reports grants, personal fees and other from Arthrex; personal fees from Springer Publishing; personal fees from Medbridge; and other from VuMedi, ProofPoint Biologics, Steadman Philippon Research Institute, Smith & Nephew, Siemens, and Ossur, outside the submitted work. This work was partially funded by a private grant from Paul and Lee Schmidt. Full ICMJE author disclosure forms are available for this article online, as [supplementary material](#).

Associated abstract was accepted as an ePoster at the AANA 2022 Annual Meeting.

Research performed at the Steadman Philippon Research Institute, Vail, Colorado, U.S.A.

Received November 23, 2021; accepted April 11, 2022.

Address correspondence to Peter J. Millett, M.D., M.Sc., Steadman Philippon Research Institute, The Steadman Clinic, 181 W Meadow Dr., Ste 400, Vail, CO 81657. E-mail: drmillett@thesteadmanclinic.com

© 2022 THE AUTHORS. Published by Elsevier Inc. on behalf of the Arthroscopy Association of North America. This is an open access article under the CC BY-NC-ND license (<http://creativecommons.org/licenses/by-nc-nd/4.0/>). 2666-061X/211647

<https://doi.org/10.1016/j.asmr.2022.04.005>

rotator cuff operations, 6.2% presented with irreparable SSc tears.⁴ These irreparable SSc tears can be the result of previous failed repair or neglected massive tears and present as a challenging treatment dilemma.⁵ Pectoralis major tendon transfers (PMTs) and latissimus dorsi tendon transfers (LDTs) have been developed to treat this pathology and may be used to improve glenohumeral stability.^{4,6-9} However, despite good satisfaction in certain populations, these tendon transfers have limitations of nonanatomic reconstruction, moderate rate of progression of radiographic cuff arthropathy, and less-predictable outcomes in the setting of concomitant recurrent glenohumeral instability.^{8,10} In addition, tendon transfers are associated with significant retear rates and complications such as musculocutaneous or axillary nerve injury.^{4,11} Regardless of these concerns, they are used to avoid reverse total shoulder arthroplasty (RTSA), particularly in young, active patients or patients without glenohumeral osteoarthritis.

Anterior capsular reconstruction (ACR) is a recently described technique using a dermal allograft to restrain the humeral head and prevent anterior translation in the setting of SSc insufficiency that aims to optimize the force-coupling mechanism. ACR has evolved based on the principles of the superior capsular reconstruction (SCR) described by Mihata et al.¹²⁻¹⁵ The development of this technique draws from the excellent biomechanical outcomes of SCR that are the result of the restoration of superior glenohumeral stability and humeral head depression.^{14,16} Furthermore, capsular reconstruction provides the potential advantages over tendon transfer including a more "anatomic" reconstruction, a low risk of iatrogenic neurologic injury, and notable reduction in donor-site morbidity.^{15,17,18} A recent biomechanical study by Komperda et al.¹⁹ demonstrated that PMT alone is unable to restore anterior shoulder stability in the setting of SSc and anterior capsular deficiency and that ACR with and without PMT, restored anterior–inferior stability to that of the intact condition. Therefore, ACR has the potential to be an additional option to avoid, or at a minimum, delay the need for RTSA.

Previously, ACR techniques have used tendon and muscle allografts and autografts in the setting of end-stage instability due to deficient capsulolabral tissues with an intact SSc tendon.¹⁸ ACR with a dermal allograft offers a larger contact area between the graft and the humeral head and serves to recreate a static restraint.^{15,18} Given the relatively recent development of ACR with dermal allograft for the treatment of irreparable SSc tears, there is a paucity of clinical outcome studies in the literature on this topic. The purpose of the current study is to elucidate the clinical outcomes of patients who underwent ACR for irreparable SSc tears in native shoulders at a minimum of 2-year follow-up.

We hypothesized that ACR with dermal allograft would provide improved clinical outcomes and patient satisfaction while having low complication and revision rates.

Methods

This retrospective review of prospectively collected data was conducted after obtaining approval from the Vail Health Hospital institutional review board under study number 2021-075. Patients who underwent ACR in native shoulders by the senior surgeon, (P.J.M.) from March 2015 to September 2018 and were at least 2 years out from surgery and had not undergone previous prosthetic arthroplasty were included. No patients were excluded.

Patient Demographics, Examination, and Operative Data

Patient demographics including sex, age, mechanism of injury, previous surgeries, time to surgery, worker's compensation status, hand dominance, and operative data were collected from the institutional database. Anterior shoulder instability was evaluated using an anterior apprehension test and relocation test. SSc integrity was evaluated using bear-hug, lift-off, and belly press tests. All patients were evaluated with standard radiography as well as advanced imaging that included magnetic resonance imaging. Before surgery, the potential risks and benefits of the procedure were discussed with the patient. Discussion included detailing that this was a salvage procedure and that the patient should be aware of certain precautions regarding contact sports and overhead activities. The ultimate decision to proceed with ACR was made intraoperatively based on the size of the defect, tissue quality, degree of retraction, and ability to mobilize the tissue after releases. Specific focus was placed on the ability to mobilize the SSc tendon to appropriately cover the anatomic footprint without placing a potential repair under excessive tension in the setting of a degraded tendon.

Surgical Technique

The ACR surgical technique has been previously published but will be briefly reviewed.¹⁵ The patient is placed in the beach-chair position with the operative extremity situated in a pneumatic arm holder (Tenet T-Max Beach Chair and Spider arm positioner; Smith & Nephew, Memphis, TN). A diagnostic arthroscopy is performed using a standard posterior viewing portal and a standard anterior viewing portal through the rotator interval. Once the SSc deficiency is confirmed and the decision to proceed with ACR is made, the open portion of the case is performed.

The anterior glenohumeral joint is exposed through a standard deltopectoral approach, exposing the glenoid

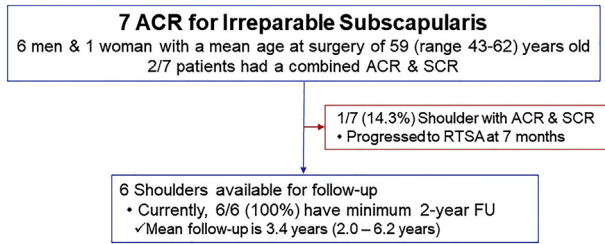


Fig 1. Flow diagram of the study cohort. (ACR, anterior capsular reconstruction; RTSA, reverse total shoulder arthroplasty; SCR, superior capsular reconstruction.)

and the anterior glenoid rim. Debridement of the remnant SSc and capsular tissue is performed, and any residual labrum is removed. The anterior glenoid is lightly decorticated and three 3.0-mm knotted BioComposite SutureTak anchors preloaded with FiberWire (Arthrex, Naples, FL) are inserted into the anterior glenoid rim at the 5-, 3-, and 1-o'clock positions. A 3.5-mm thick human acellular dermal patch (ArthroFlex; Arthrex) is then appropriately sized and the 2 suture limbs from the middle glenoid suture anchor are passed through the midpoint of the medial edge of the graft with a suture passer (Scorpion Suture Passer; Arthrex). One limb from the inferior anchor and one limb from the superior anchor are then passed through the superior and inferior aspects of the graft, respectively. The graft is shuttled down to the glenoid by use of an arthroscopic knot pusher. The middle suture limbs are tensioned and tied. The additional superior and inferior limbs that were not passed through the graft are passed through the adjacent tissue and tied to their counterpart limb and tensioned, thus preventing "dog-ear" formation on the inferomedial and superomedial corners.

The lesser tuberosity is then prepared to expose a bleeding bony bed to optimize healing. Typically, a hybrid double-row bridging repair (SpeedBridge kit; Arthrex) with 4 anchors is performed (2 medial and 2 lateral anchors) for the lateral humeral-sided fixation. Fixation is performed with the humerus in 30° of abduction, 30° of external rotation, and 30° of forward elevation. Two margin convergence sutures are then placed at the lateral part of the superior aspect of the graft into the leading edge of the supraspinatus tendon that can be identified in the recess of the glenohumeral joint. Before wound closure, a complete dynamic evaluation is performed with particular emphasis on testing stability in the abducted and externally rotated position to ensure adequate stability and security of the repair.

In 2 cases, patients also had a supraspinatus deficiency and required a combined ACR and SCR. Previously published SCR techniques can be reviewed here.^{20,21} The aforementioned principles of the

technique remain as described; however, the procedure is expanded to include the superior capsule. Notable alterations include extension of the light decortication of the glenoid in the superior and posterior direction to accommodate the placement of 2 additional 3.0-mm knotted BioComposite SutureTak anchors preloaded with FiberWire into the glenoid rim at the 9- and 11-o'clock positions. In these cases, anchor placement begins at the 9-o'clock position and progresses clockwise with the anchors being placed percutaneously if needed. Care is taken to prevent "dog-ear" formation by sequentially passing suture limbs through the medial aspect of the graft, again beginning at the 9-o'clock position and progressing clockwise. The bleeding bony bed prepared on the humerus includes the greater and lesser tuberosities to optimize healing of the lateral portion of the graft to the SSc and supraspinatus footprints. In these cases, the double-row bridging repair is performed using 8 anchors (4 medial and 4 lateral). Lastly, the 2 margin convergence sutures are placed to secure the graft to the infraspinatus tendon.

Postoperative Rehabilitation

Postoperatively, all patients must follow a strict SSc tendon repair rehabilitation protocol beginning with shoulder immobilization in a sling with external rotation limited to neutral for 2 weeks and then to 30° through week 6. If a biceps tenodesis is also performed, resisted elbow flexion should be restricted for 6 weeks. Wrist and hand exercises are permitted during this time. Pendulum exercises are initiated at 6 weeks. Active range of motion is started at 6 to 8 weeks. Return to activity is expected after 6 months when full range of motion and strength have been achieved. Patients are counseled that there is the potential for some loss of external rotation and forward flexion; however, the goal is to obtain a stable shoulder with at least 45° of external rotation and 140° of forward flexion.

Questionnaire Administration and Patient-Reported Outcomes (PROs) Assessment

Patients were given questionnaires to complete pre- and postoperatively. Postoperatively, patients were sent questionnaires via email on the yearly anniversary of their surgery. Patients without minimum 2-year outcomes in the institutional database were contacted and, after obtaining consent, were sent a link via email to complete the electronic questionnaire. PROs collected included the American Shoulder and Elbow Surgeons (ASES; 100 = best score) score, Single Assessment Numeric Evaluation (SANE; 100 = best score) score, Quick Disabilities of the Arm, Shoulder and Hand (QuickDASH; 0 = best score) score, Short-Form 12 Physical Component Summary (SF-12 PCS; greater scores correspond with better health) score, and patient satisfaction (scale 0-10; 0 = very unsatisfied, 10 = very satisfied).

Table 1. Patient Demographics

Patient	Age, y/Sex	MOI	Previous Surgery	Injury to Surgery, mo	WC	Surgery
1	58/M	Fall from horse during rodeo competition	1 open and 1 arthroscopic subscapularis repair	9.7	No	ACR SCR
2	43/M	Traumatic external rotation of arm while pulling a hose	1 open labral repair, 1 arthroscopic subscapularis repair	11.7	Yes	ACR
3	51/M	15+ Anterior dislocations	None	32	No	ACR
4	60/M	Reaching out with chainsaw and felt a pop	None	6.6	Yes	ACR SCR
5	62/F	Ground-level fall onto shoulder	None	3.8	No	ACR Soft-tissue BT
6	46/M	Ground-level fall while hiking	None	13.6	No	ACR
7	49/M	Shoulder injury while weightlifting	Open labral repair	19.2	No	Open RCR ACR

ACR, anterior capsular reconstruction; BT, biceps tenodesis; F, female; M, male; T, MOI, mechanism of injury; SCR, superior capsular reconstruction; WC, worker's compensation.

Additional subjective questions were used to assess patient functional outcomes. Pain during activities of daily living and work was assessed with the separate questions, "How does pain affect your activities of daily living (ADLs)/work?" with the answer choices: none, mild, moderate, or severe. Painless use of the arm was assessed with the question, "At what level can you use your arm for reasonably strong activities?" with the answer choices: up to waist, up to nipple line, up to neck, up to top of head, and overhead. Finally, subjective assessment of internal rotation function was graded using the question, "How would you rate your ability to wash your back?" with the answer choices: unable, very difficult, somewhat difficult, or normal.

Failure was defined as conversion to RTSA and surgical complications were documented. Outcomes for patients who were converted to RTSA were included pre- and postoperatively.

Given the small number of patients and the heterogeneity of procedures performed within this cohort, the PROs have been detailed on an individual basis. Statistical analysis was performed but was not a focus of the results, recognizing the aforementioned aspects of the patient population.

Statistical Analysis

χ^2 analysis was used for bivariate comparisons. Wilcoxon signed-rank tests were used to detect differences between pre- and postoperative variables. Statistical analyses were performed using SPSS, version 11.0 (SPSS, Chicago, IL).

Results

Between the dates of March 2015 and September 2018, there were 7 (6 male, 1 female) total patients who underwent ACR, with a mean age at the time of surgery of 53 ± 7.3 years old (Fig 1). The demographics of each patient are detailed in Table 1. All patients injured their dominant shoulder. Two of these patients had 3 previous failed SSc repairs, and 5 of the patients presented with chronic SSc tears. Median time from injury to surgery was 13.8 months (range 3.8-32.0 months). Two patients had concomitant SCR for supraspinatus deficiency. A soft-tissue biceps tenodesis at the level of the pectoralis major was performed in 2 patients. Of note, 1 patient progressed to an RTSA at 6.8 months and was removed from further analysis. Minimum 2-year follow-up was obtained in the remaining 6/6 (100%) patients with a mean follow-up of 3.4 years (range 2.0-6.2).

PRO Scores

Given the small number of patients and heterogeneity of procedures in this study population, statistical significance has been provided but is not a central focus for this study. Therefore, the individual preoperative

Table 2. Patient-Reported Outcome Scores

Age/Sex	Surgery	Preoperative ASES	Postoperative ASES	Preoperative SANE	Postoperative SANE	Preoperative QuickDASH	Postoperative QuickDASH	Patient Satisfaction
43/M	ACR	49.9	N/A	49	20	47.7	N/A	10
51/M	ACR	71.6	100	19	99	11.3	0	9
60/M	ACR	78.3	93	65	89	13.6	7	10
	SCR							
62/F	ACR	34.9	100	39	97	61.3	0	10
	BT							
46/M	ACR	74.9	72	64	49	31.8	20	8
	Open RCR							
49/M	ACR	49.9	80	34	74	52.2	20	7
	BT							

ACR, anterior capsular reconstruction; ASES, American Shoulder and Elbow Surgeons score; BT, biceps tenodesis; F, female; M, male; MOI, mechanism of injury; QuickDASH, Quick Disabilities of the Arm, Shoulder and Hand; SANE, Single Assessment Numeric Evaluation; SCR, superior capsular reconstruction; WC, worker's compensation.

and postoperative scores for ASES, SANE, QuickDASH, and postoperative patient satisfaction are detailed in Table 2. Overall, the mean preoperative ASES score was 59.9 (range 49.9-78.3) and postoperatively was 87.9 (range 71.6-100; $P = .08$). In terms of SANE scores, the mean preoperatively was 45 (range 19-65) and postoperatively was 79.8 (range 49-99; $P = .17$). The mean QuickDASH score preoperatively was 36.3 (range 11.3-61.3) and postoperatively was 10.2 (range 0-20.4; $P = .04$). The mean preoperative SF-12 PCS score was 37.2 (range 27.7-51.1) and the postoperative mean score was 52.2 (range 47.6-56.9; $P = .08$). Patient satisfaction was a mean of 9 of 10 (range 7-10).

The subjective questions and percentages that each individual answer choice was selected are detailed in Table 3. Preoperatively, all patients were experiencing some degree of pain with ADLs, and postoperatively all patients reported no pain (60%) or mild pain (40%) with ADLs ($P = .066$). Patients' ability to wash their back was used as a subjective surrogate measure for functional internal rotation. Preoperatively, one-third of patients had difficulty washing their back and two-thirds reported being unable to perform this task. Postoperatively, 1 patient was still unable to wash their back, and the remaining patients reported it as somewhat difficult (40%) or normal (40%; $P = .174$). Finally, regarding the level at which patients reported being able

to use their arm for reasonably strong activities, preoperatively there was a distribution of answers from up to their waist to overhead. Postoperatively, patients reported being able to use their arm for reasonably strong activities to the level of the top of their head (40%) or overhead (60%; $P = .131$).

Revision Surgery and Clinical Failure

There were no intraoperative complications. Regarding clinical failure and revision surgery, 1 patient who received combined ACR and SCR progressed to a RTSA at 6.8 months postoperation. Before conversion to RTSA, the patient had significant weakness and anterior escape with continued deterioration in shoulder function over time. PROs collected before surgery included an SF-12 PCS of 57.2, ASES of 65, SANE of 0, and a QuickDASH of 4.5. Two years after conversion to RTSA, the PROs were an SF-12 PCS of 55.9, ASES of 88, SANE of 89, and a QuickDASH of 11.3. No other patients required revision surgery.

Discussion

The current study demonstrates clinical outcomes in a series of 7 patients following ACR with dermal allograft at a minimum follow-up of 2 years. Although there was an improvement in all PROs from pre- to postoperatively (ASES: +28 points, SANE: +34.8 points, QuickDASH:

Table 3. Pre- to Postoperative Functional Outcomes Expressed in Percent Respondents

	None	Mild	Moderate	Severe	
<i>Pain Effect on ADLs</i>					
<i>Preoperative</i>	0%	33%	33%	33%	
<i>Postoperative</i>	60%	40%	0	0	
<i>Ability to wash back</i>	Unable	Very difficult	Somewhat difficult	Normal	
<i>Preoperative</i>	67%	16%	16%	0%	
<i>Postoperative</i>	20%	0%	40%	40%	
<i>Painless use of arm</i>	Up to waist	Up to nipple line	Up to neck	Up to top of head	Overhead
<i>Preoperative</i>	16%	33%	16%	16%	16%
<i>Postoperative</i>	0%	0%	0%	40%	60%

ADLs, activities of daily living.

–26.1 points, SF-PCS: +15 points), only the QuickDASH improvement reached significance. Additionally, there was a trend toward improved pain during ADLs, ability to wash one's back, and painless use of the of arm after undergoing ACR with a dermal allograft. These results are aligned with the postoperative patient satisfaction of 7 to 10 of 10. It must be noted that these results are in a small cohort of patients with a relatively heterogeneous group in terms of concomitant procedures performed. Therefore, these findings suggest that ACR with a dermal allograft may a viable option for irreparable SSc tears in the short-term, but additional long-term studies and larger study populations are needed.

There is a lack of clinical outcomes of ACR using human dermal allograft in the literature. Zink et al.²² recently reported on a single patient who underwent ACR with dermal allograft for recurrent anterior instability despite previous arthroscopic Bankart repair and Latarjet procedures. At 24 months postoperatively, the patient's shoulder remained stable with no recurrent instances of anterior subluxation or dislocation. Active range of motion achieved forward elevation of 160°, abduction of 180°, external rotation of 35°, and internal rotation to T12. Functional outcome score for ASES, Constant, and SANE were 69.9, 97, and 50%, respectively. The patient reported no pain and was subjectively "very satisfied" with the procedure. Similarly, our cohort trended toward improved pain and functional outcomes, which may be due to the restoration of the anterior checkrein preventing glenohumeral translation.

PMT and LDT have been used in patients with isolated irreparable SSc tears to attempt to improve internal rotational strength and decrease anterior humeral head translation.^{6-8,23} However, despite high patient satisfaction in certain populations, muscle transfers have been criticized for their nonanatomic nature, moderate rate of progression of radiographic cuff arthropathy, and less-predictable outcomes in the setting of concomitant recurrent glenohumeral instability.^{8,10} In a recent systematic review, Luo et al.²⁴ reviewed 9 PMT and 3 LDT studies reporting average postoperative Subjective Shoulder Value scores of 71 for PMT and 70 for LDT. These values are comparable to our cohort's average SANE score of 71, an outcome measure analogous to the Subjective Shoulder Value. Comparison of additional PROs are complicated by their use of the Constant–Murley score rather than the ASES score. However, when each are expressed as a percentage of the best possible score, Constant–Murley scores are 63% and 69% in the PMT and LDT groups, respectively, whereas the mean ASES score in our cohort is 89%.²⁴ Luo et al.²⁴ reported failure rates of 12.9% for PMT and 7.1% for LDT which is comparable to our failure rate of 14.3% (1 patient). While we did not have any surgical complications in our 7-patient cohort,

complication rates of 15.5% for PMT and 15.1% for LDT were documented and notably included neu-rapraxia, tendon re-rupture, and pseudoparalysis.²⁴

In a 2018 case series by Mun et al.,²⁵ clinical outcomes of LDT for irreparable SSc tears demonstrated a mean postoperative ASES score of 70 at a mean follow-up of 2.3 years. While our study did not demonstrate statistical improvement in ASES, the average ASES score improved to 87.9 at a comparable follow-up of 3.4 years.²⁵ Despite continued weakness experienced postoperatively by our cohort, these data indicate that ACR with dermal allograft may lead to better pain and functional outcomes than PMT or LDT in addition to having lower complication rates among patients treated for irreparable SSc tears. Prospective studies to evaluate this operation against PMT and LDT are needed to further compare treatment strategies for this challenging pathology.

Limitations

The limitations of this study include its retrospective design for an uncommon procedure. This resulted in a small patient cohort, leading our analysis to be under-powered to detect a difference in pre- to postoperative scores. Second, the subjective PRO questions regarding ADLs, internal rotation (ability to wash their back), and painless use of the arm with reasonably strong activities are less commonly used outcome measures. Thus, these are limited in their ability to truly extrapolate patients' improvement with ADLs, range of motion, and strength when compared to other procedures. There was also heterogeneity of patient demographics including prior surgeries and concomitant procedures (2/7 had SCR, 2/7 biceps tenodesis, and 1/7 had RCR), adding potential bias to our analysis. Furthermore, although the in-person follow-up in our study was variable and limited for some patients, all patients were assessed at a minimum of 2 years, and a mean of 3.4 years. Longer-term outcomes after ACR with dermal allograft remain unknown. In addition, our practice setting is a sports medicine referral center with a high proportion of active patients with limited comorbidities, potentially limiting the generalizability of our results.

Conclusions

This small cohort of patients had a significant improvement in QuickDASH score, high patient satisfaction, and relatively low conversion rate to RTSA. These clinical outcomes demonstrate that ACR with a dermal allograft may be a viable salvage operation for irreparable SSc tears in the short-term.

References

1. Burkhart SS. Arthroscopic treatment of massive rotator cuff tears. Clinical results and biomechanical rationale. *Clin Orthop Relat Res* 1991;(267):45-56.

2. Deutsch A, Altchek DW, Veltri DM, Potter HG, Warren RF. Traumatic tears of the subscapularis tendon. Clinical diagnosis, magnetic resonance imaging findings, and operative treatment. *Am J Sports Med* 1997;25:13-22.
3. Hamada K, Fukuda H, Mikasa M, Kobayashi Y. Roentgenographic findings in massive rotator cuff tears. A long-term observation. *Clin Orthop Relat Res* 1990;(254):92-96.
4. Elhassan B, Ozbaydar M, Massimini D, Diller D, Higgins L, Warner JJ. Transfer of pectoralis major for the treatment of irreparable tears of subscapularis: Does it work? *J Bone Joint Surg Br* 2008;90:1059-1065.
5. Bartl C, Salzmann GM, Seppel G, et al. Subscapularis function and structural integrity after arthroscopic repair of isolated subscapularis tears. *Am J Sports Med* 2011;39:1255-1262.
6. Jost B, Puskas GJ, Lustenberger A, Gerber C. Outcome of pectoralis major transfer for the treatment of irreparable subscapularis tears. *J Bone Joint Surg Am* 2003;85:1944-1951.
7. Resch H, Povacz P, Ritter E, Matschi W. Transfer of the pectoralis major muscle for the treatment of irreparable rupture of the subscapularis tendon. *J Bone Joint Surg Am* 2000;82:372-382.
8. Shin JJ, Saccomanno MF, Cole BJ, Romeo AA, Nicholson GP, Verma NN. Pectoralis major transfer for treatment of irreparable subscapularis tear: A systematic review. *Knee Surg Sports Traumatol Arthrosc* 2016;24:1951-1960.
9. Wirth MA, Rockwood CA Jr. Operative treatment of irreparable rupture of the subscapularis. *J Bone Joint Surg Am* 1997;79:722-731.
10. Moroder P, Schulz E, Mitterer M, Plachel F, Resch H, Lederer S. Long-term outcome after pectoralis major transfer for irreparable anterosuperior rotator cuff tears. *J Bone Joint Surg Am* 2017;99:239-245.
11. Ruiz-Iban MA, Murillo-Gonzalez JA, Diaz-Heredia J, Avila-Lafuente JL, Cuellar R. Pectoralis major transfer for subscapular deficiency: anatomical study of the relationship between the transferred muscle and the musculocutaneous nerve. *Knee Surg Sports Traumatol Arthrosc* 2013;21:2177-2183.
12. Mihata T. Editorial Commentary: Superior capsular reconstruction-improved superior stability and functional deltoid reverse pseudoparalysis in patients with irreparable rotator cuff tears. *Arthroscopy* 2019;35:29-31.
13. Mihata T, Lee TQ, Watanabe C, et al. Clinical results of arthroscopic superior capsule reconstruction for irreparable rotator cuff tears. *Arthroscopy* 2013;29:459-470.
14. Mihata T, McGarry MH, Pirolo JM, Kinoshita M, Lee TQ. Superior capsule reconstruction to restore superior stability in irreparable rotator cuff tears: A biomechanical cadaveric study. *Am J Sports Med* 2012;40:2248-2255.
15. Pogorzelski J, Hussain ZB, Lebus GF, Fritz EM, Millett PJ. Anterior capsular reconstruction for irreparable subscapularis tears. *Arthrosc Tech* 2017;6:e951-e958.
16. Mihata T, McGarry MH, Kahn T, Goldberg I, Neo M, Lee TQ. Biomechanical role of capsular continuity in superior capsule reconstruction for irreparable tears of the supraspinatus tendon. *Am J Sports Med* 2016;44:1423-1430.
17. Rogers JP, Kwapisz A, Tokish JM. Anterior capsule reconstruction for irreparable subscapularis tears. *Arthrosc Tech* 2017;6:e2241-e2247.
18. Dewing CB, Horan MP, Millett PJ. Two-year outcomes of open shoulder anterior capsular reconstruction for instability from severe capsular deficiency. *Arthroscopy* 2012;28:43-51.
19. Komperda KW, Adamson GJ, Itami Y, et al. Anterior capsule reconstruction versus pectoralis major transfer for irreparable subscapularis tears involving the anterior capsule: A comparative biomechanical cadaveric study. *Arthroscopy* 2019;35:3002-3008.
20. Adams CR, Frank RM, Denard PJ, Millett PJ, Hartzler RU, Romeo AA. Arthroscopic superior capsular reconstruction for treatment of massive irreparable rotator cuff tears: An update of the technique for 2020. *JBJS Essent Surg Tech* 2020;10:e19.00014.
21. Petri M, Greenspoon JA, Millett PJ. Arthroscopic superior capsule reconstruction for irreparable rotator cuff tears. *Arthrosc Tech* 2015;4:e751-e755.
22. Zink TJJ, Myers DM, Taylor BC, Wiseman SP, Long NK. Anterior capsular reconstruction of the shoulder for chronic instability using a dermal allograft. *Tech Shoulder Elbow Surg* 2019;20:92-95.
23. Burnier M, Lafosse T. Pectoralis major and anterior latissimus dorsi transfer for subscapularis tears. *Curr Rev Musculoskelet Med* 2020;13:725-733.
24. Luo Z, Lin J, Sun Y, Zhu K, Wang C, Chen J. Outcome comparison of latissimus dorsi transfer and pectoralis major transfer for irreparable subscapularis tendon tear: A systematic review [published online June 17, 2021]. *Am J Sports Med*. doi:10.1177/03635465211018216.
25. Mun SW, Kim JY, Yi SH, Baek CH. Latissimus dorsi transfer for irreparable subscapularis tendon tears. *J Shoulder Elbow Surg* 2018;27:1057-1064.