

Rehabilitation of the Arthrofibrotic Knee

Peter J. Millett, MD, MSc, Burt Johnson, ATC, Jeff Carlson, PT,
Sumant Krishnan, MD, and J. Richard Steadman, MD

Abstract

This paper describes the postoperative rehabilitation of the arthrofibrotic knee, with specific emphasis on modern rehabilitation techniques. The significance of prevention and early recognition is discussed. The importance of early motion and patellar mobility is emphasized and specific exercises to prevent and treat stiffness are described. Continuous passive motion, bracing, and exercise—on the stationary bicycle, on the treadmill, and in water—are adjuncts in the program. Strengthening is added when motion is re-established and there is no swelling or pain. Sport-specific activities are added if progress is satisfactory and motion is maintained. If pain, swelling, or stiffness develops, exercises should be discontinued. Modalities such as cryotherapy, ultrasound, electrical stimulation, rest, and manipulation can be used judiciously. Anti-inflammatory and analgesic medications should be used to prevent inflammation, to control pain, and to allow more aggressive rehabilitative exercises.

Rehabilitation of the arthrofibrotic knee is among the toughest challenges in orthopedics. Care must be coordinated appropriately to achieve optimum results. Arthrofibrosis is a process that occurs when diffuse scar tissue or fibrous adhesions form within or about a joint.^{1,3} In the knee, such periarticular scarring can occur as a localized or a global process that can restrict flexion, extension, or patellofemoral mobility. Fibrosis of the suprapatellar pouch, as well as the medial and lateral gutters, is typical. The scarring may also occur in the anterior com-

partment and frequently in the posteromedial and posterolateral joint capsule. A thickened, fibrotic capsule is characteristic and, in its most severe forms, can completely prohibit joint motion.

Sprague and colleagues⁴ were among the first to describe the phenomenon of arthrofibrosis in the knee. Since that time, several reports⁵⁻⁷ have discussed the clinical outcomes after both arthroscopic and open surgical treatment. Millett and colleagues⁷ recently reported good outcomes after open surgery and aggressive rehabilitation in a series of patients with profound motion loss of the knee secondary to advanced arthrofibrosis.

Arthrofibrosis can be caused by a variety of factors, such as prolonged immobilization, infection, or graft malposition after ligament reconstruction.^{1,8} Historically, anterior cruciate ligament (ACL) reconstruction has been the major culprit, although there are many other situations in which arthrofibrosis may occur. Fortunately, a better understanding of the causes has led to improved prevention strategies and earlier recognition, which has resulted in a decrease in both the incidence and the sequelae of arthrofibrosis. Because arthrofibrosis can be so difficult to treat, prevention is clearly the best approach. Appropriate surgical indications, surgical techniques, and rehabilitation can decrease the incidence. These topics are discussed elsewhere in the literature.^{2,3}

When arthrofibrosis does develop, it needs to be recognized early and treated appropriately.^{5,6} Physical therapy and rehabilitation are essential to a good outcome. Currently, there are no reports that deal specifically with the rehabilitation of the arthrofibrotic knee. Therefore, the purpose of this paper is to discuss this topic, emphasizing modern rehabilitative techniques.

Initial Management

Prevention and Early Detection

Primary prevention of arthrofibrosis is the best management strategy. For knees with ACL injuries, arthrofibrosis can be prevented by avoiding surgery when the knee lacks full motion, by using proper surgical technique with meticulous graft placement and avoidance of bleeding, and by instituting an early and appropriate rehabilitation program.^{2,3}

Dr. Millett is an Orthopedic Surgeon at Harvard Shoulder Service/Sports Medicine, Harvard Medical School, and Brigham and Women's Hospital, Boston, Massachusetts.

Mr. Johnson is an Athletic Trainer, Vail, Colorado.

Mr. Carlson is a Physical Therapist, Vail, Colorado.

Dr. Krishnan is an Orthopedic Surgeon, W. B. Carrell Memorial Clinic, Dallas, Texas.

Dr. Steadman is an Orthopedic Surgeon, Steadman Hawkins Clinic, Vail, Colorado.

Address correspondence to Peter J. Millett, MD, MSc, Harvard Medical School, Brigham and Women's Hospital, 75 Francis Street, Boston, MA 02115 (e-mail, pmillett@partners.org); phone, (617) 732-5793.

When motion problems do occur, early detection allows for the prompt intervention that can decrease long-term morbidity. In the immediate postoperative period after any knee surgery, but particularly after ligament reconstruction, monitoring knee motion is critical. We systematically assess both flexion and extension and compare motion with that of the uninvolved, contralateral side. By serially measuring prone heel hangs, or having a 2-week goal of full extension and 120° of flexion, we can detect motion problems early and modify our rehabilitation program accordingly. In patients with arthrofibrotic knees who are treated surgically, we also carefully monitor knee motion and its progression. In this way, we can alter our physical therapy, bracing, and other modalities as needed.

Patellar mobility is important for proper knee function, and loss of this mobility is invariably involved in arthrofibrosis. We always examine the mobility of the entire extensor mechanism—the patella, the patella tendon, and the quadriceps tendon. Decreased mobility, in either the medial-lateral direction or the superior-inferior direction, can lead to patellofemoral overload with pain and poor outcomes. Scarring and adhesions in the anterior interval (pretibial recess) or suprapatellar pouch will increase patellofemoral contact forces, alter patellofemoral tracking, and cause pain.^{9,10}

When motion loss is detected, a careful systematic evaluation should help establish the correct cause, allowing for targeted treatment. Magnetic resonance imaging (MRI) may assist in evaluating the soft tissues; often, an ACL nodule, fat pad scarring, or adhesions can be noted. Suprapatellar scarring can be felt on exam and seen on MRI as the suprapatellar pouch becomes compartmentalized and abnormally shortened. This leads to a decreased excursion of the extensor mechanism and patellar entrapment. Patellar height should also be assessed. By carefully measuring patellar height both on exam and with radiographs, patella baja may be detected.

Other potential causes of motion loss after reconstructive knee surgery include an ACL nodule or reflex sympathetic dystrophy. By palpation, the examiner may be able to detect the subtle crepitus or “clunk” of an ACL nodule.¹¹ The clinician should be alert for the possibility of reflex sympathetic dystrophy in patients who develop pain out of proportion to the diagnostic maneuvers, allodynia, or trophic or sudomotor changes.¹²

Early recognition and intervention are essential to prevent the sequelae of arthrofibrosis, which include patella baja and progressive joint degeneration. Noyes and colleagues¹³ found that by placing patients with early motion problems into an aggressive rehabilitation program that included serial casting and aggressive motion exercises, outcomes could be improved.

Surgical Management

Arthroscopic or Open?

A detailed description of the specific techniques of surgical treatment for arthrofibrosis can be found elsewhere in the literature.^{3,6,7,14-16} Briefly, to outline our approach, we treat the majority of patients who develop arthrofibrosis with an arthroscopic procedure, distending the capsule and releasing scar tissue, adhesions, and other surgically correctable lesions.^{15,16} Particular attention is paid to mobilizing the extensor mechanism by re-establishing the suprapatellar pouch, releasing the medial and lateral retinacula, maintaining the pretibial recess, and inspecting the notch for impingement. Restoring mobility to the extensor mechanism is key to decreasing anterior knee pain and to restoring knee function. In certain instances in which the motion loss is severe, open releases may be necessary to accomplish this goal.^{7,15} A systematic 9-step evaluation to the surgical management of the arthrofibrotic knee should be undertaken (Table).³ Whenever surgery of the arthrofibrotic knee is undertaken, an appropriate rehabilitation and pain management protocol must follow in order to achieve optimal results.

The Role of Manipulation

In certain instances, such as in those patients with relatively mild involvement, a nonoperative approach can be initiated. This consists of physical therapy and possibly a manipulation of the knee under anesthesia. Although manipulation under anesthesia can be used to improve motion in the arthrofibrotic knee,¹³ we generally recommend an arthroscopic release to liberate the tight capsular tissues and to remove adhesions.¹⁷ We believe surgical intervention can address the offending contracted tissues more precisely, helping to avoid collateral damage and minimize bleeding. To our knowledge, there is no data that

TABLE. 9-STEP SURGICAL EVALUATION OF THE ARTHROFIBROTIC KNEE

1. Suprapatellar pouch—free adhesions/mobilize
2. Medial gutter—free adhesions/mobilize
3. Lateral gutter—free adhesions/mobilize
4. Infrapatellar fat pad/pretibial recess—re-establish normal anterior interval of the knee
5. Lateral retinaculum—perform lateral retinacular release if tight or scarred
6. Medial retinaculum—perform medial retinacular release if tight or scarred
7. Intercondylar notch—debride scar tissue; in severe cases release ACL and/or PCL
8. Tibial insertion of posterior capsule—inspect capsular recess, medial and, if necessary, lateral capsulotomies
9. Femoral insertion of posterior capsule—release if necessary

specifically addresses the timeframe during which a manipulation would be most effective. Our experience treating patients with postoperative or posttraumatic arthrofibrosis indicates that immature scar tissue can be successfully broken up by manipulation but that mature scar tissue cannot. Exactly when scar tissue becomes mature is a subject of contention; we estimate the timeframe to be 3 to 4 months.

Because of the unpredictability and danger of manipulation, we rarely, if ever, perform an isolated manipulation in a chronically stiff knee. Instead, we prefer a more controlled surgical release, and this can usually be accomplished arthroscopically. Forceful manipulation of the stiff knee can create excessive joint compression leading to articular cartilage damage or even fracture.

Other authors, however, have reported manipulation to be a successful and useful adjunct. Dodds and colleagues¹⁸ reported the results of manipulations of 42 knees with persistent flexion or extension deficits after intra-articular ACL reconstructions. At manipulation, average flexion increased from 95° to 136°, and average extension from 11° to 3°. At final follow-up, average flexion was 127° and average extension was 4°. Final range of motion (ROM) was not affected by time to manipulation, severity of flexion deficit, or concomitant arthroscopic débridement of adhesions. However, knees with pre-manipulation extension deficits of greater than or equal to 15° achieved significantly less final extension than knees with lesser pre-manipulation deficits. The authors concluded that manipulations were a safe and effective method for improving both flexion and extension in knees that had restricted motion after ACL reconstructions.

Our use of manipulation is summarized in the box below.

OUR APPROACH TO USING MANIPULATION SUMMARIZED

We view manipulation as an option that works best for flexion deficits in milder and early cases of arthrofibrosis, when the scar tissue is relatively immature. Generally, we prefer to avoid manipulation as a first-line treatment and instead advocate arthroscopic surgical releases. Focal lesions, such as ACL nodules, malpositioned grafts, or dense adhesions, respond better to surgery. When manipulation is chosen, it should be performed gently so as not to overload the chondral surfaces and cause further degeneration. With forceful manipulation, one also must be careful to avoid rupturing the quadriceps or tearing the muscle, which can lead to myositis. The optimum timeframe for performing a manipulation is unclear, but we do not recommend manipulation in long-standing or chronic cases of arthrofibrosis.

Analgesia and Anti-inflammatory Medications

After surgery, pain control is essential, as it allows rehabilitation to begin without undue discomfort. Analgesia may be achieved with oral or injectable opioids, but in many cases we prefer to utilize indwelling epidural catheters for a few days postoperatively.⁷ This permits total analgesia and allows for more aggressive motion exercises. Collaborating with pain management specialists or anesthesiologists is often helpful. We also advocate the use of anti-inflammatory medications in conjunction with epidural analgesia in the immediate postoperative period. We routinely use nonsteroidal anti-inflammatory drugs and, in severe cases, may consider a short course of intravenous corticosteroids.⁷

Rehabilitation

Early Motion

Early motion is key for the successful rehabilitation of the postoperative arthrofibrotic knee. We have known for some time that prolonged immobilization has detrimental effects on periarticular cartilage, bone, and soft tissues and can lead to motion loss.⁸ Therefore, modern rehabilitation programs have stressed early motion and weight-bearing, resulting in fewer motion problems and better outcomes.^{19,20} Several researchers^{19,21} have shown that patients recovering from ACL reconstruction who participated in early motion and weight-bearing had a decreased incidence of motion loss and regained extension more quickly. We also advocate early motion after surgery for knee arthrofibrosis. Poor rehabilitation, whether due to lack of motivation or lack of instruction, will adversely affect the ultimate outcome.

While knee ROM varies from individual to individual, most normal knees have some degree of hyperextension (average, 5° in males, 6° in females).^{22,23} Hyperextension not only allows the normal "screw home" mechanism to occur but also permits the quadriceps to relax during stance phase. Normal knee flexion is approximately 140° in men and 143° in women,²² and while small flexion deficits typically do not alter gait, most readily notice a unilateral or asymmetric loss of flexion, particularly those involved in running or jumping sports.

Our motion goals are determined at the conclusion of surgery for knee arthrofibrosis. Although restoring full motion is the ultimate goal, avoiding damage to the quadriceps and patellar tendons is also crucial. Passive ROM can be done by wall slides, by seated flexion and extension exercises, by prone flexion exercises, or by heel slides. Hamstring and calf muscle strengthening is also performed to stretch the posterior capsule and soft tissues. To encourage knee

extension, we instruct patients to prop up their heels when resting supine or to hang their legs off the table when resting prone. Although full motion is the goal, excessive or overly aggressive passive motion can trigger an inflammatory response that actually increases pain and leads to new adhesion formation.

Based on our experience, we recommend passive ROM exercises 3 to 4 times daily, for approximately 15 to 20 minutes per session. We use the contralateral limb as a reference and aim to achieve full extension by 2 weeks. Passive ROM exercises should be performed in conjunction with muscle re-education techniques for the quadriceps muscle group. Straight leg raises and isometric quadriceps exercises are also utilized.

Patellar mobility may be the most important aspect of rehabilitation (Figure 1). In a cadaveric study, Ahmad and coworkers¹⁰ showed an increase in patellofemoral contact pressure in knees with quadriceps or patellar tendon adhesions. Thus, patellar mobility exercises are performed in all planes of motion (mediolateral and superoinferior), 5 to 6 times daily for 5 to 10 minutes each session. Manual mobilization by a therapist, friend, or family member is more effective than patient-directed exercises, as it is easier for the patient to relax the quadriceps. Mobilizing the soft tissues of both the quadriceps and patellar tendons is critical to restoring normal extensor mobility and ultimately to restoring normal knee function.

Adjuncts

Continuous Passive Motion

The benefits of continuous passive motion (CPM) on cartilage metabolism have been known for some time.²⁴⁻²⁶ Therefore, we routinely use CPM in the rehabilitation of the arthrofibrotic knee. CPM is not only beneficial to the cartilage but also keeps the soft tissues supple and loose. The clinician must remember, however, that CPM promotes flexion but is less effective in promoting extension. Patients are placed in a CPM machine immediately after surgery and are sent home with a machine for the first 2 weeks postoperatively (to use for approximately 6 to 8 hours daily).

Bracing

When bracing is needed to maintain extension, the knee should be splinted in full extension. Terminal knee extension restores normal mechanics and function, as small losses of extension lead to increased quadriceps activity and significantly increased patellofemoral contact stresses. When extension bracing is necessary, we advocate alternating between periods of bracing and periods of motion. Passive motion, both manually with the therapist and pas-

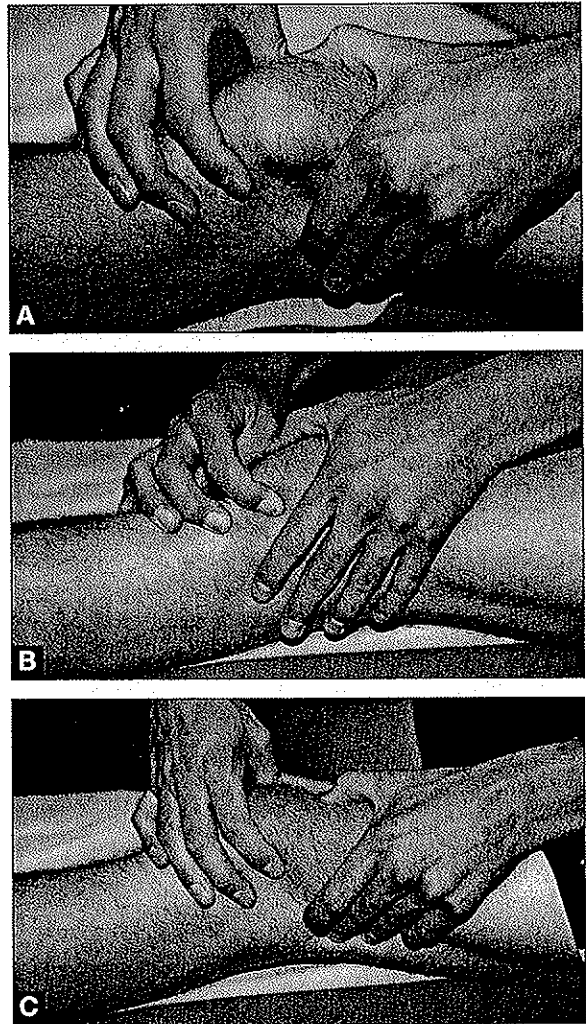


Figure 1. Extensor mechanism mobilizations. These exercises are performed 5 to 6 times daily for 5 to 10 minutes each session and are critical to restoring normal extensor function. Manual therapy by a therapist, friend, or family member permits better quadriceps relaxation and more effective mobilization. (A) The patella is mobilized in all planes, medio-lateral and supero-infero, as well as tilted. (B) The patellar tendon is mobilized medially and laterally. (C) The quadriceps tendon is manually mobilized.

sively with a CPM machine, will help to prevent new adhesions from forming.^{7,21} There are no specific reports on the effects of bracing or brace position on outcome; however, one retrospective analysis of consecutive patients who underwent ACL reconstruction reported a 23% incidence of motion problems when patients had their leg braced at 45° and immobilized for 1 week, compared with only a 3% incidence of motion problems when patients were braced in full extension and had motion started within 24 hours.²¹

When a brace is needed to maintain extension, a variety of options exist, such as dynamic splints, custom drop-lock orthoses,⁷ extension casts, or custom braces. We currently use the JAS® brace (Joint Active Systems, Effingham, IL), which is a static progressive

splint that applies a series of increasing incremental displacements over a constant period of time.²⁷ This method theoretically causes plastic deformation of the soft tissues by the displacement, which the brace then maintains. The brace is used 2 to 3 times daily for 30 minutes, and the patient is instructed to increase the stretch every 5 minutes.

While many brace options exist, they nevertheless must be used properly. Improper use can cause excess compressive loads on the chondral surfaces, leading to unnecessary cartilage wear and joint degradation.

Stationary Bicycle

The stationary bicycle is utilized for restoring normal joint kinematics, soft tissue mobility, and muscle re-education. The bicycle has classically been used to increase ROM. We have also found the repetitive motion of the bike helpful to loosen and mobilize the soft tissues. We set the seat height so that patients have approximately 10° of knee flexion at the bottom of the pedal stroke.

While the bicycle may be introduced in the first postoperative week, often we delay its use until postoperative day 14 to decrease the incidence of swelling or joint irritation. In most cases, patients spin without any resistance for the first 6 weeks. After 6 weeks, patients are permitted to increase the revolutions per minute and to add resistance, provided there is no loss of motion, sign of heat, or swelling. At approximately 3 months postoperatively, advanced speed intervals can be utilized for low-load strengthening.

Treadmill

The treadmill can be used to improve cardiovascular and muscle endurance and is introduced as early as 1 week postoperatively. A 7% to 12% incline minimizes patellofemoral contact stresses and is beneficial to the soft tissues and muscles of the knee.²⁸ At 6 weeks, backward treadmill walking can be added. This is an excellent exercise for quadriceps conditioning that places relatively low stress on the patellofemoral joint. Time spent walking backwards can be increased every 2 weeks as tolerated by the patient.

Aquatherapy

Deep water jogging is begun when the surgical incisions have healed. From weeks 2 to 6, deep water running in a fashion that mimics jogging is done 2 to 3 days per week, for 20 to 30 minutes per session. At 6 to 8 weeks postoperatively, aquatherapy can be advanced by the addition of training fins that increase resistance. The patient performs a 'flutter kick' and uses a kickboard to help isolate the lower body. We have found the flutter kick to be particularly useful and safe for the patellofemoral joint.






Figure 2. Elastic resistance exercises. An elastic resistance cord is used to perform each of these exercises. The patients initially start with high repetitions and low resistance to build endurance. Over time, resistance can be increased by altering the cord. **(A)** The double knee bend, a closed-chain exercise that strengthens both the quadriceps and hamstring muscle groups. Notice that the patient does not bend more than 30°-40° to decrease patellofemoral contact stresses. **(B)** The "carpet drag," which strengthens the hamstring muscles. **(C)** The seated leg press, which strengthens the quadriceps muscle group.

Elastic Resistance Strengthening

The first phase of strengthening is started with elastic resistance exercises, concentrating on high repetitions with moderate resistance.²⁹ Our goal is maintaining mobility while regaining strength and endurance. The first 3 exercises are the double knee bend, the "carpet drag," and the leg press (Figure 2). More advanced exercises such as forward or backward jogging, single knee bends, and side-to-side lateral agility can be added as tolerated. If proper knee mobility is maintained, advanced strength exercises are performed to increase the load on the muscle. Any exercises that cause stiffness or swelling in the knee joint or extensor mechanism are immediately discontinued.

TYPICAL POSTOPERATIVE PROTOCOL

Our typical postoperative protocol is multifaceted:

- Weight-bearing as tolerated.
- Continuous passive motion, -5° hyperextension to 90° increase as tolerated.
- Dynamic splint for 1 hour after physical therapy and at night.
- Full passive, active, and active-assisted ROM.
- Patella and extensor mobilizations.
- Exercise bike—both legs start within first week as tolerated.
- Treadmill—2 weeks postoperatively.
- Sport cord—wait until 2 weeks postoperatively.
- Water exercises when incisions are healed.
- Daily outpatient physical therapy for 1 week.
- Continued outpatient physical therapy 6 times per week for 6 to 8 weeks.

Before surgery, we carefully document the motion loss and determine the specific cause. In the operative suite prior to arthroscopy, the knee capsule is distended with saline to stretch the thickened capsule and to disrupt the intra-articular adhesions.¹⁸ Subsequently, the arthroscope is inserted; the 9-step evaluation is performed (Table, page 532), and appropriate surgical treatment is performed, as described elsewhere.¹⁵

After surgery, patients are typically hospitalized for 24 to 48 hours, but in severe cases may remain hospitalized for 4 to 6 days. When there is global arthrofibrotic involvement of the knee or when extensive surgical releases are performed, we use indwelling epidural catheters for the first 48 to 72 hours to provide pain relief. Analgesia of the affected extremity is extremely important as it allows us to mobilize the limb without undue discomfort to the patient. A nonsteroidal anti-inflammatory medication, such as ketorolac, is also administered for both its anti-inflammatory and analgesic effects.

The patient is immediately placed in a CPM machine and continues to use one for 6 to 8 hours per day to maintain motion. Range-of-motion activities are alternated with dynamic extension bracing in an orthosis, such as the JAS brace. This brace was designed to maintain knee extension while minimizing joint compressive loads. Whenever extension bracing is used and the limb is immobilized, we add pneumatic compressive foot pumps and anti-embolic stockings to prevent venous thrombosis. Partial weight-bearing is allowed as tolerated; crutches are usually recommended for the first week. A compressive dressing is applied to limit swelling and prevent effusions, which inhibit quadriceps muscle activity.²⁹ Cryotherapy is used liberally for its analgesic and vasoconstrictive benefits.

On the first postoperative day, we encourage patients to spin on a stationary bike without resistance. In addition to a self-directed patella and patellar tendon mobilization program that begins immediately, the patients work with a physical therapist 2 to 3 times daily for passive ROM exercises and patellar mobilizations. Straight-leg raises and isometric quadriceps exercises are initiated early.

At 2 weeks or when the surgical incisions have healed, aquatherapy is initiated. A strengthening program is gradually introduced at 4 to 6 weeks, if motion has been maintained. We find the use of the uphill treadmill particularly helpful during this phase. The height of the treadmill is gradually increased. Once the patient is comfortable, strengthening is best achieved with a 7% to 12% grade on the treadmill. Some patients also find elliptical exercise machines helpful. Stairclimbers generally place too much stress on the knee and are avoided until the knee is near full recovery. Around 3 months postoperatively, elastic resistance exercises and sport-specific activities are added if progress is satisfactory and motion is maintained.

Modalities

Cryotherapy

Cryotherapy is a simple and successful means to control swelling, pain, and inflammation.³⁰⁻³² Ice can be used liberally after each exercise session and as needed when not exercising. Our protocol is 20 minutes "on," with at least 1 hour between sessions.

Ultrasound

Ultrasound has been shown to increase the elasticity of soft tissues,^{33,34} which may be beneficial in suppressing scar tissue formation. This can be used as early as 2 weeks postoperatively.

Electrical Stimulation

Electrical stimulation can be used for swelling reduction and muscle re-education.³⁵⁻³⁸ In severe cases of

arthrofibrosis, the quadriceps muscle may be shut down due to excessive scarring or swelling. An external electrical stimulation device may be indicated in such instances. A variety of currents can achieve an adequate muscle contraction.

When Motion May Do Harm

In certain instances, rest and observation are the best methods of treatment for the stiff knee.³

The "Hot Knee"

A knee that is acutely inflamed with soft-tissue swelling and loss of motion, the so-called "hot knee," should not be treated forcefully. Rest, ice, and anti-inflammatory agents are necessary to avoid further inflammation and motion loss. This can occur after any surgical or traumatic insult to the knee.

In such knees, tissue injury has led to the release of cytokines and growth factors that result in inflammation, scar tissue formation, fibrosis, and joint contractures. Active manipulation at this time will only accelerate the process. When a "hot knee" develops, only gentle active and passive ROM exercises are permitted. Forceful extension and flexion are avoided altogether.

Reflex Sympathetic Dystrophy

Knees that have developed or are in the process of developing reflex sympathetic dystrophy (RSD) should also be handled with care. Unlike the "hot knee," which is caused by inflammation, RSD has a poorly defined neurogenic cause. Pain out of proportion to the stimulus, allodynia, and skin changes are common features. RSD can cause stiffness from swelling, which is usually extra-articular or from increased sensitivity to pain. Gentle and appropriate rehabilitation can hasten recovery while overzealous or aggressive treatment may only exacerbate the underlying complex regional pain syndrome. Recognition is key. The management of such knees, however, is beyond the scope of this paper.

Myositis

Another uncommon cause of motion loss is myositis, which can be severely disabling owing to pain and stiffness. In suspected cases, radiographs should be carefully reviewed for soft tissue calcifications, which may be seen as early as 6 weeks after injury but often require 3 months or more to develop. If calcifications are noted, aggressive attempts at restoring motion should be avoided. With time, the soft tissue insult will clear and motion will return. However, pain can persist over the calcified area for months. On occasion, extensive periarticular calcifications can result in severe loss of motion, and surgical excision and release may be indicated.

Summary

Rehabilitation of the arthrofibrotic knee is among the most difficult challenges in orthopedics. Physical therapy is usually a first-line approach to any postoperative problem with motion about the knee and is essential after surgical treatment of the arthrofibrotic knee. In this paper, we have outlined our standard protocol for the postoperative rehabilitation of the arthrofibrotic knee.

The first step is to recognize and diagnose arthrofibrosis accurately. Then, a rational approach that focuses on maintaining and regaining motion can be implemented. In the early postoperative period we stress ROM exercises and patellar mobility. We utilize the CPM machine, gentle manipulation, and the stationary bike as rehabilitative aids. We avoid stimulating inflammation and are careful to rest the "hot

knee." If increased swelling, inflammation, or pain occur, it is best to rest the knee and allow this phase to pass. Ice and anti-inflammatory agents are used liberally to prevent inflammation and to provide analgesia. Once motion is established, we slowly begin strengthening with elastic resistance exercises, aqua jogging, and the treadmill. Eventually we allow sport-specific rehabilitation and a return to full activities.

Acknowledgments

The authors wish to thank Lottie Applewhite for her help in preparing this manuscript.

References

1. Petsche TS, Hutchinson MR. Loss of extension after reconstruction of the anterior cruciate ligament. *J Am Acad Orthop Surg.* 1999;7:119-127.
2. Millett PJ, Wickiewicz TL, Warren RF. Motion loss after ligament injuries to the knee. Part I: causes. *Am J Sports Med.* 2001;29(5):664-675.
3. Millett PJ, Wickiewicz TL, Warren RF. Motion loss after ligament injuries to the knee. Part II: prevention and treatment. *Am J Sports Med.* 2001;29(6):822-828.
4. Sprague NF, O'Connor RL, Fox JM. Arthroscopic treatment of postoperative knee arthrofibrosis. *Clin Orthop.* 1982;166:165-172.
5. Cosgarea AJ, DeHaven KE, Lovelock JE. The surgical treatment of arthrofibrosis of the knee. *Am J Sports Med.* 1994;22:184-191.
6. Richmond JC, al Assal M. Arthroscopic management of arthrofibrosis of the knee, including infrapatellar contraction syndrome. *Arthroscopy.* 1991;7:144-147.
7. Millett PJ, Williams RJ, 3rd, Wickiewicz TL. Open debridement and soft tissue release as a salvage procedure for the severely arthrofibrotic knee. *Am J Sports Med.* 1999;27:552-561.
8. Enneking WF, Horowitz M. The intra-articular effects of immobilization on the human knee. *J Bone Joint Surg Am.* 1972;54:973-985.
9. Perry J, Antonelli D, Ford W. Analysis of knee-joint forces during flexed-stance. *J Bone Joint Surg Am.* 1975;57:961-967.
10. Ahmad CS, Kwak SD, Ateshian GA, Warden WH, Steadman JR, Mow VC. Effects of patellar tendon adhesion to the anterior tibia on knee mechanics. *Am J Sports Med.* 1998;26:715-724.
11. Marzo JM, Bowen MK, Warren RF, Wickiewicz TL, Altchek DW. Intraarticular fibrous nodule as a cause of loss of extension following anterior cruciate ligament reconstruction. *Arthroscopy.* 1992;8:10-18.
12. O'Brien SJ, Ngeow J, Gibney MA, Warren RF, Fealy S. Reflex sympathetic dystrophy of the knee. Causes, diagnosis, and treatment. *Am J Sports Med.* 1995;23:655-659.
13. Noyes FR, Mangine RE, Barber SD. The early treatment of motion complications after reconstruction of the anterior cruciate ligament. *Clin Orthop.* 1992;277:217-228.
14. Parisien JS. The role of arthroscopy in the treatment of postoperative fibroarthrosis of the knee joint. *Clin Orthop.* 1988;185-92.
15. Steadman JR, Burns TP, Pelozo J. Surgical treatment of arthrofibrosis of the knee. *J Orthop Tech.* 1993;1:119-127.
16. Millett PJ, Steadman JR. The role of capsular distention in the arthroscopic management of arthrofibrosis of the knee: a technical consideration. *Arthroscopy.* 2001;17(7):E31.
17. Shelbourne KD, Johnson GE. Outpatient surgical management of arthrofibrosis after anterior cruciate ligament surgery. *Am J Sports Med.* 1994;22:192-197.
18. Dodds JA, Keene JS, Graf BK, Lange RH. Results of knee manipulations after anterior cruciate ligament reconstructions. *Am J Sports Med.* 1991;19:283-287.
19. Shelbourne KD, Wilckens JH, Mollabashy A, DeCarlo M. Arthrofibrosis in acute anterior cruciate ligament reconstruction. The effect of timing of reconstruction and rehabilitation. *Am J Sports Med.* 1991;19:332-336.
20. Noyes FR, Barber-Westin SD. Reconstruction of the anterior and posterior cruciate ligaments after knee dislocation. Use of early protected postoperative motion to decrease arthrofibrosis. *Am J Sports Med.* 1997;25:769-778.
21. Cosgarea AJ, Sebastianelli WJ, DeHaven KE. Prevention of arthrofibrosis after anterior cruciate ligament reconstruction using the central third patellar tendon autograft. *Am J Sports Med.* 1995;23:87-92.

22. DeCarlo MS, Sell K. Normative data for range of motion and single leg hop in high school athletes. *J Sports Rehabilitation*. 1997;6:246-255.
23. Shelbourne KD, Rask BP. Controversies with anterior cruciate ligament surgery and rehabilitation. *Am J Knee Surg*. 1998;11:136-143.
24. Salter RB, Simmonds DF, Malcolm BW, Rumble EJ, MacMichael D, Clements ND. The biological effect of continuous passive motion on the healing of full-thickness defects in articular cartilage. An experimental investigation in the rabbit. *J Bone Joint Surg Am*. 1980;62:1232-1251.
25. Ulrich C, Burri C, Worsdorfer O. Continuous passive motion after knee-joint arthrolysis under catheter peridural anesthesia. *Arch Orthop Trauma Surg*. 1986;104:346-351.
26. O'Driscoll SW, Giori NJ. Continuous passive motion (CPM): theory and principles of clinical application. *J Rehabil Res Dev*. 2000;37:179-188.
27. Jansen CM, Windau JE, Bonutti PM, Brillhart MV. Treatment of a knee contracture using a knee orthosis incorporating stress-relaxation techniques. *Phys Ther*. 1996;76:182-186.
28. Lange GW, Hintermeister RA, Schlegel T, Dillman CJ, Steadman JR. Electromyographic and kinematic analysis of graded treadmill walking and the implications for knee rehabilitation. *J Orthop Sports Phys Ther*. 1996;23:294-301.
29. Hintermeister RA, Bey MJ, Lange GW, Steadman JR, Dillman CJ. Quantification of elastic resistance knee rehabilitation exercises. *J Orthop Sports Phys Ther*. 1998;28:40-50.
30. Zaffagnini S, Iacono F, Petitto A, Loreti I, Fu FH, Marcacci M. Cryo/Cuff use after arthroscopic surgery: effect on knee joint temperature. *Am J Knee Surg*. 1998;11:203-207.
31. Noyes FR, Berrios-Torres S, Barber-Westin SD, Heckmann TP. Prevention of permanent arthrofibrosis after anterior cruciate ligament reconstruction alone or combined with associated procedures: a prospective study in 443 knees. *Knee Surg Sports Traumatol Arthrosc*. 2000;8:196-206.
32. Martin SS, Spindler KP, Tarter JW, Detwiler K, Petersen HA. Cryotherapy: an effective modality for decreasing intraarticular temperature after knee arthroscopy. *Am J Sports Med*. 2001;29:288-291.
33. Deyle GD, Henderson NE, Matekel RL, Ryder MG, Garber MB, Allison SC. Effectiveness of manual physical therapy and exercise in osteoarthritis of the knee. A randomized, controlled trial. *Ann Intern Med*. 2000;132:173-181.
34. Reed BV, Ashikaga T, Fleming BC, Zimny NJ. Effects of ultrasound and stretch on knee ligament extensibility. *J Orthop Sports Phys Ther*. 2000;30:341-347.
35. Delitto A, Rose SJ, McKowen JM, Lehman RC, Thomas JA, Shively RA. Electrical stimulation versus voluntary exercise in strengthening thigh musculature after anterior cruciate ligament surgery. *Phys Ther*. 1988;68:660-663.
36. Kannus P, Jarvinen M. Nonoperative treatment of acute knee ligament injuries. A review with special reference to indications and methods. *Sports Med*. 1990;9:244-260.
37. Paternostro-Sluga T, Fialka C, Alacamlioglu Y, Saradeth T, Fialka-Moser V. Neuromuscular electrical stimulation after anterior cruciate ligament surgery. *Clin Orthop*. 1999;166-175.
38. Snyder-Mackler L, Delitto A, Stralka SW, Bailey SL. Use of electrical stimulation to enhance recovery of quadriceps femoris muscle force production in patients following anterior cruciate ligament reconstruction. *Phys Ther*. 1994;74:901-907.
39. Torry MR, Decker MJ, Viola RW, O'Connor DD, Steadman JR. Intra-articular knee joint effusion induces quadriceps avoidance gait patterns. *Clin Biomech (Bristol, Avon)*. 2000;15:147-159.